


# Facial Reconstruction

**Greg S. Morganroth, MD**

**Adjunct Clinical Professor of Otolaryngology/Head and Neck Surgery, Stanford University**

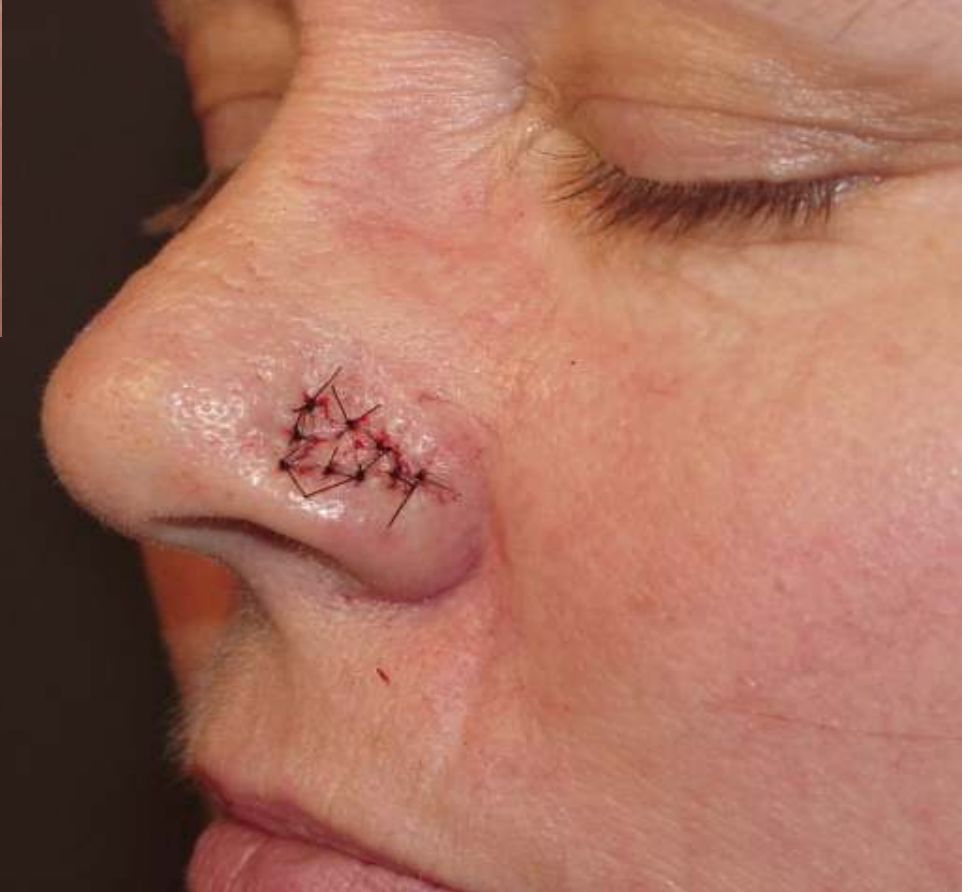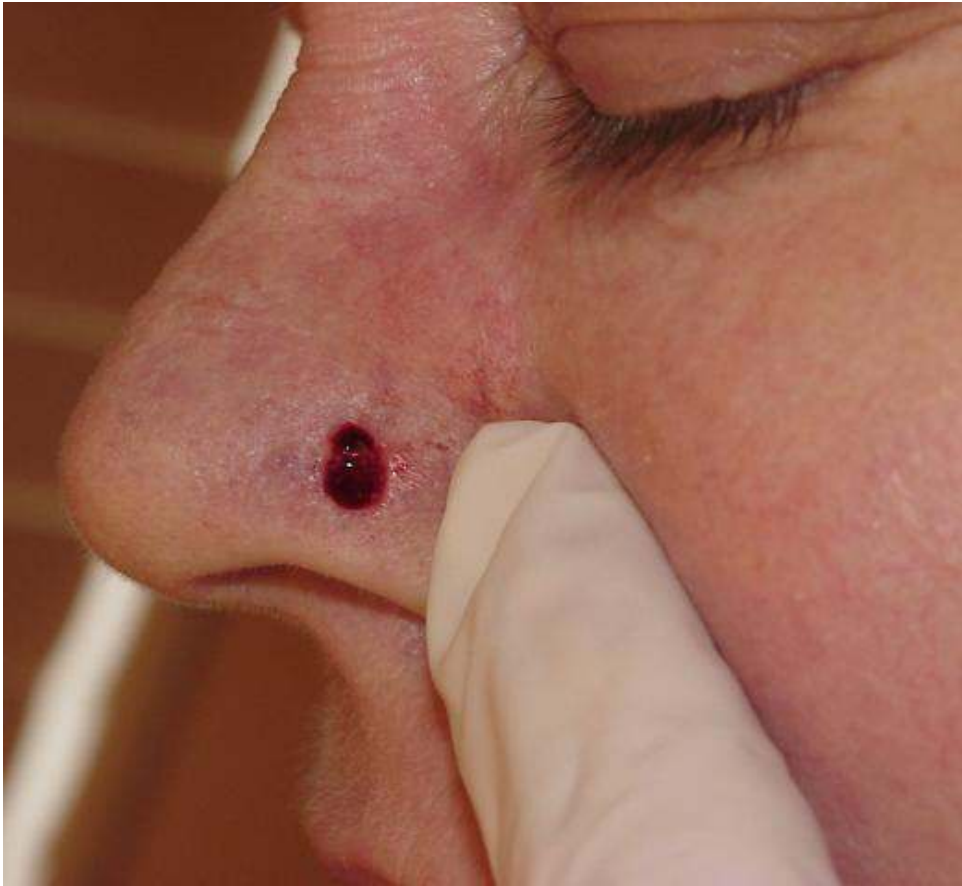**Assistant Clinical Professor of Dermatology, University of California, San Francisco**

**Fellowship Director, American College of Mohs Surgery**

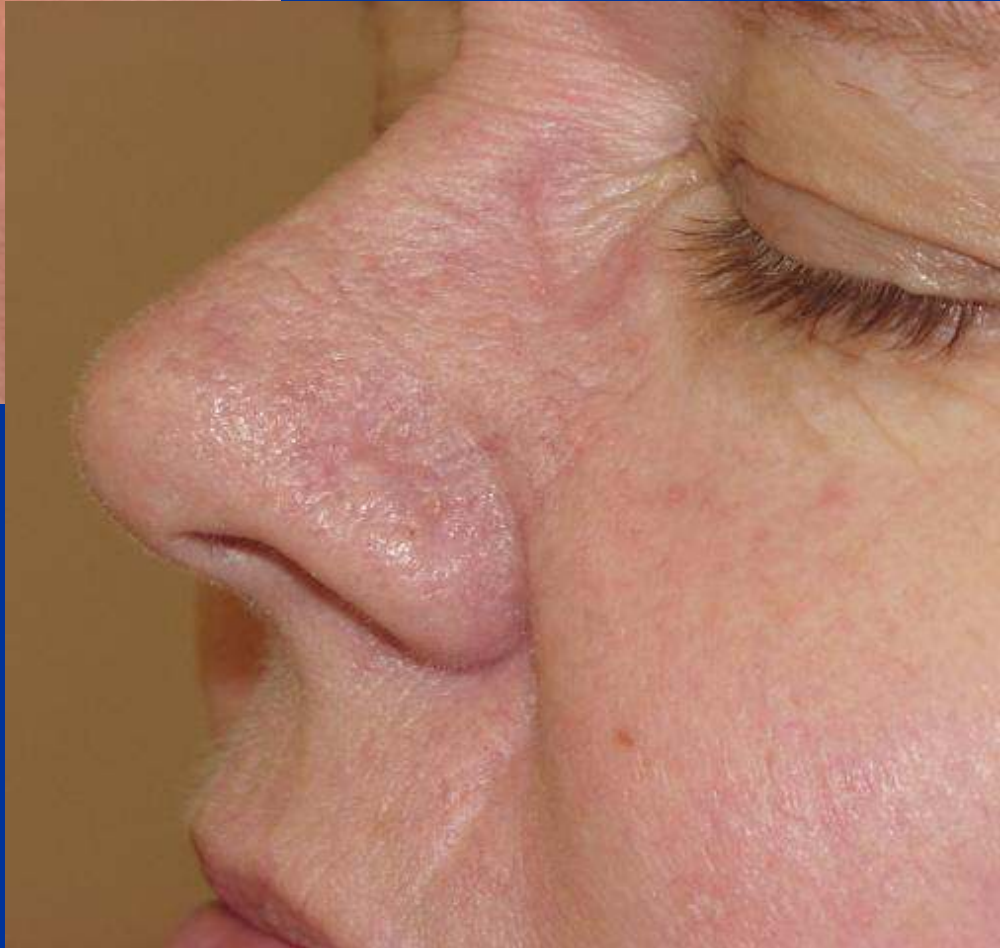
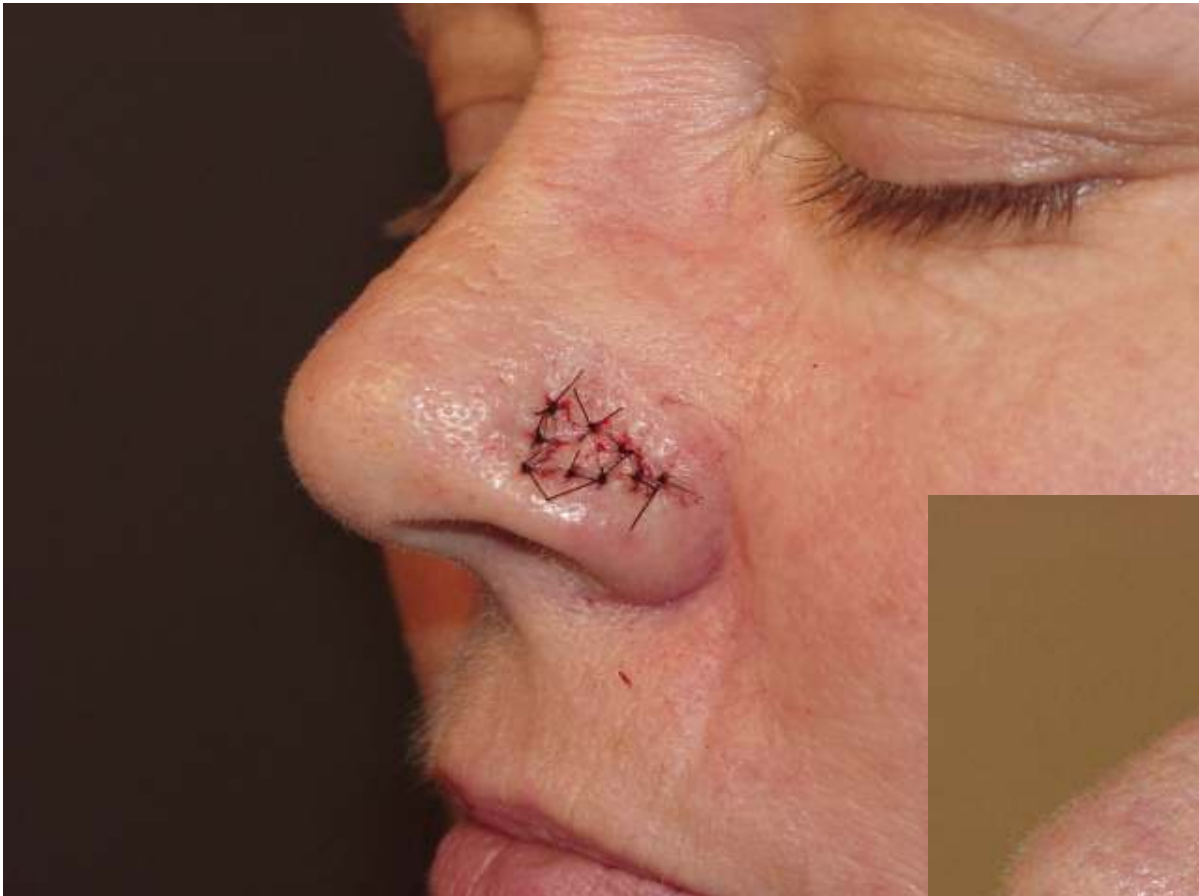
# The Nasal Ala

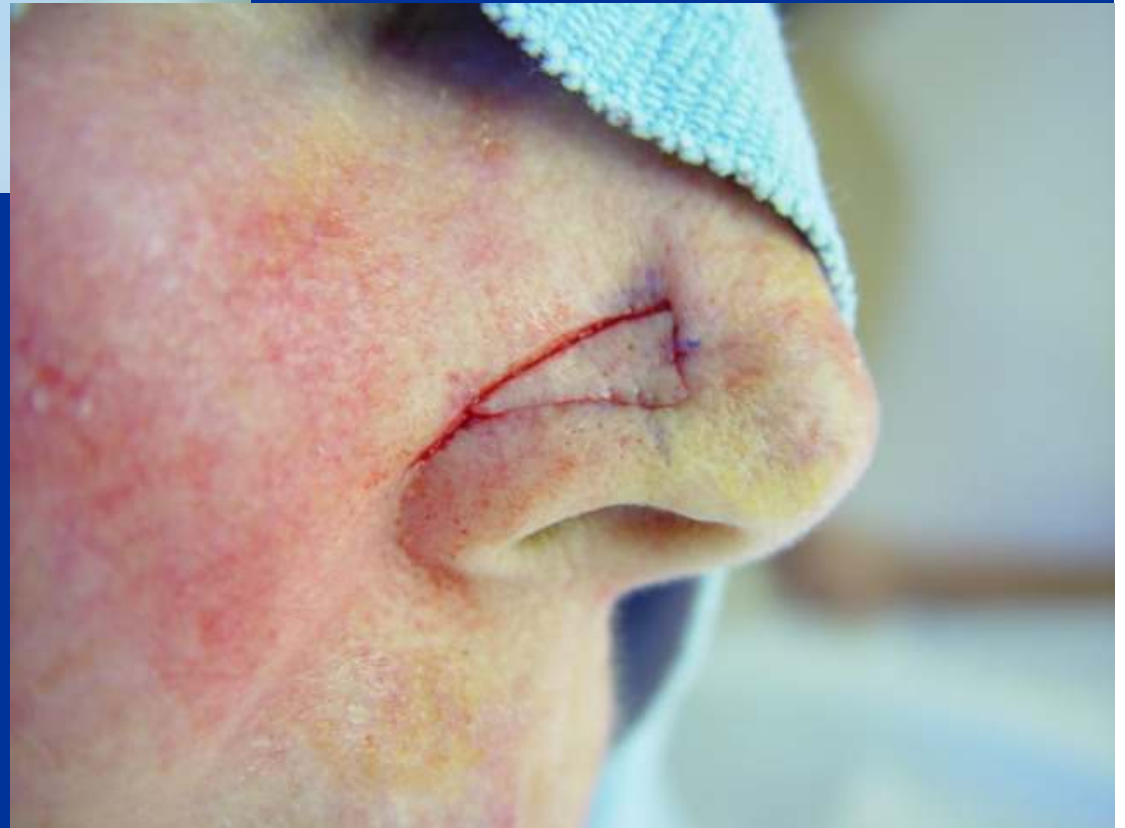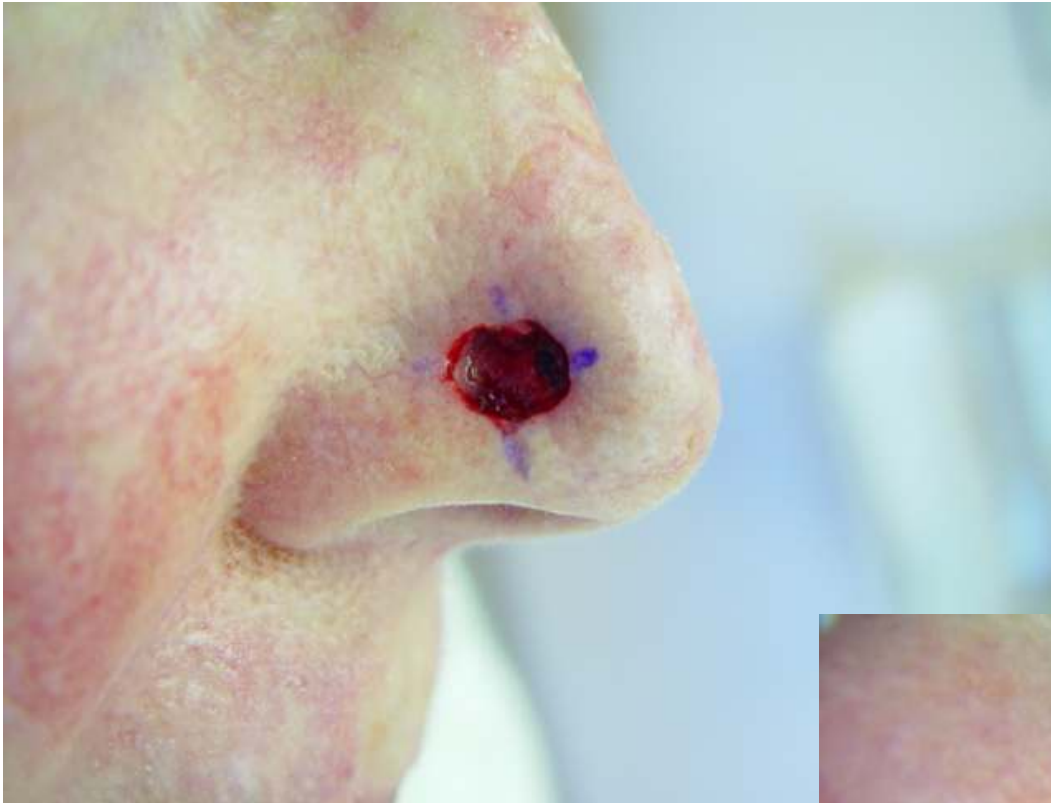Greg S. Morganroth, MD



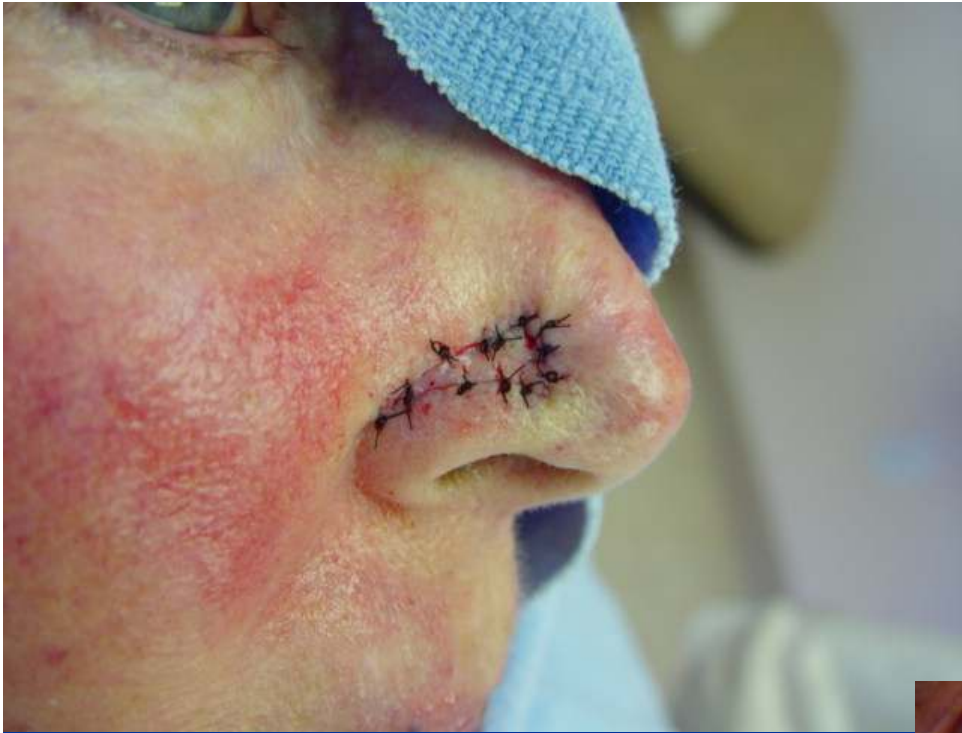Island Pedicle Flap



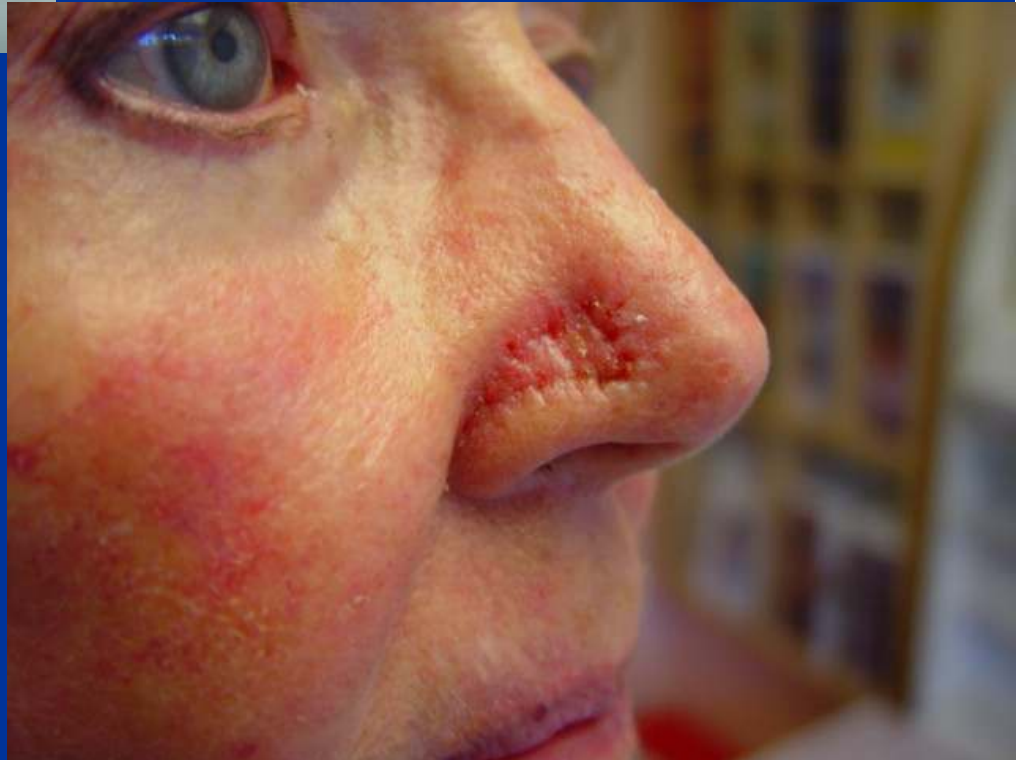Six weeks later

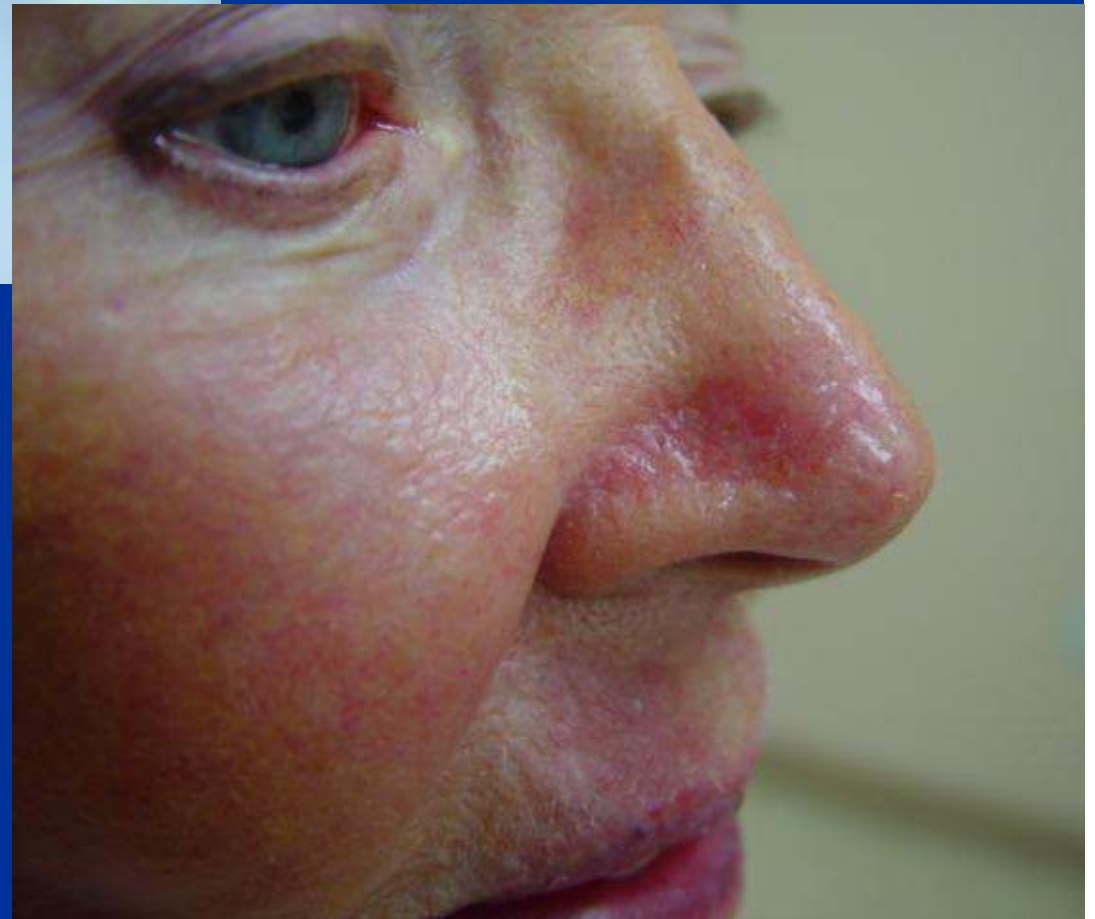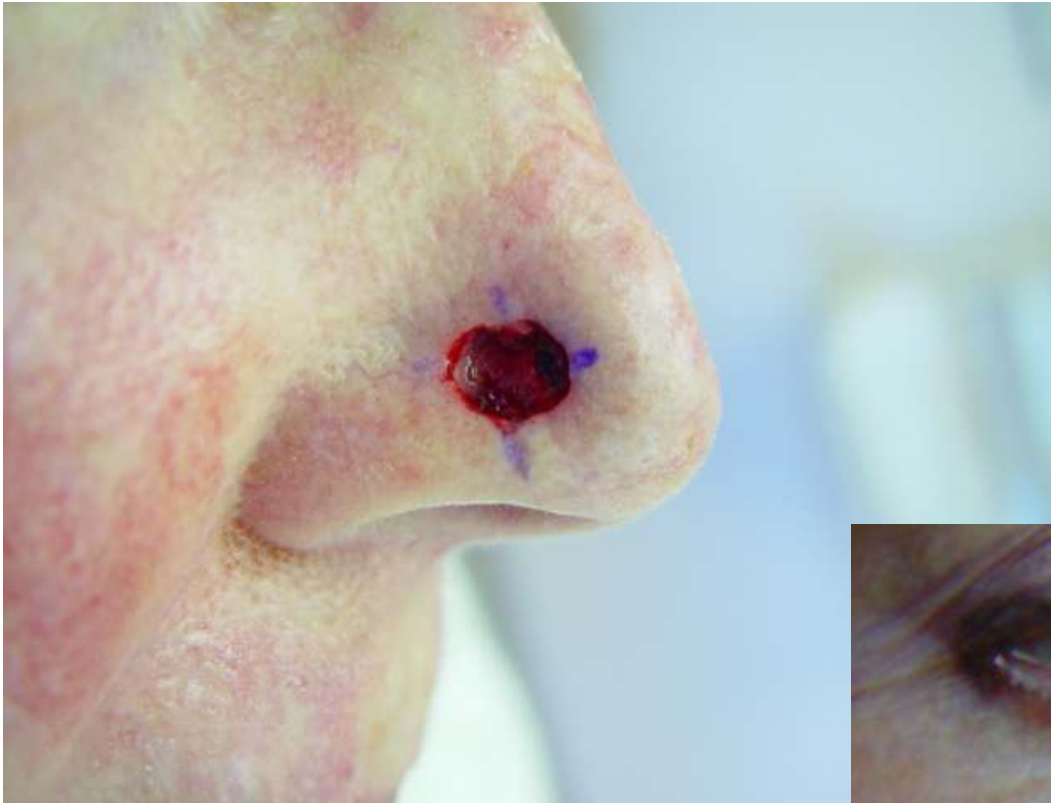


Island Pedicle Flap

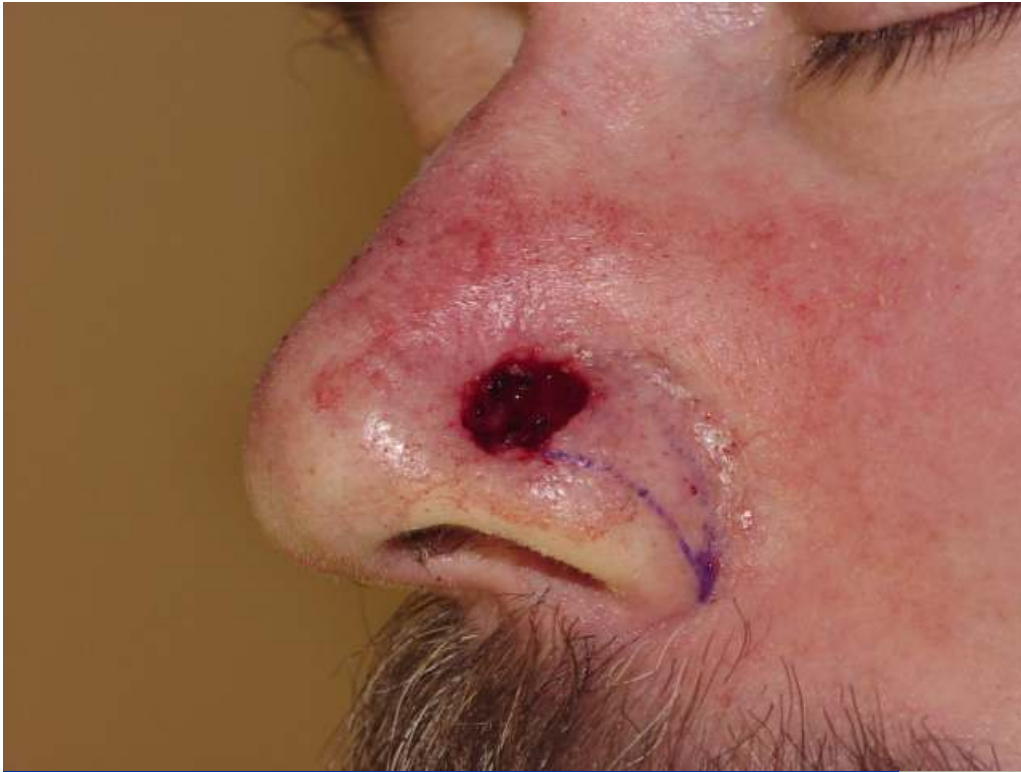

One week later

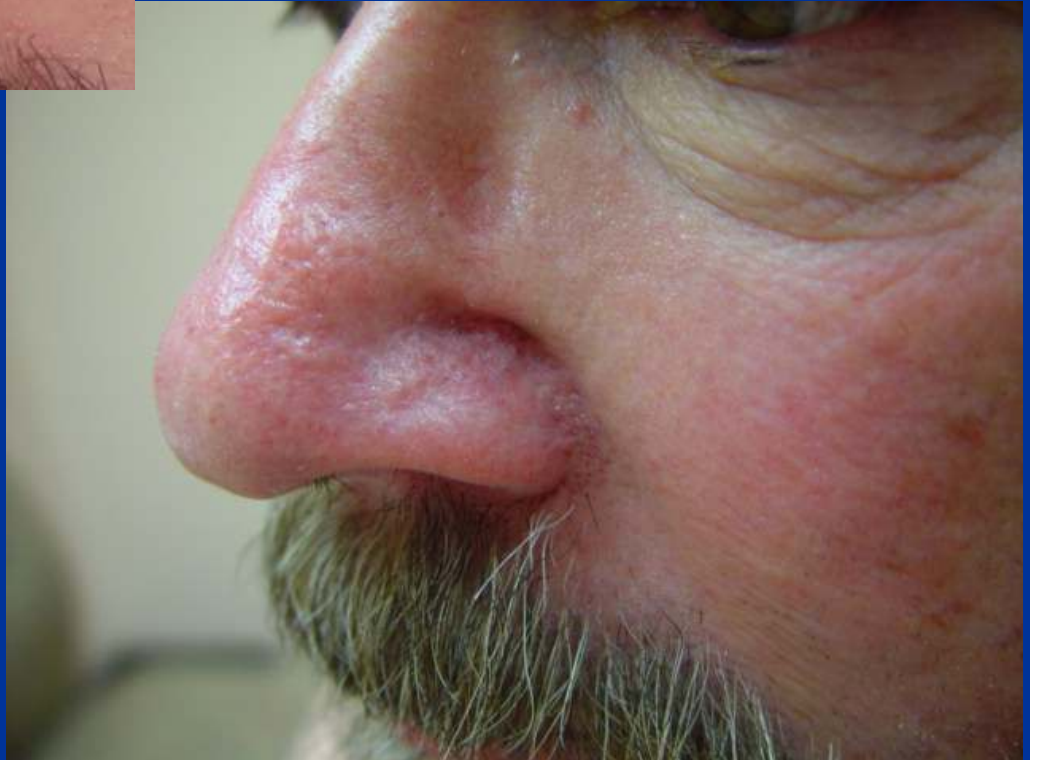


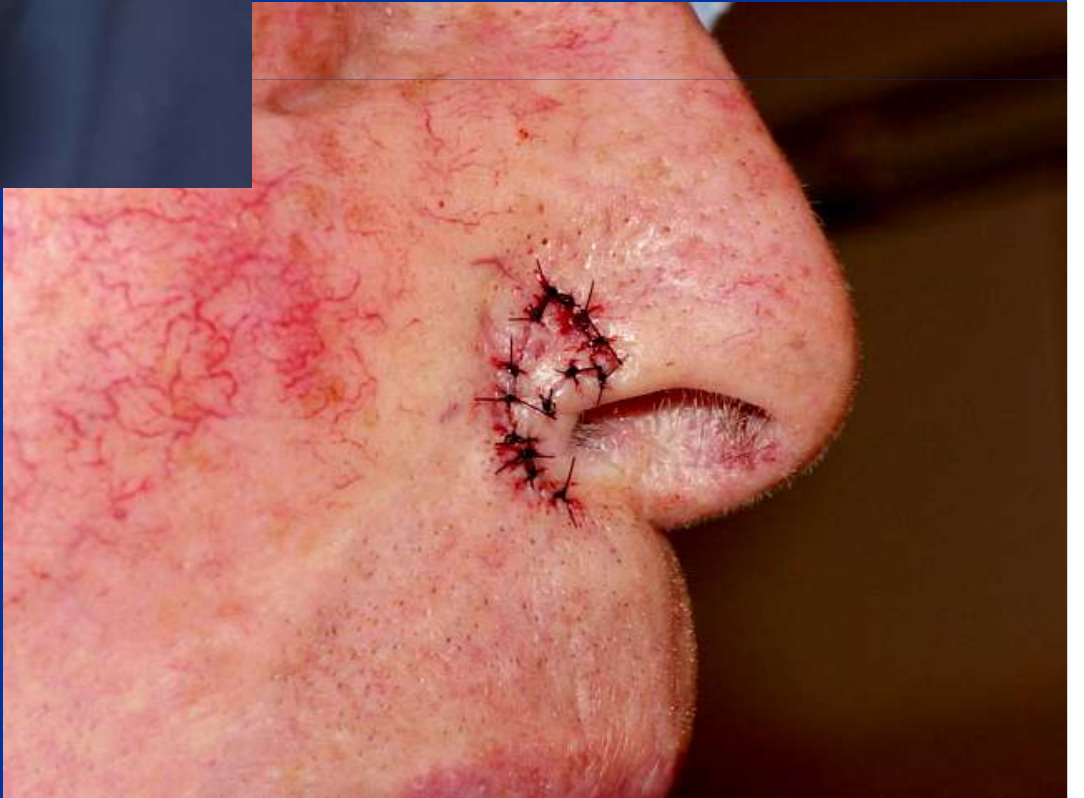
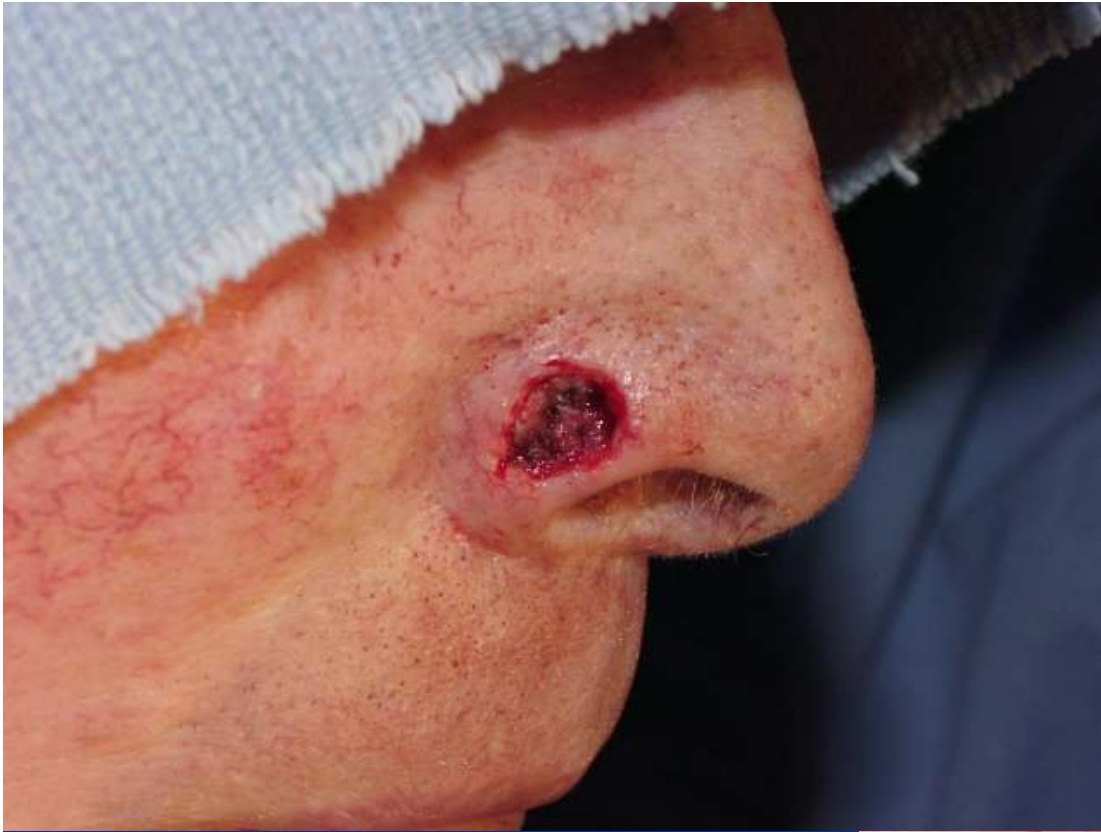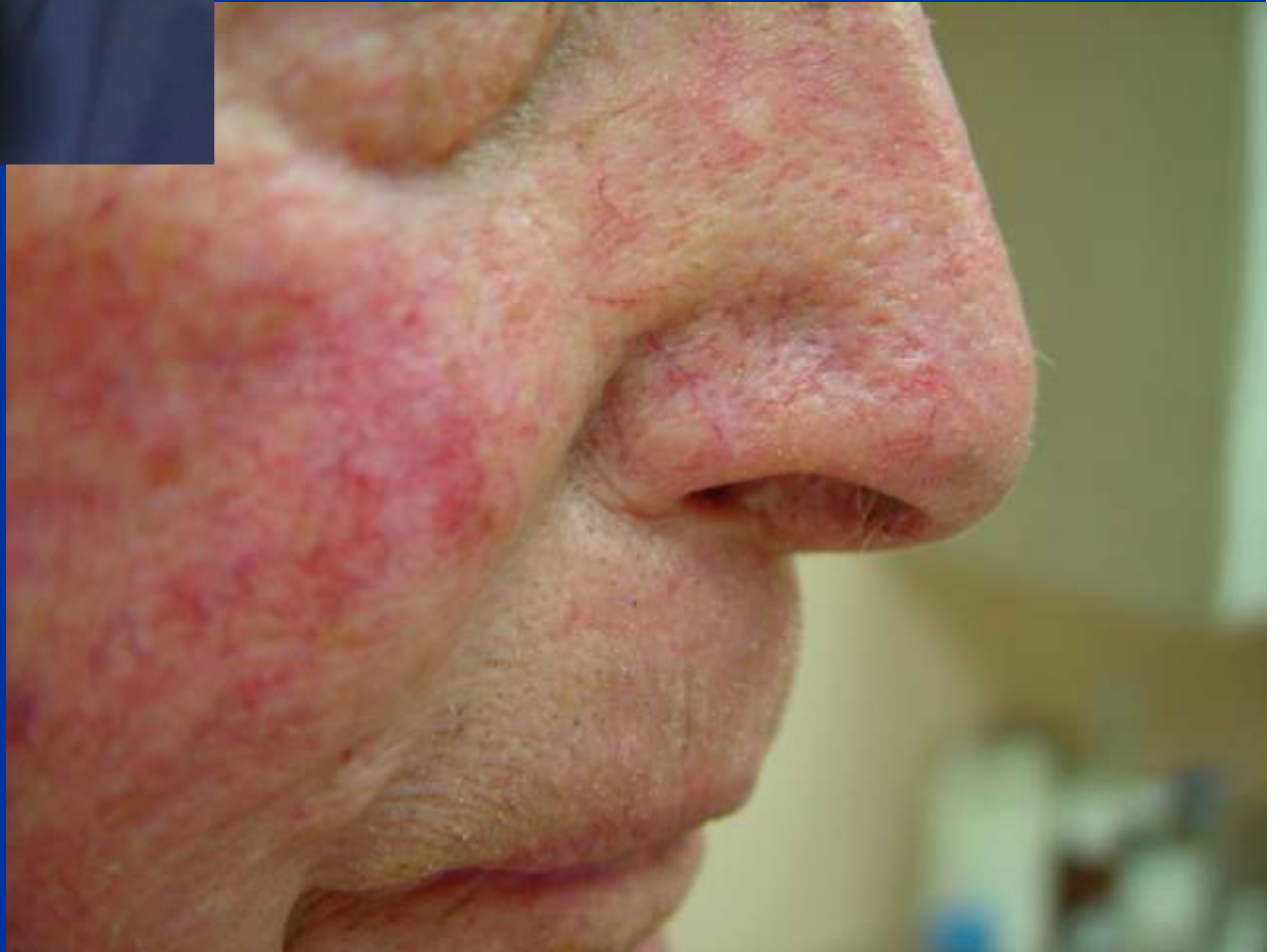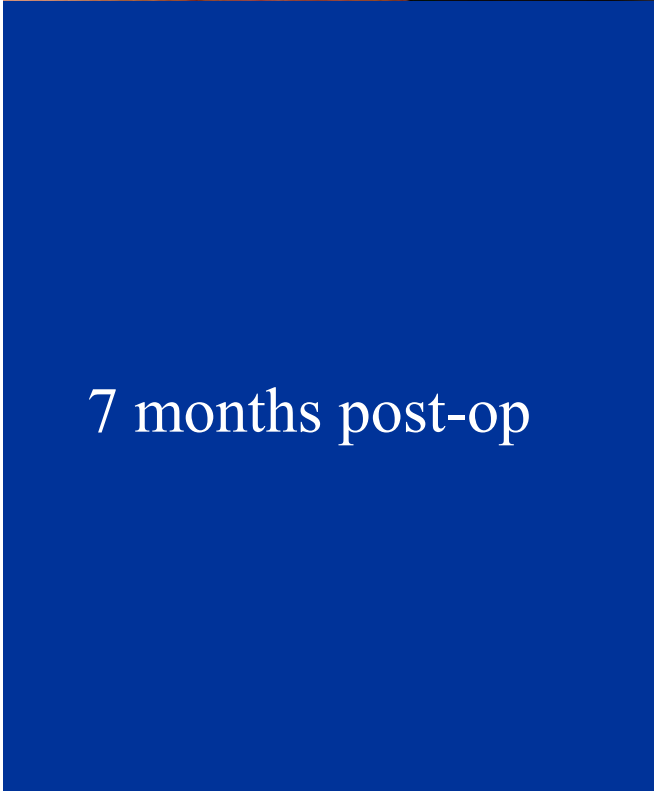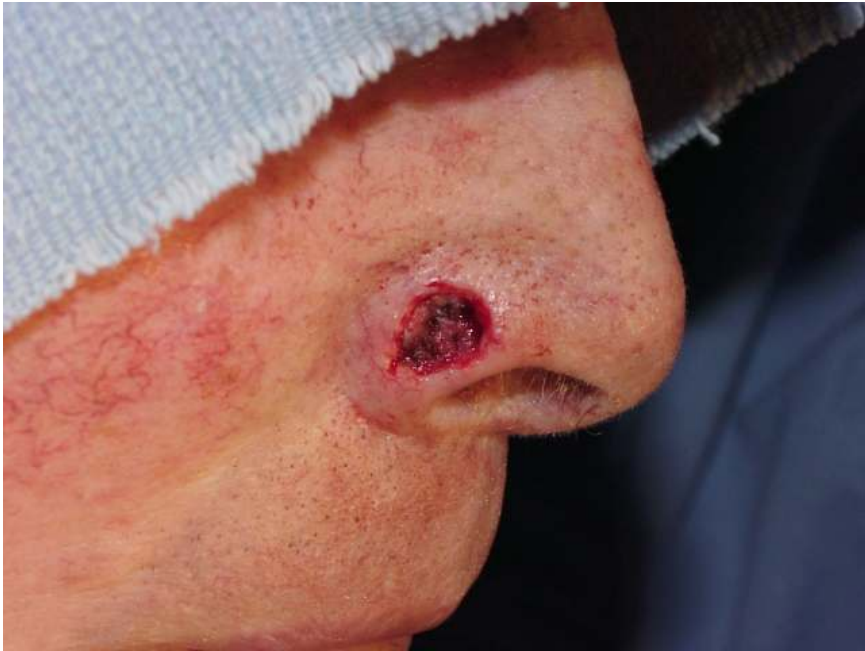One month later

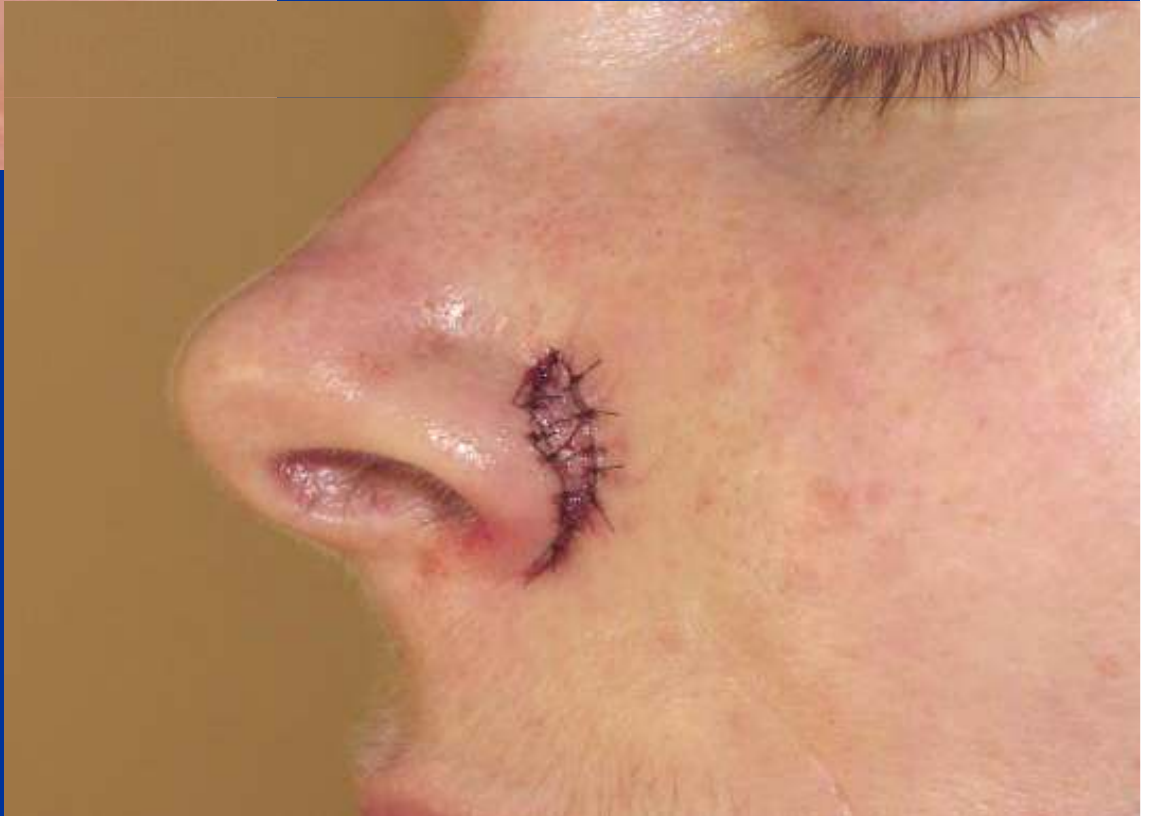
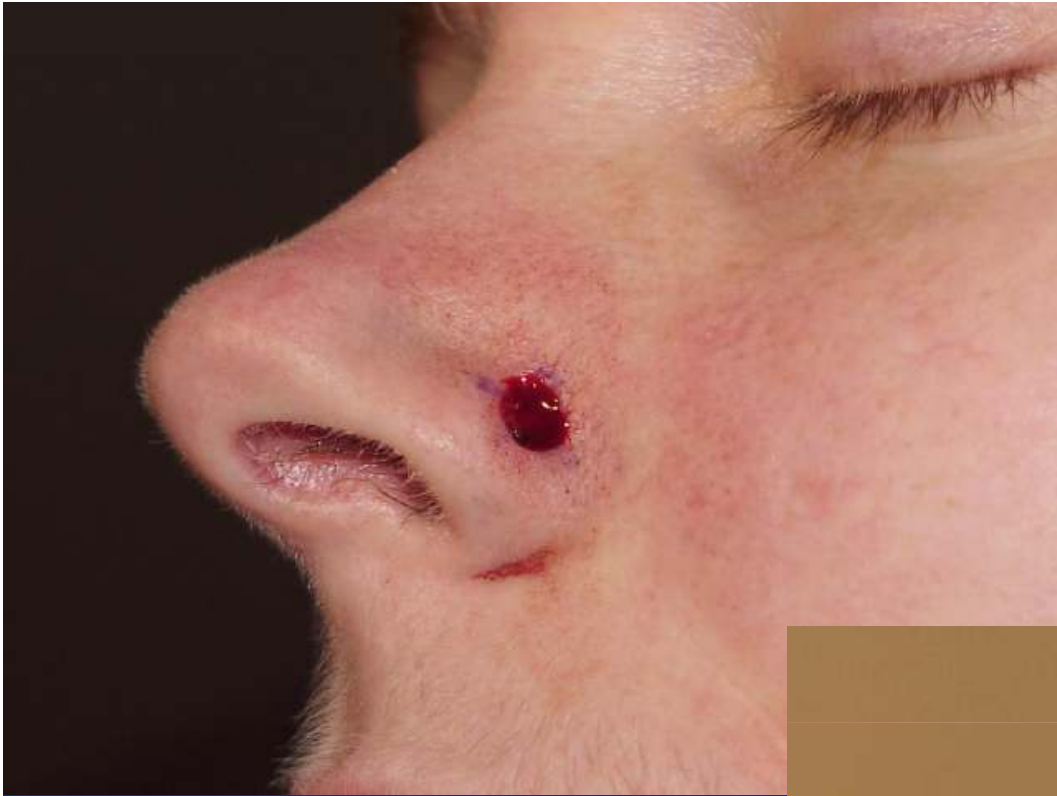
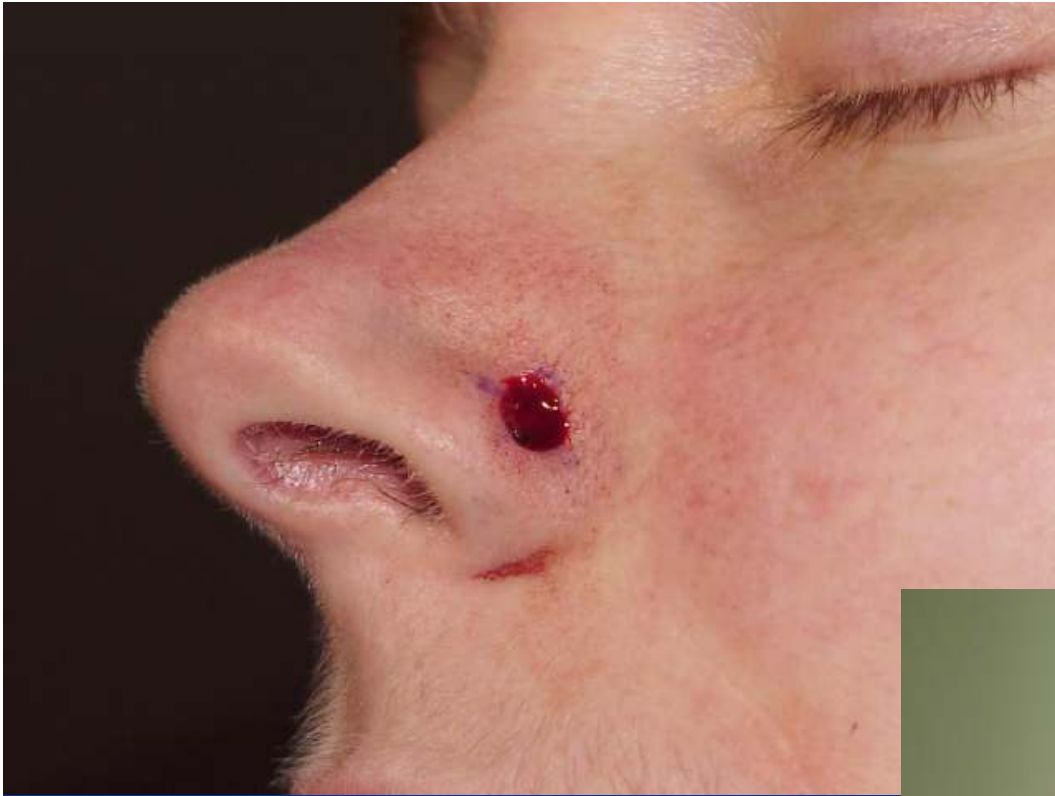**3 months later**



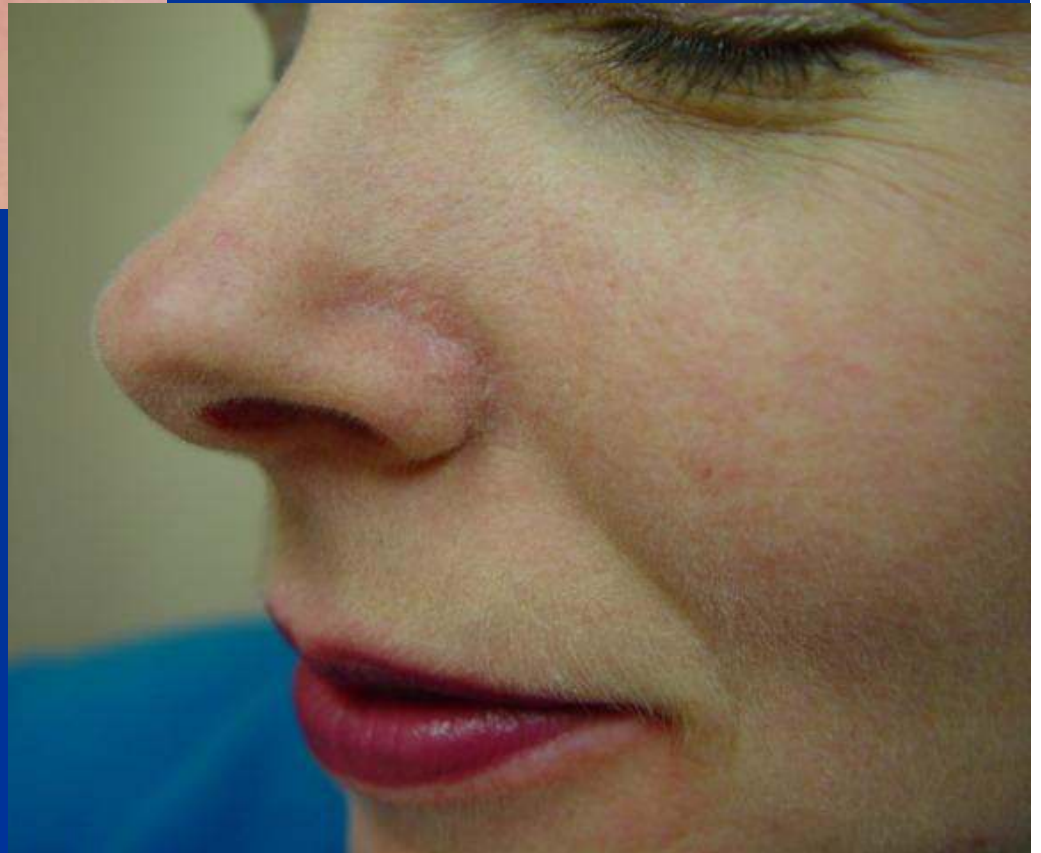






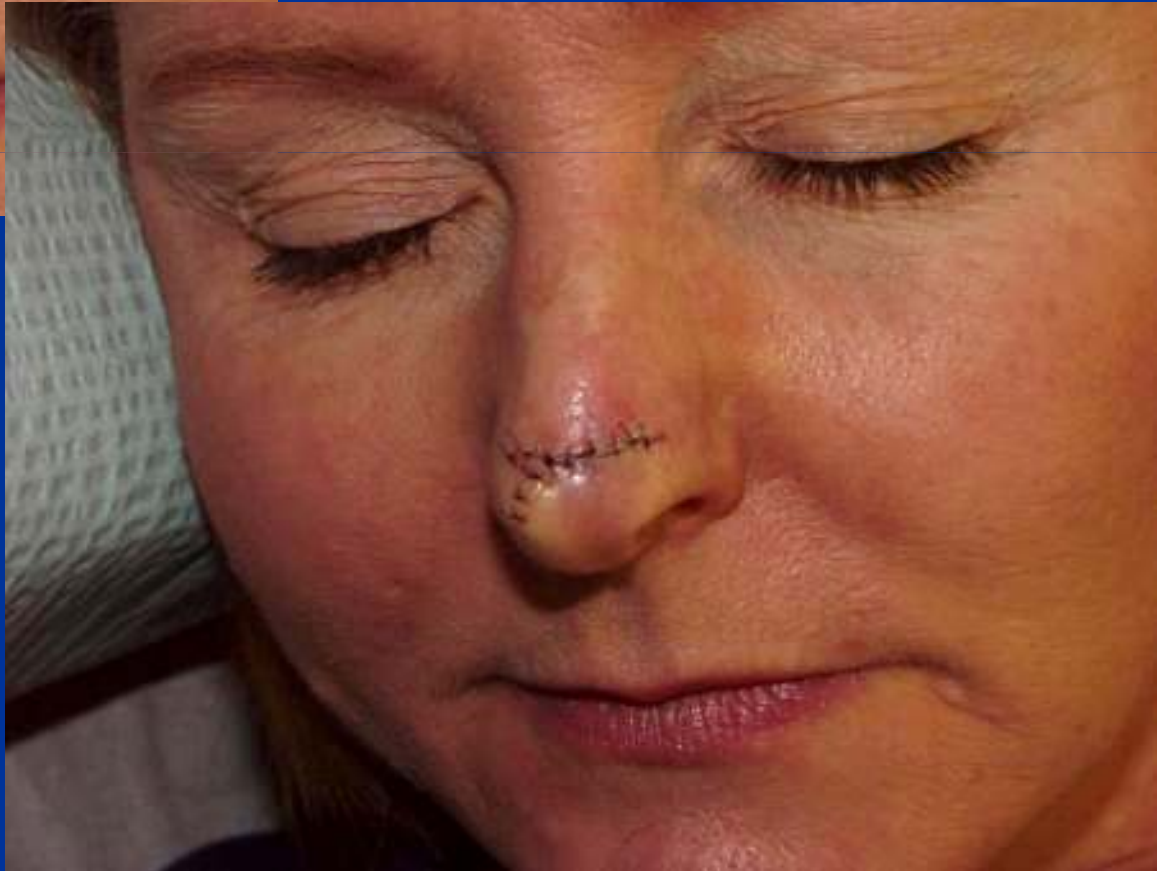
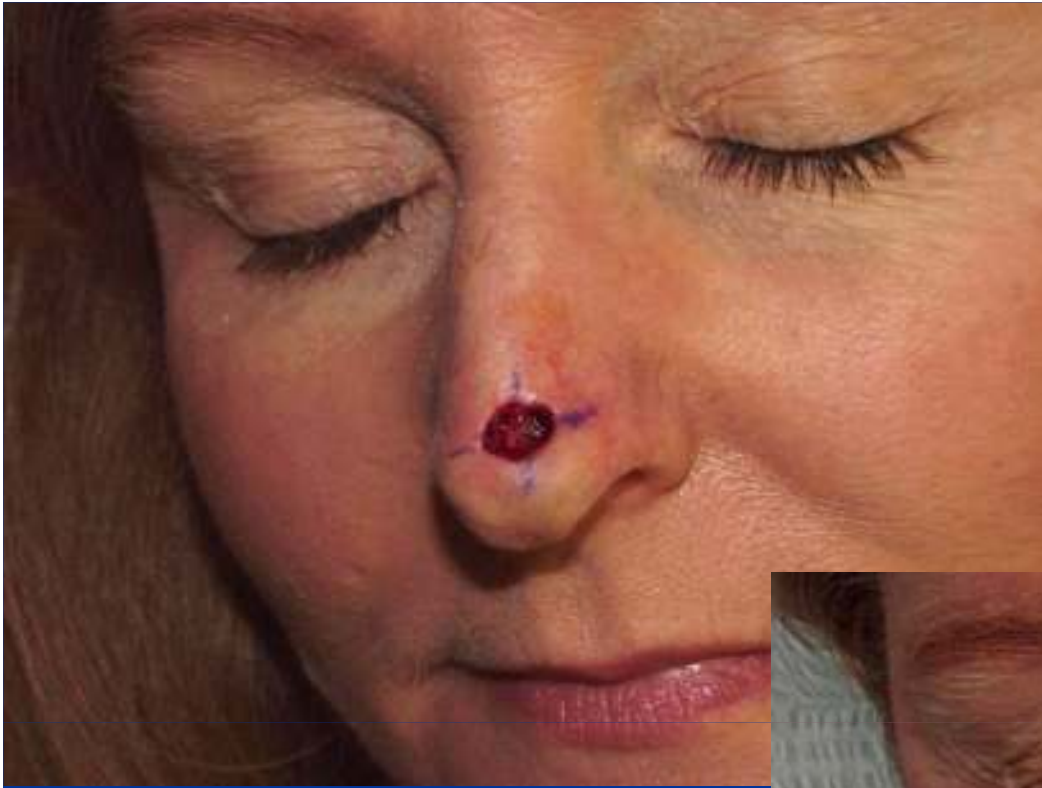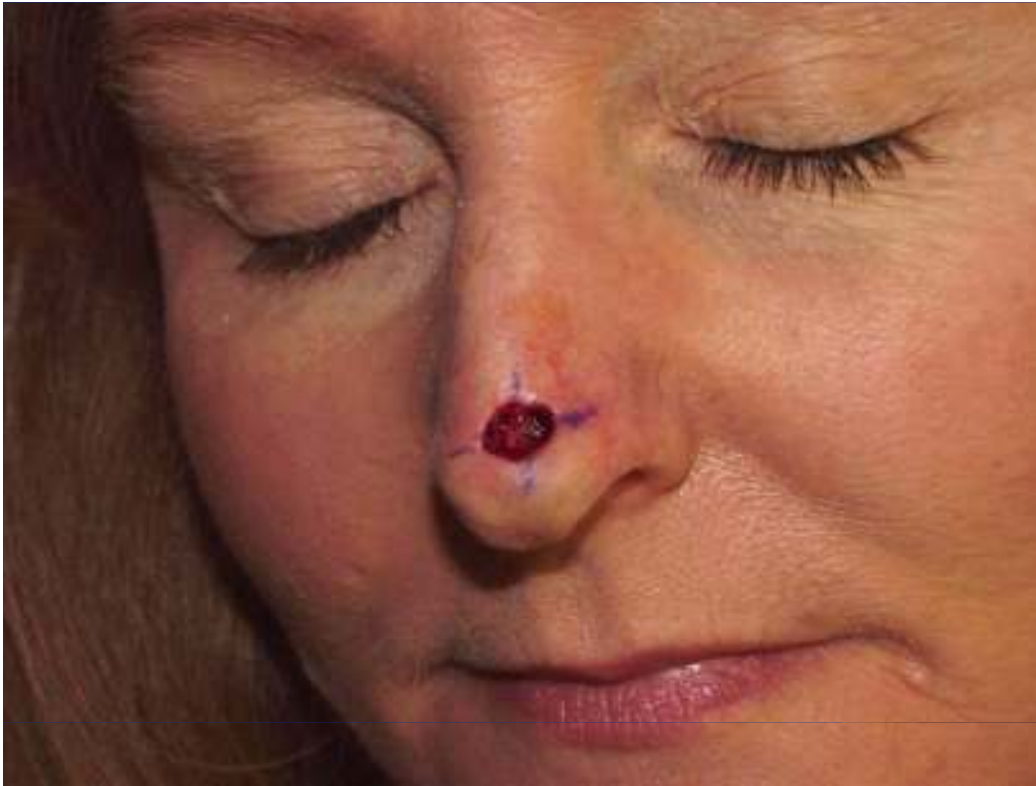**3 months later**



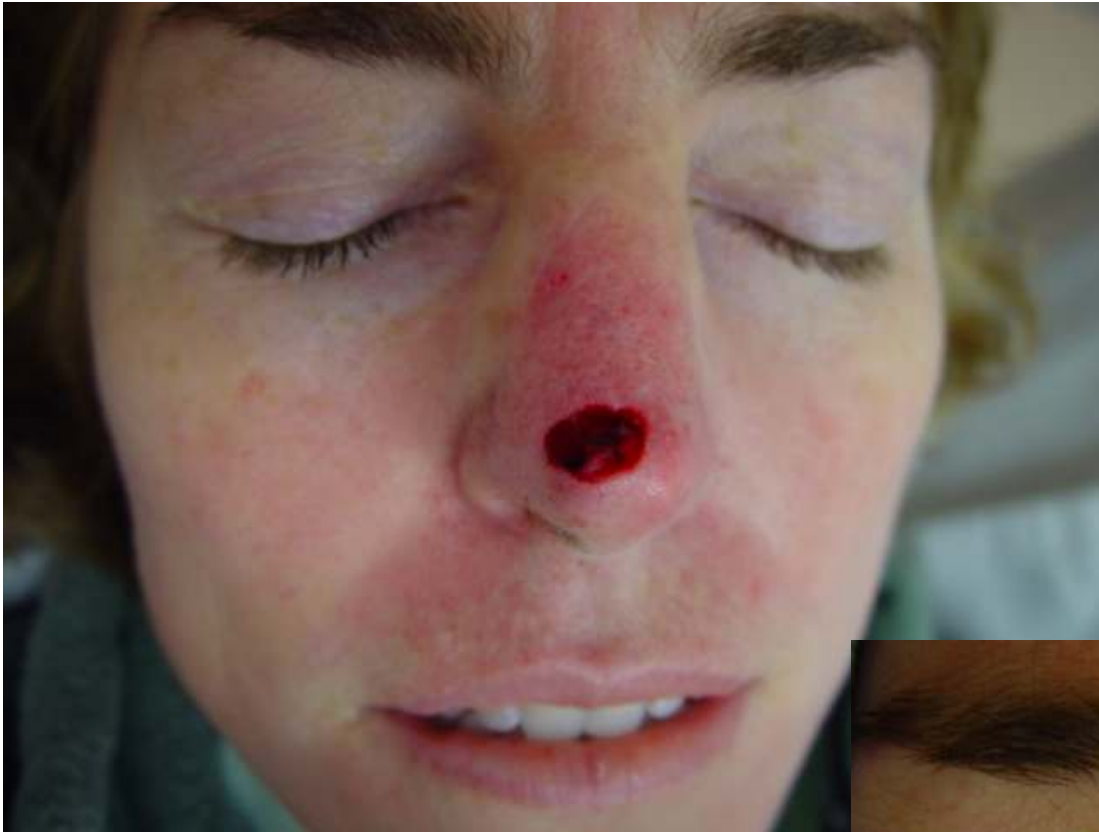# The Nasal Tip Region

Greg S. Morganroth, MD



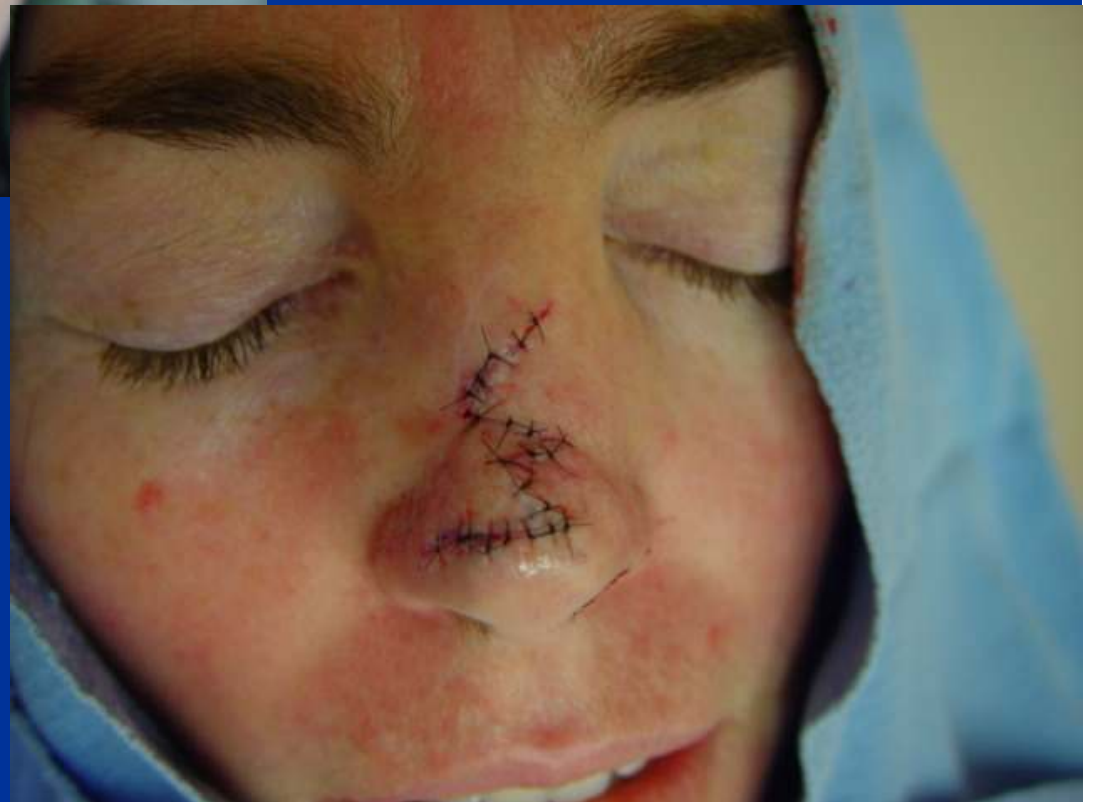

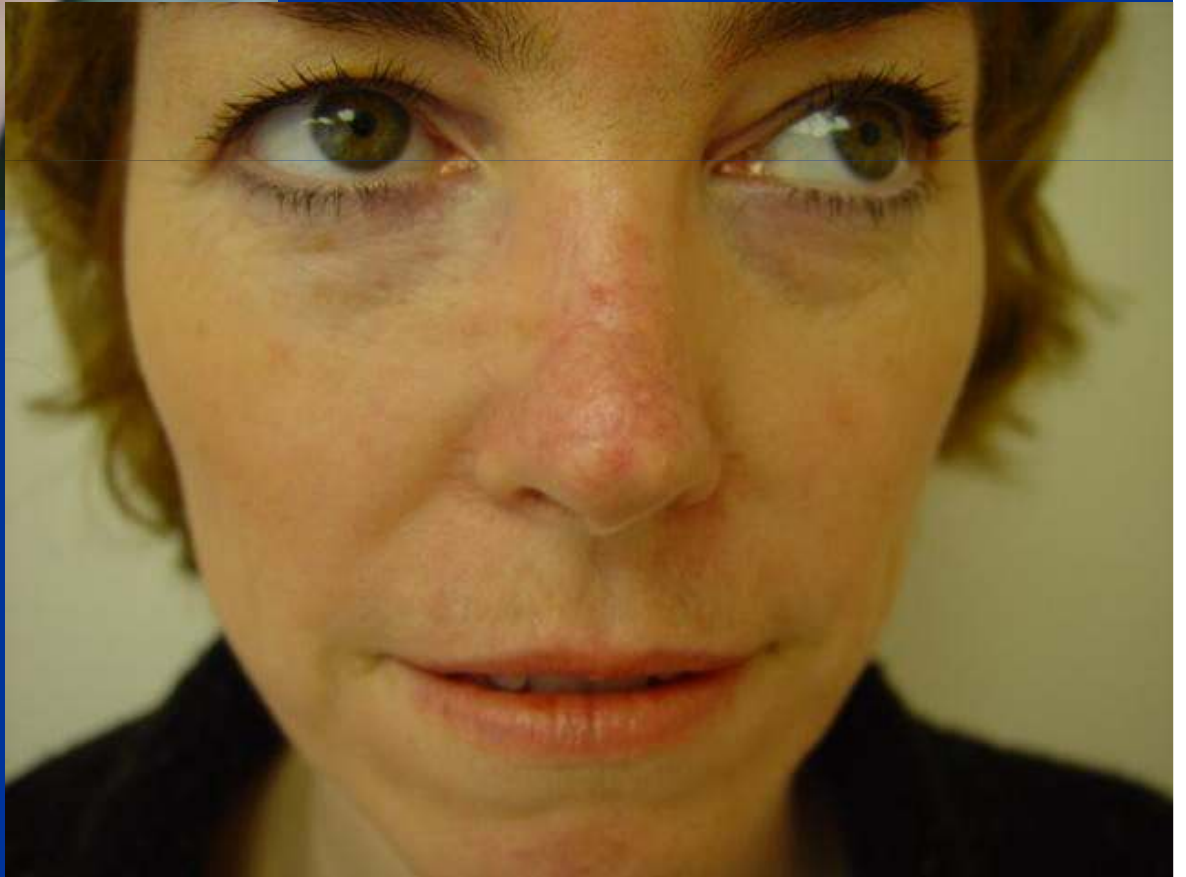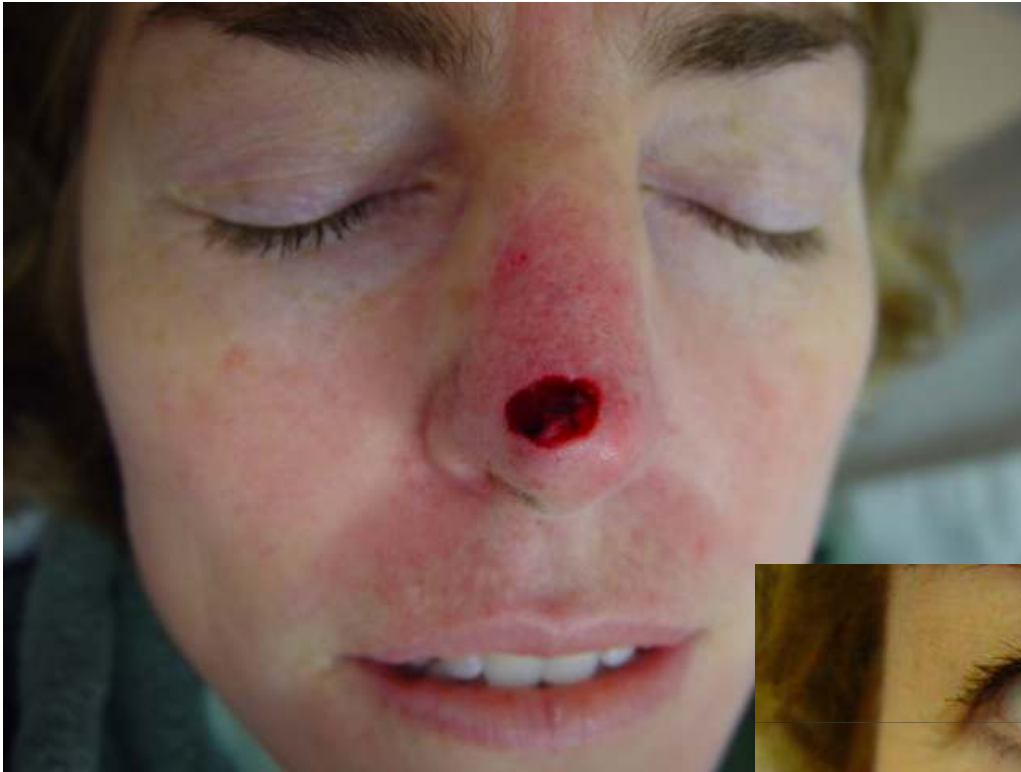6 months later



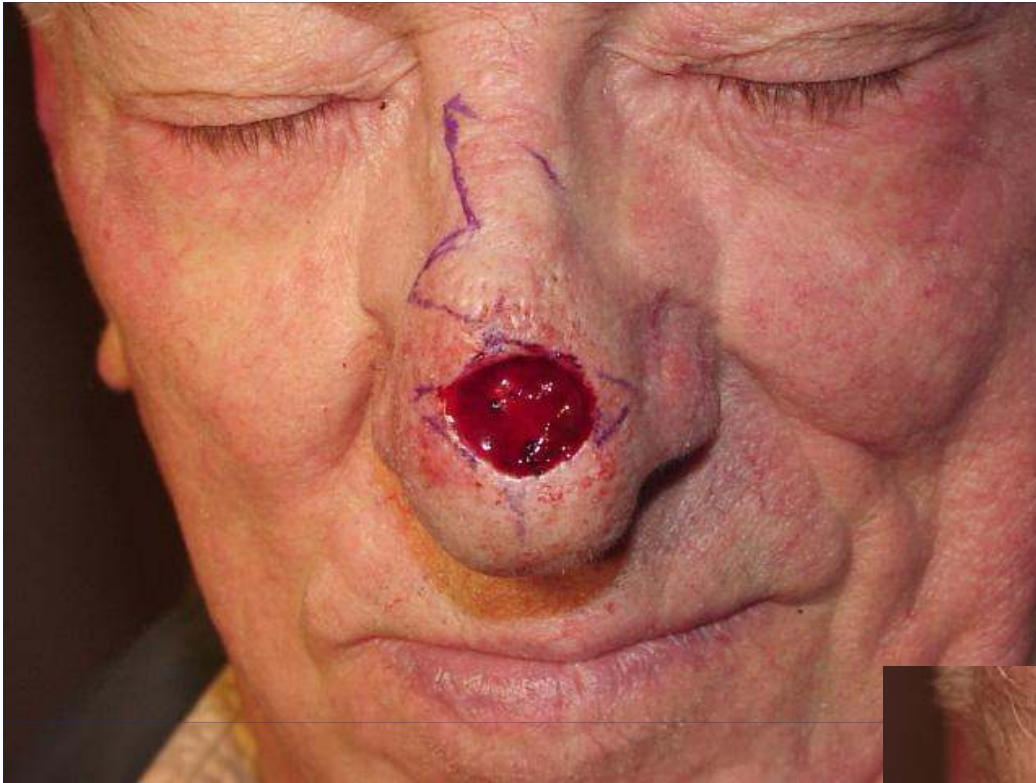Angled Bilobe  
Transposition Flap

Angles heal better  
than rounded edges

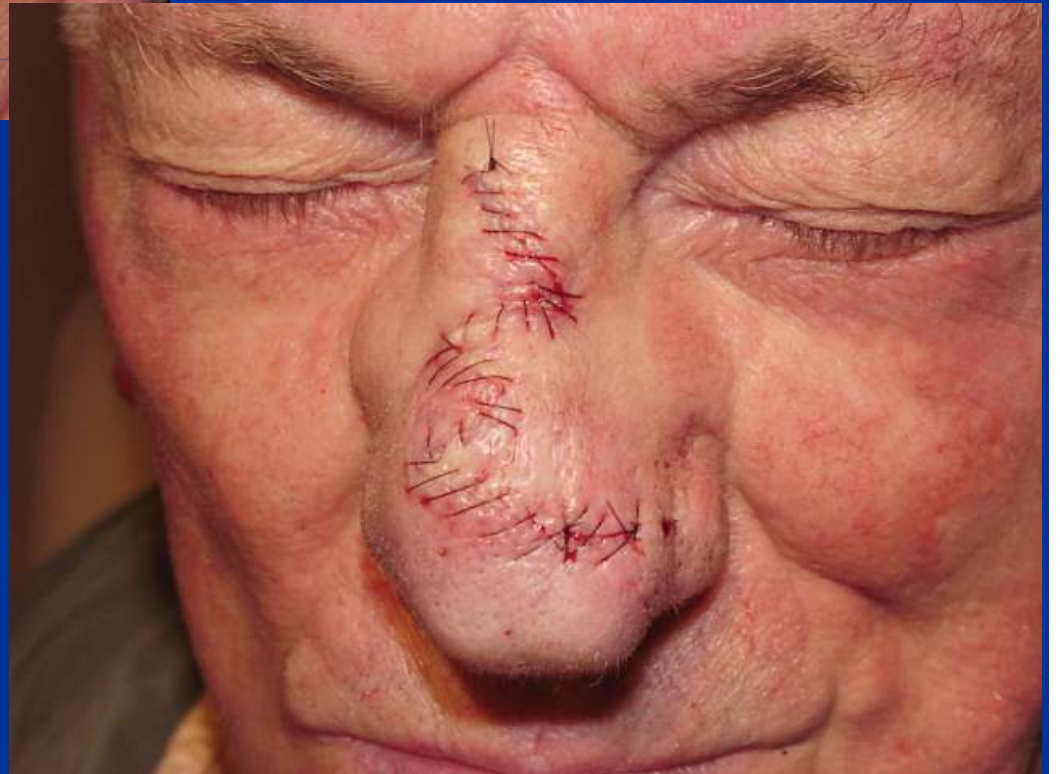


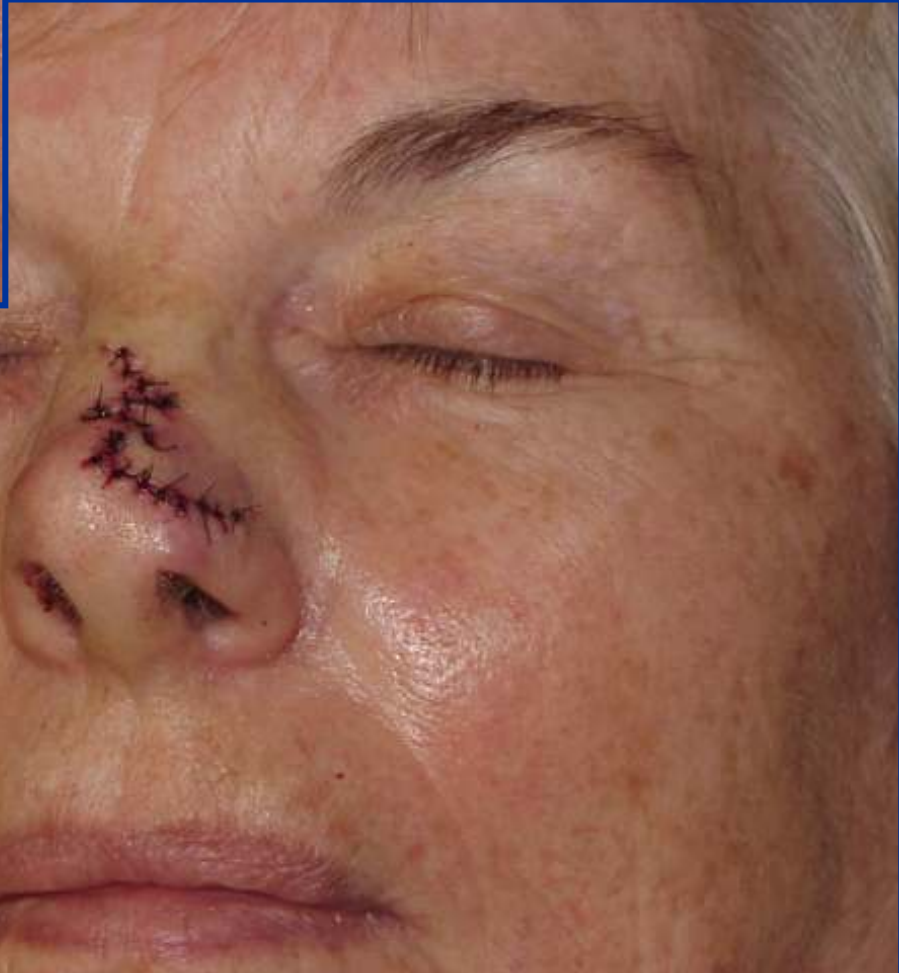
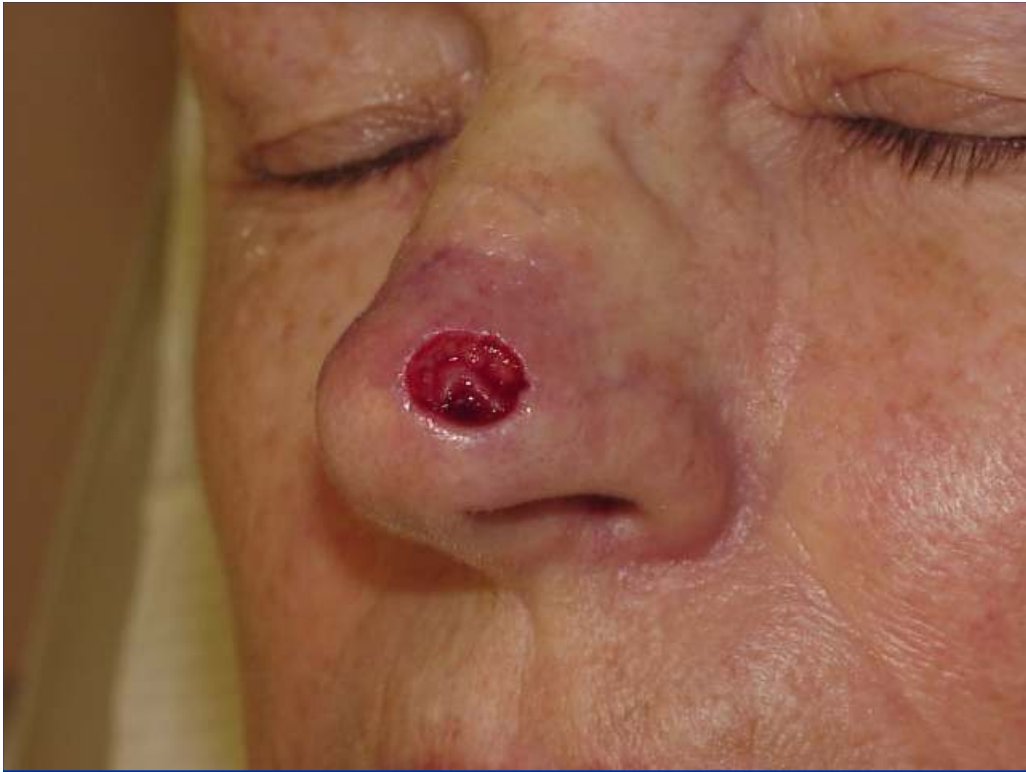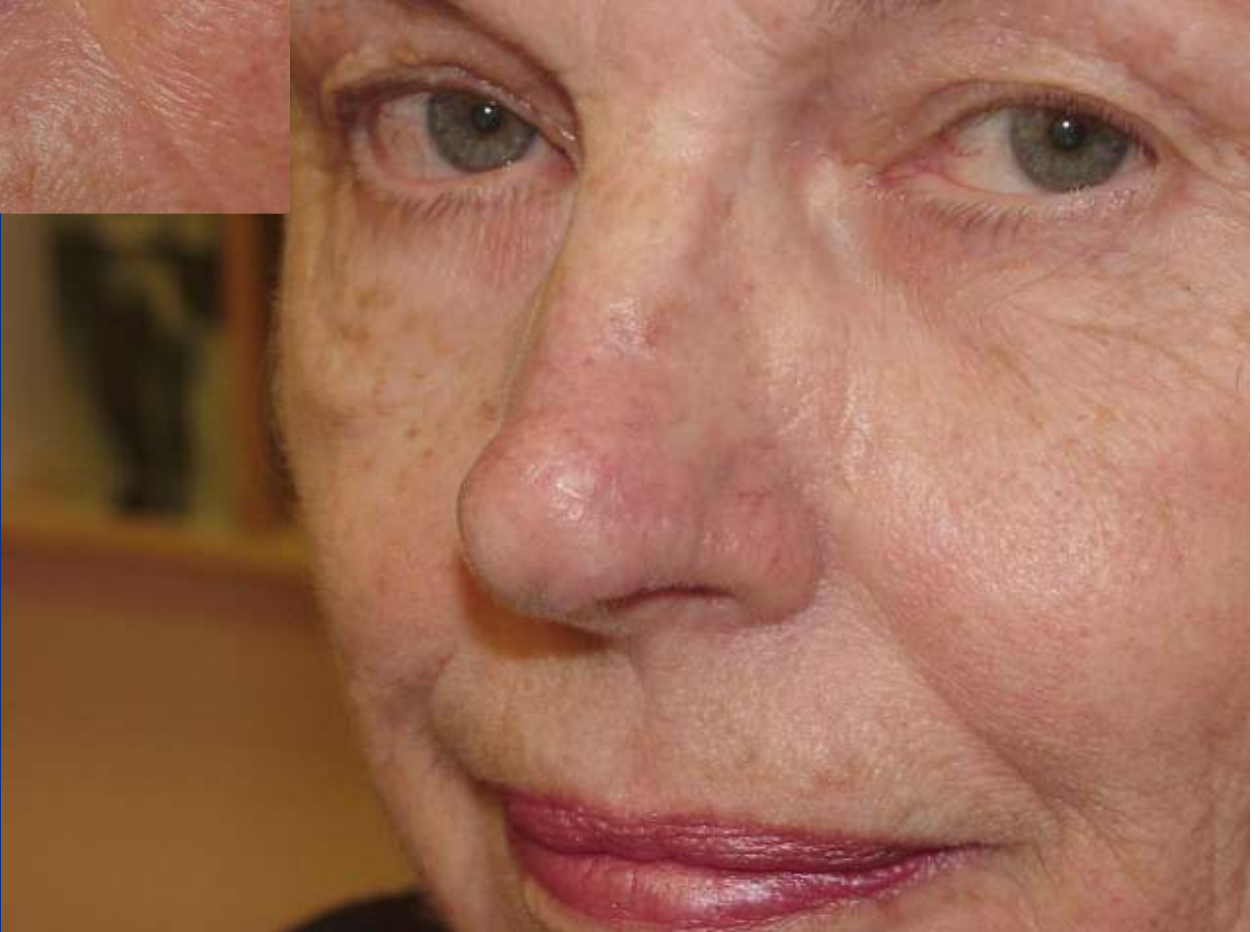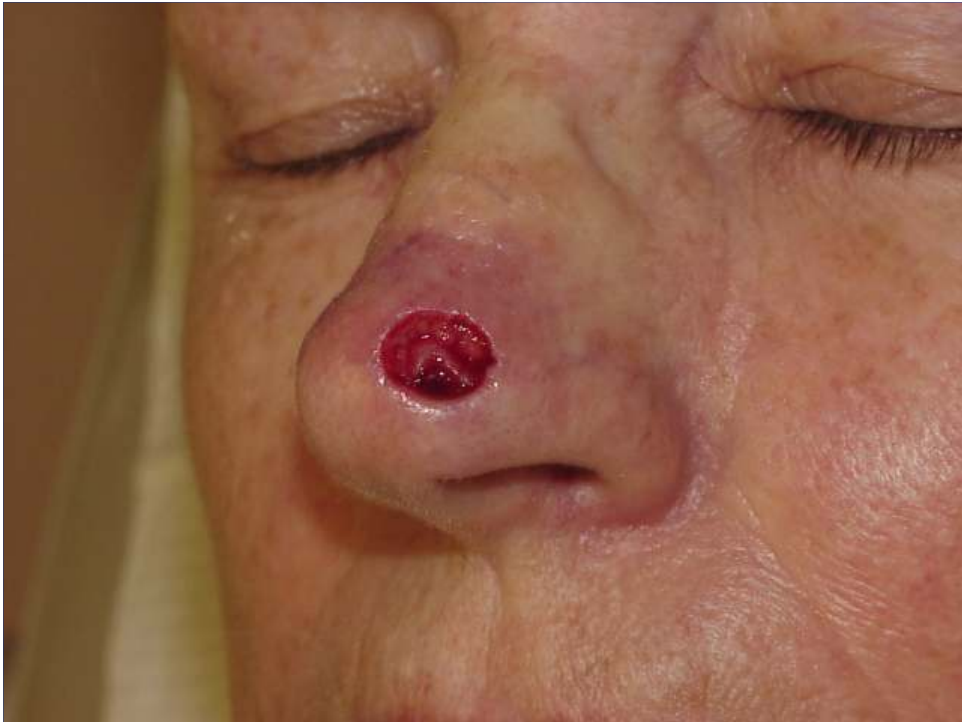6 weeks later

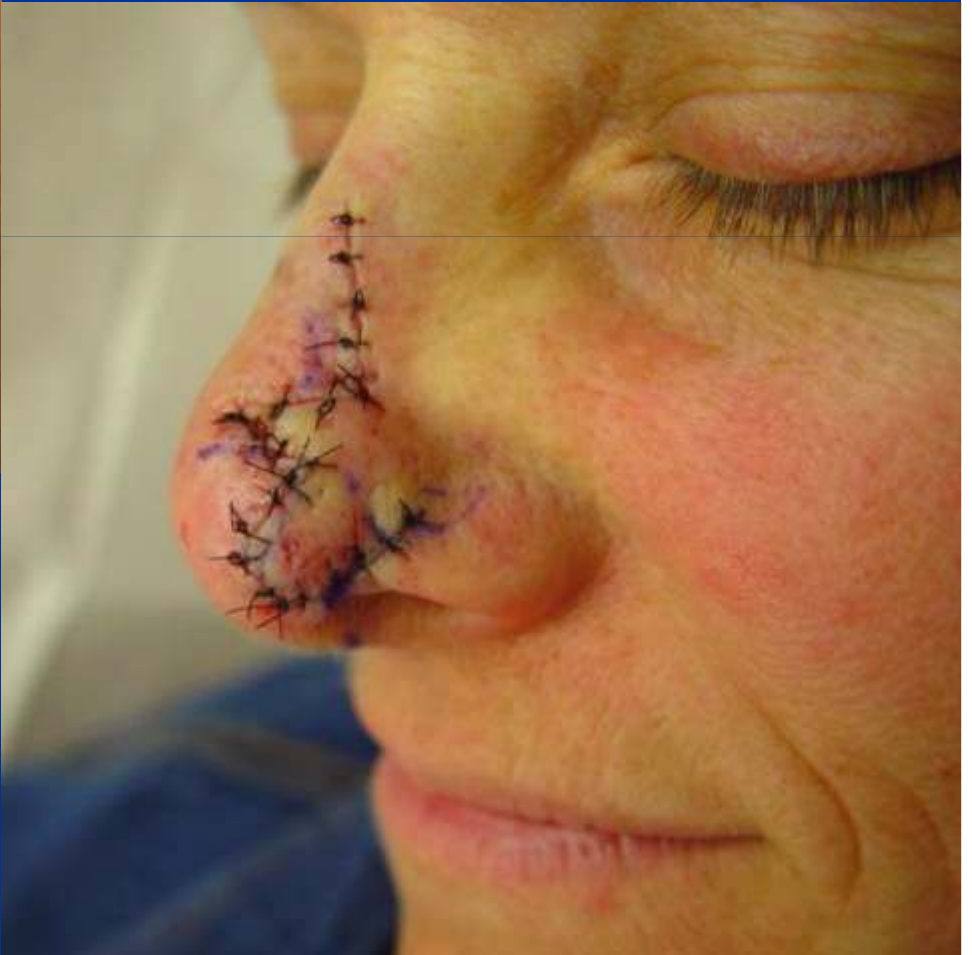
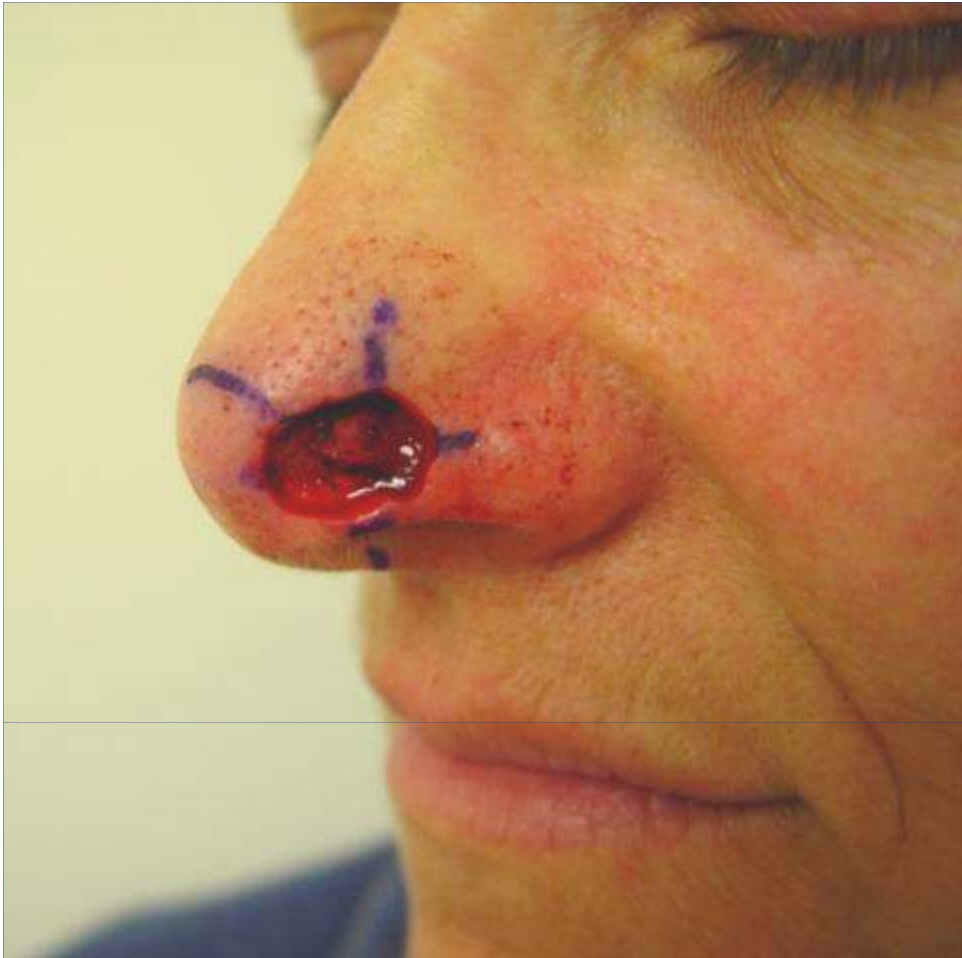

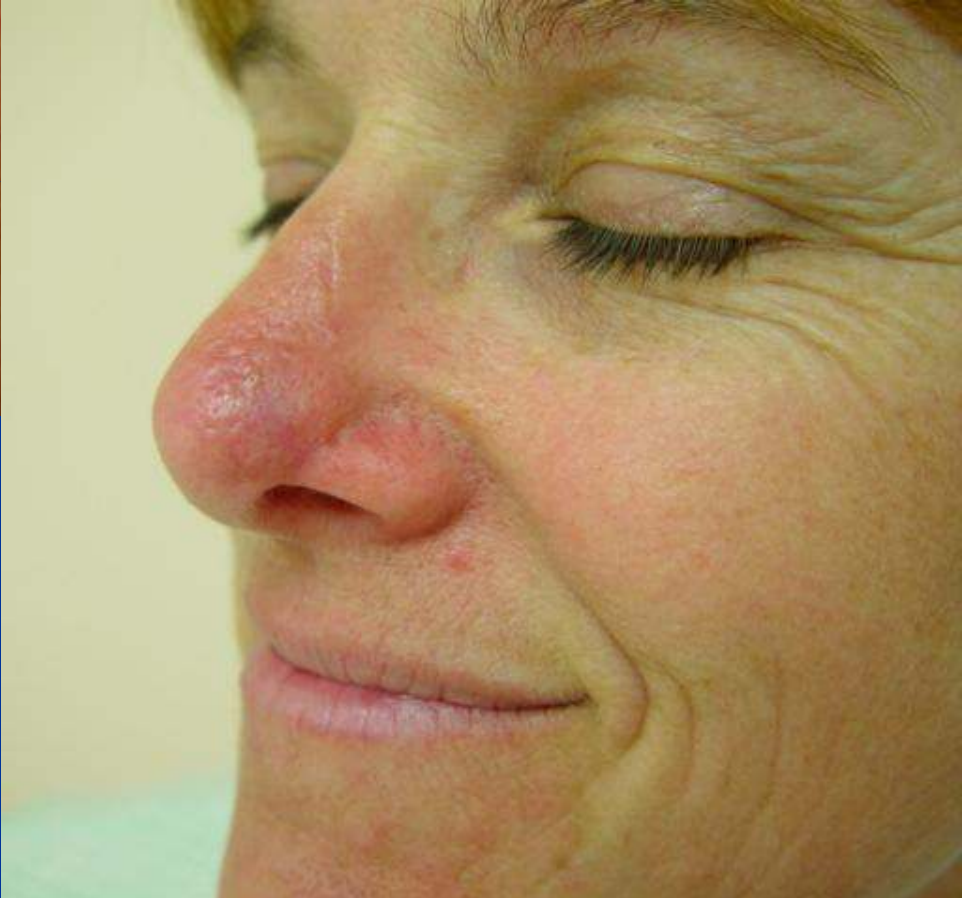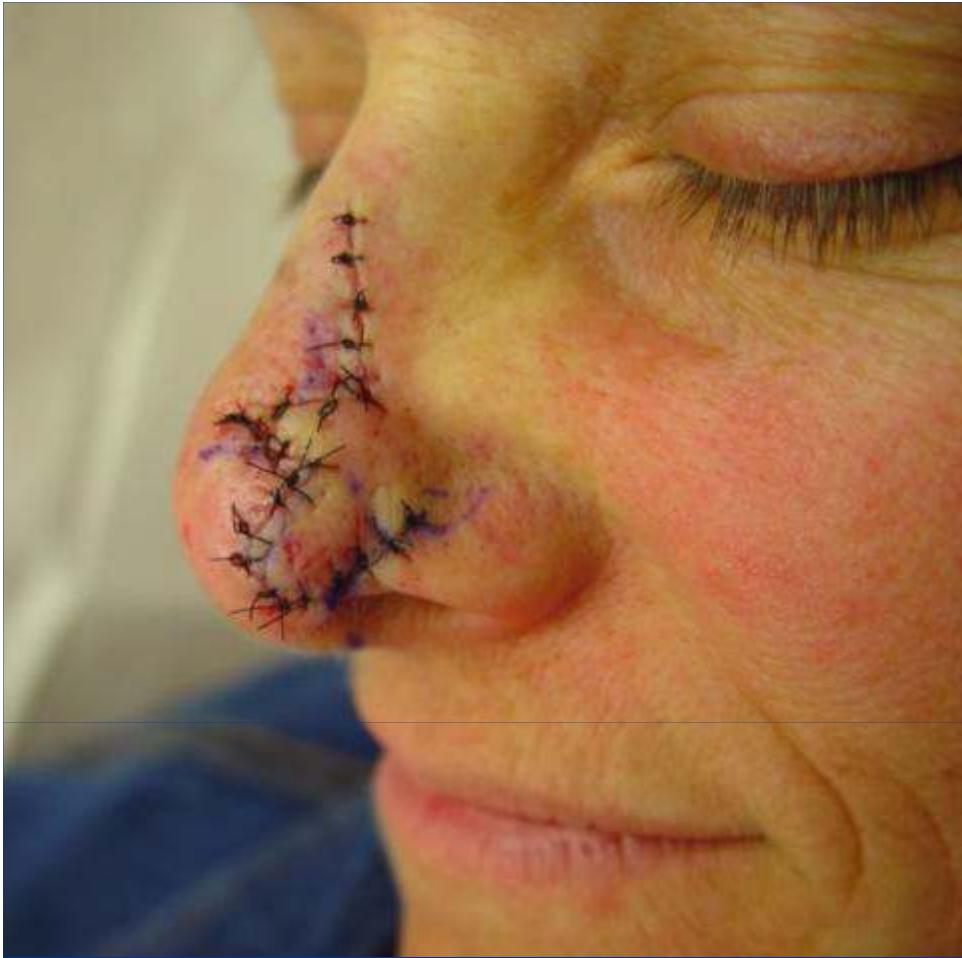**My pre-incisional drawing  
with gentian violet**



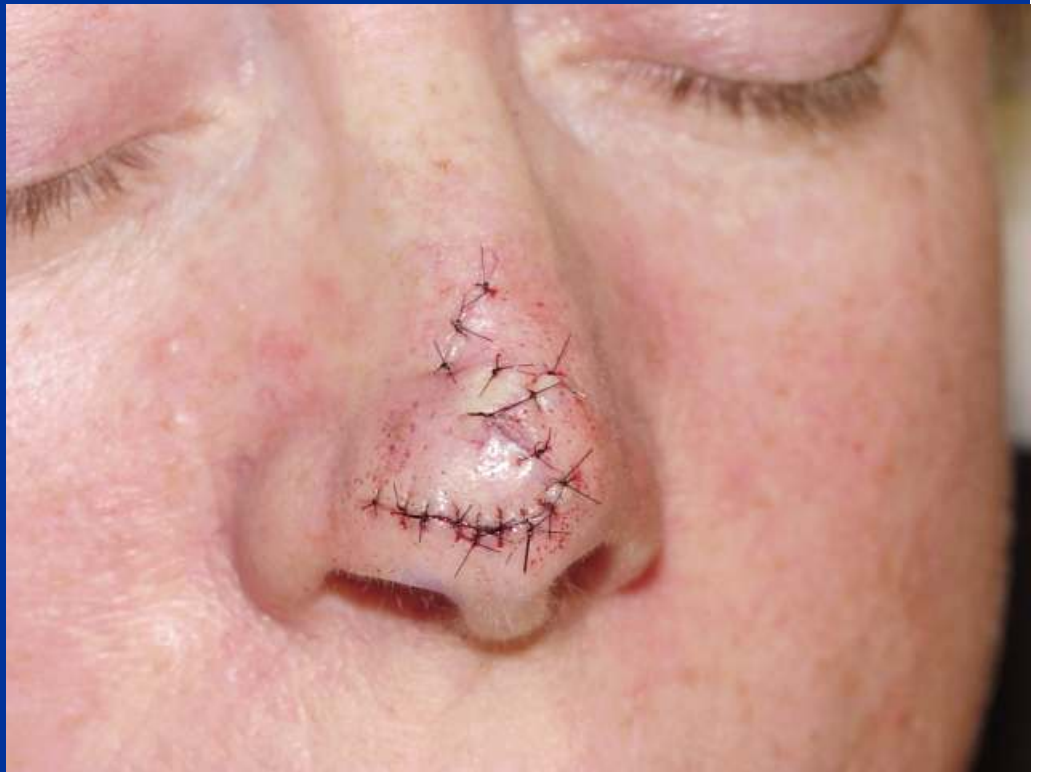
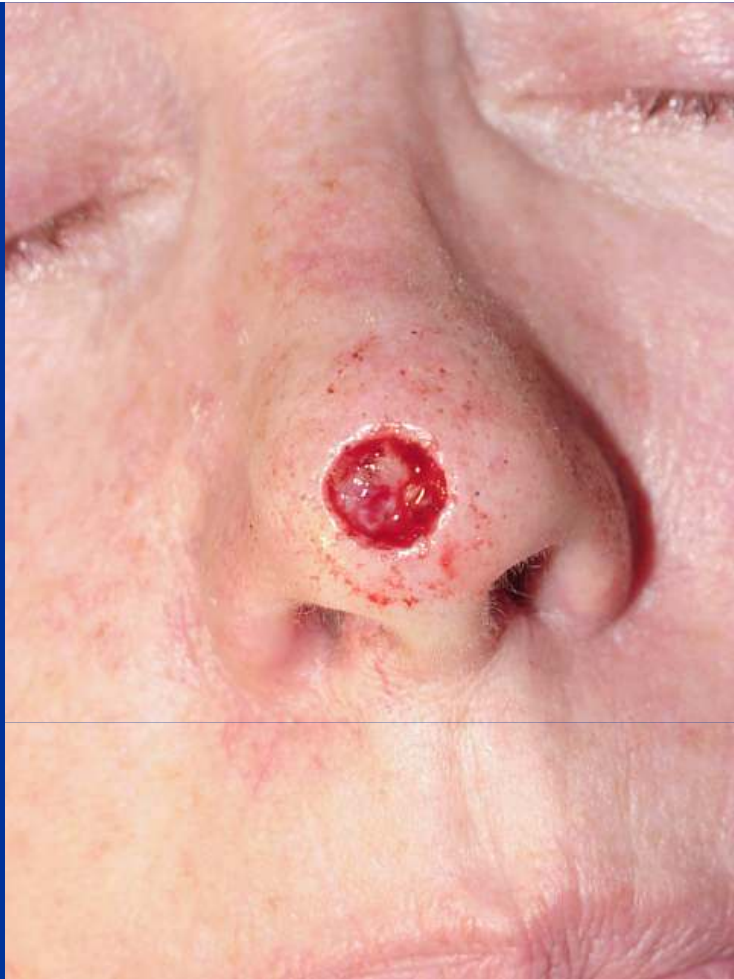


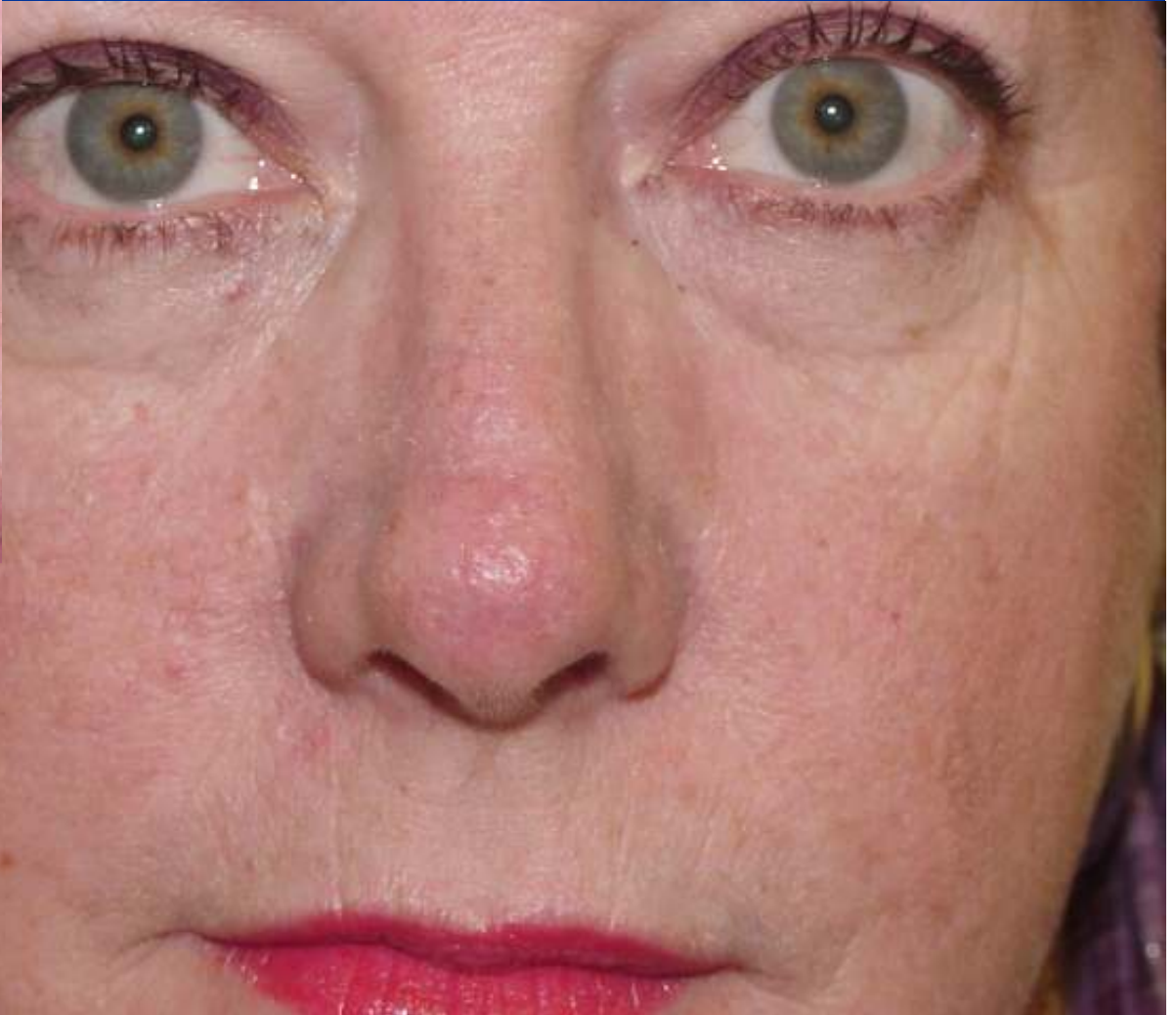
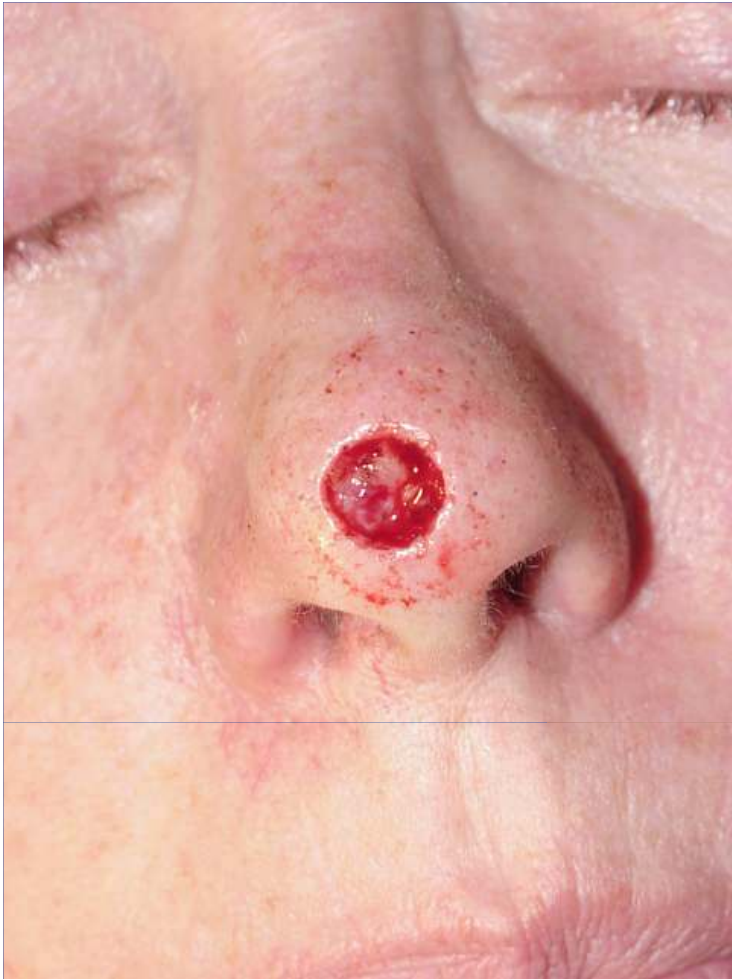


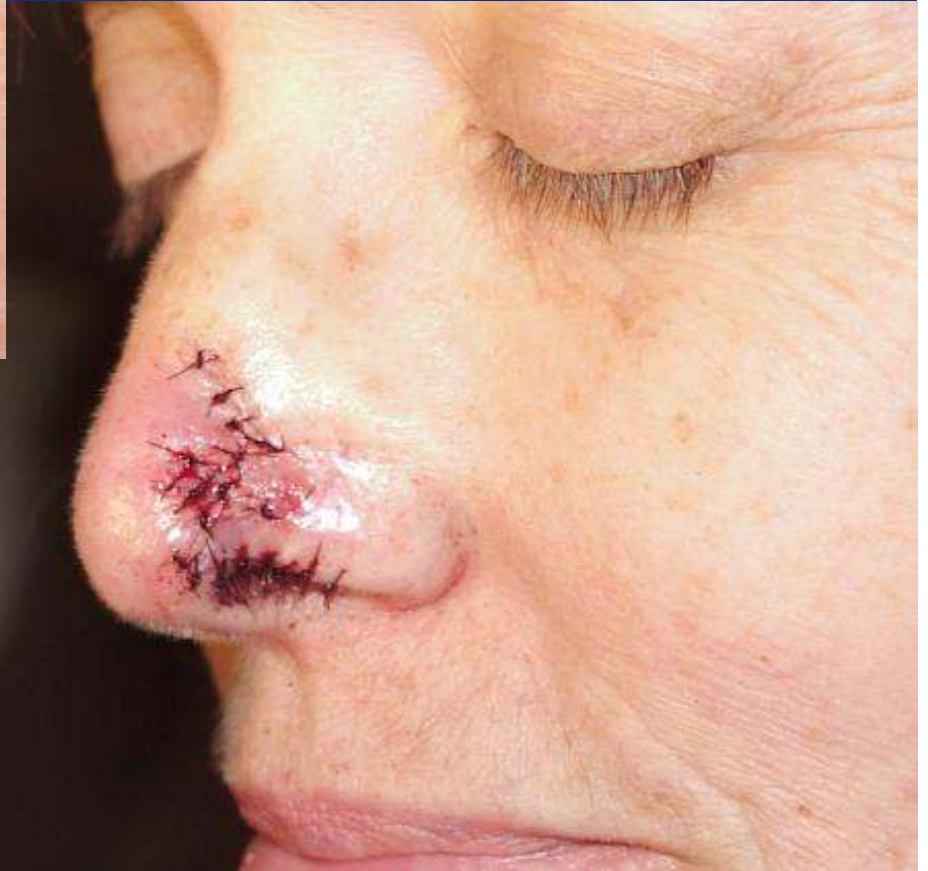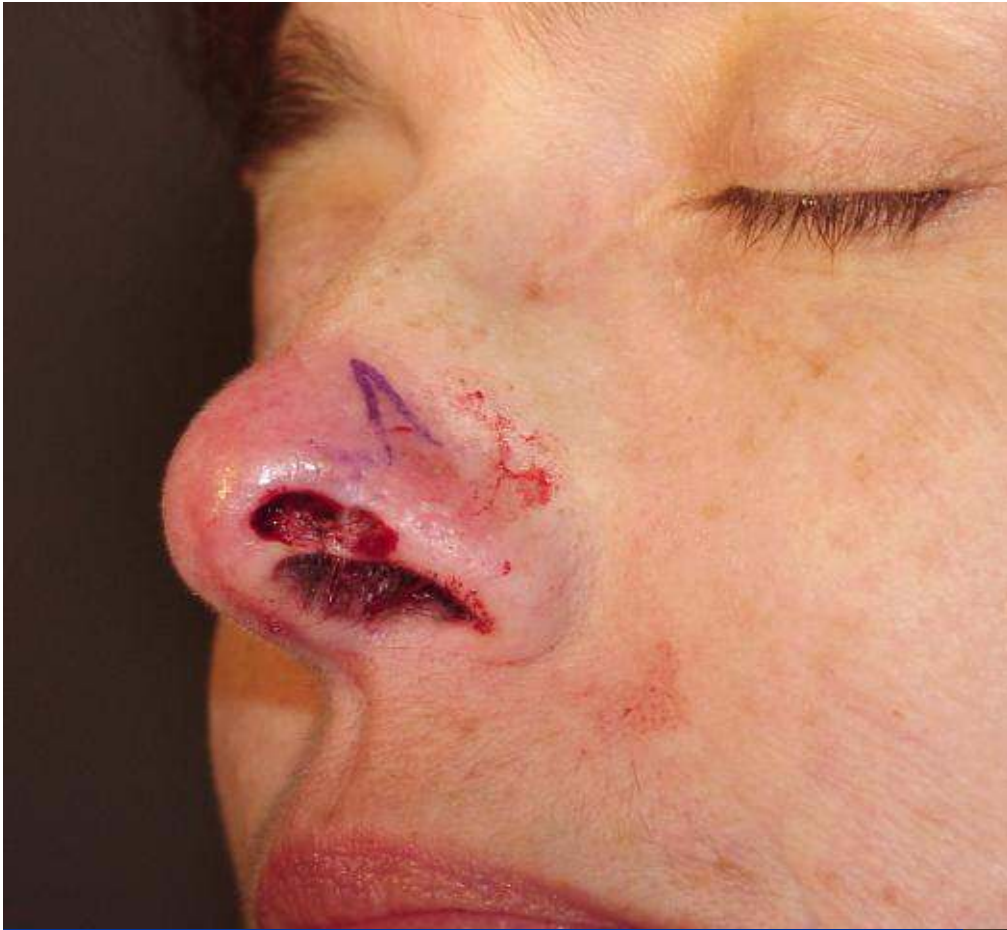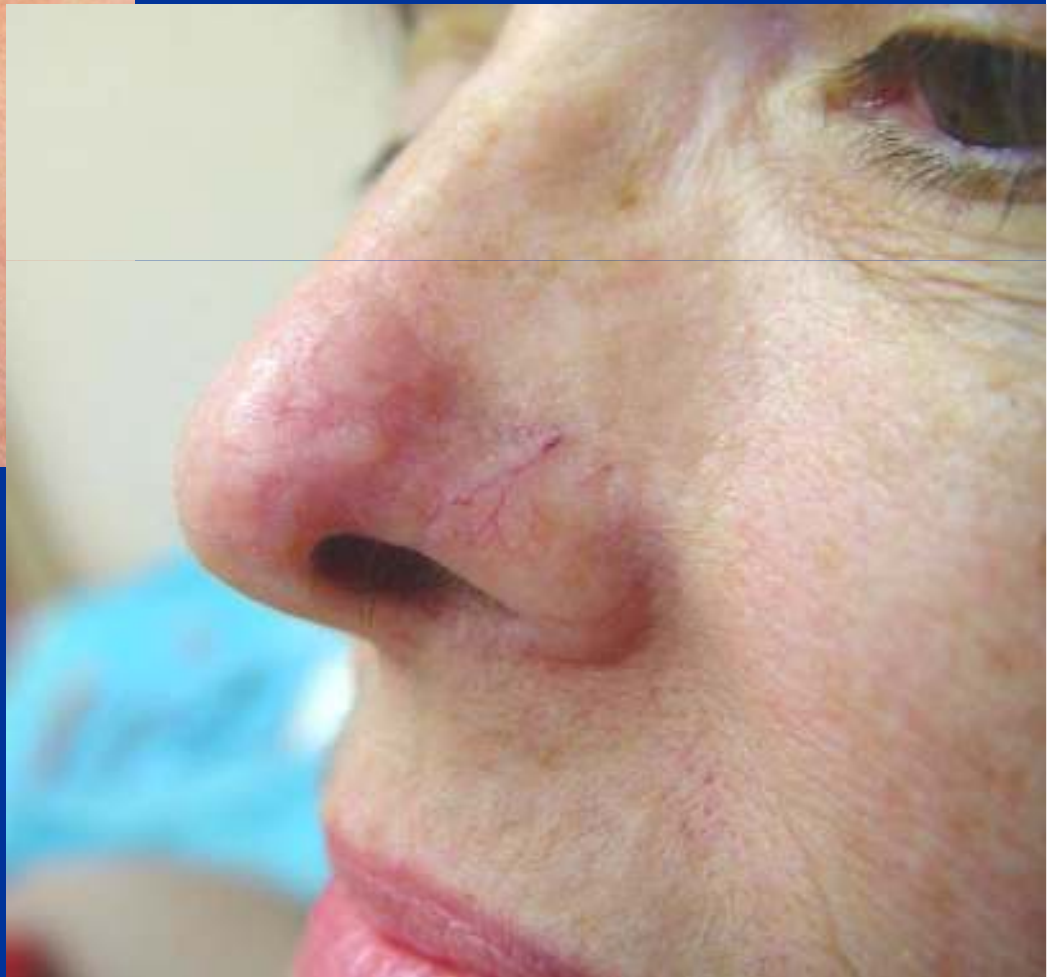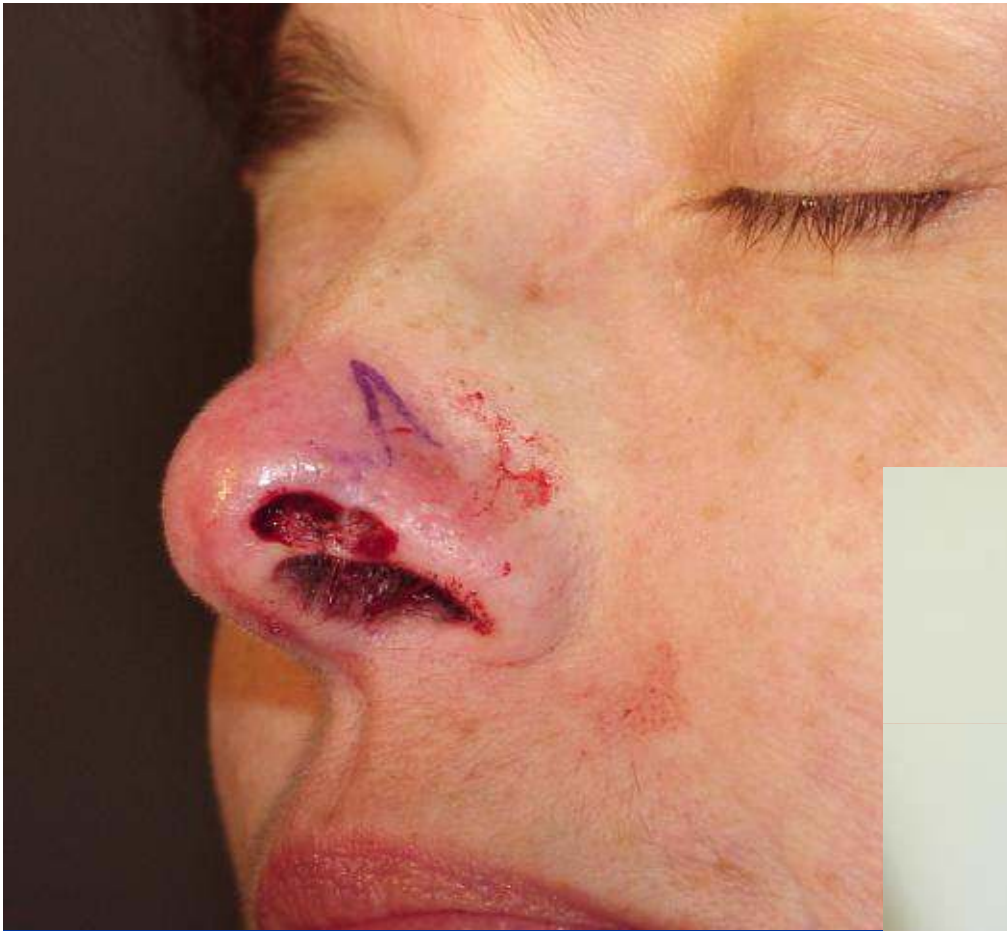6 weeks later



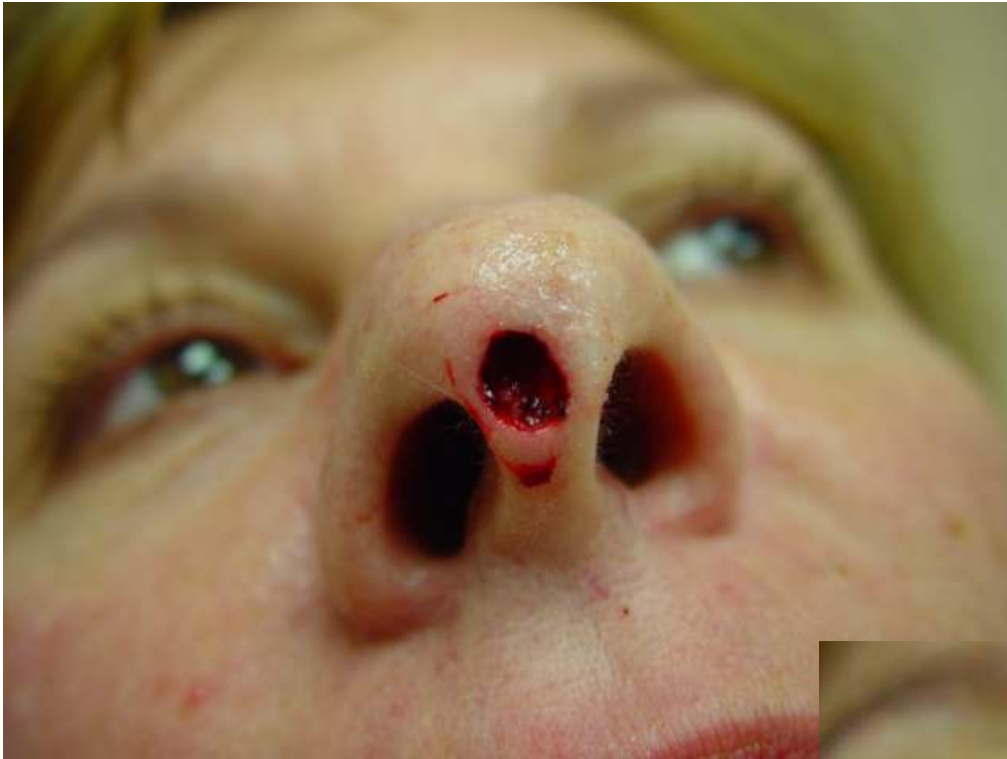

Seven weeks later

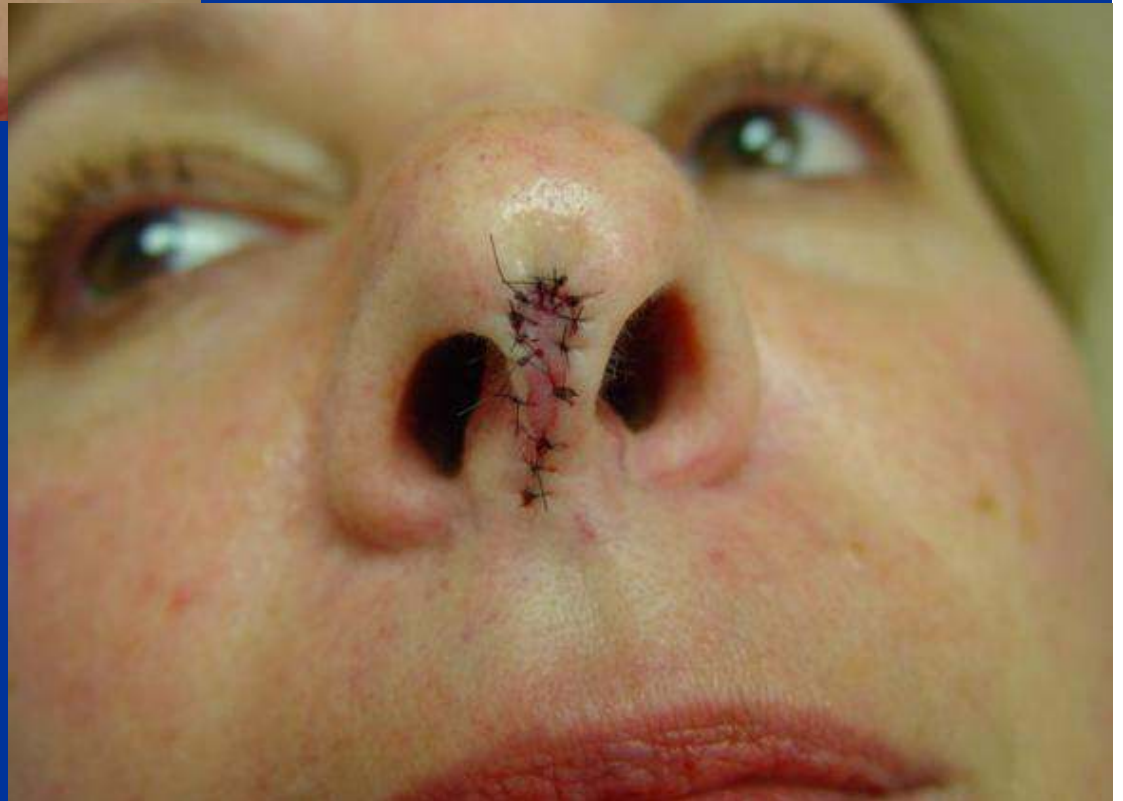


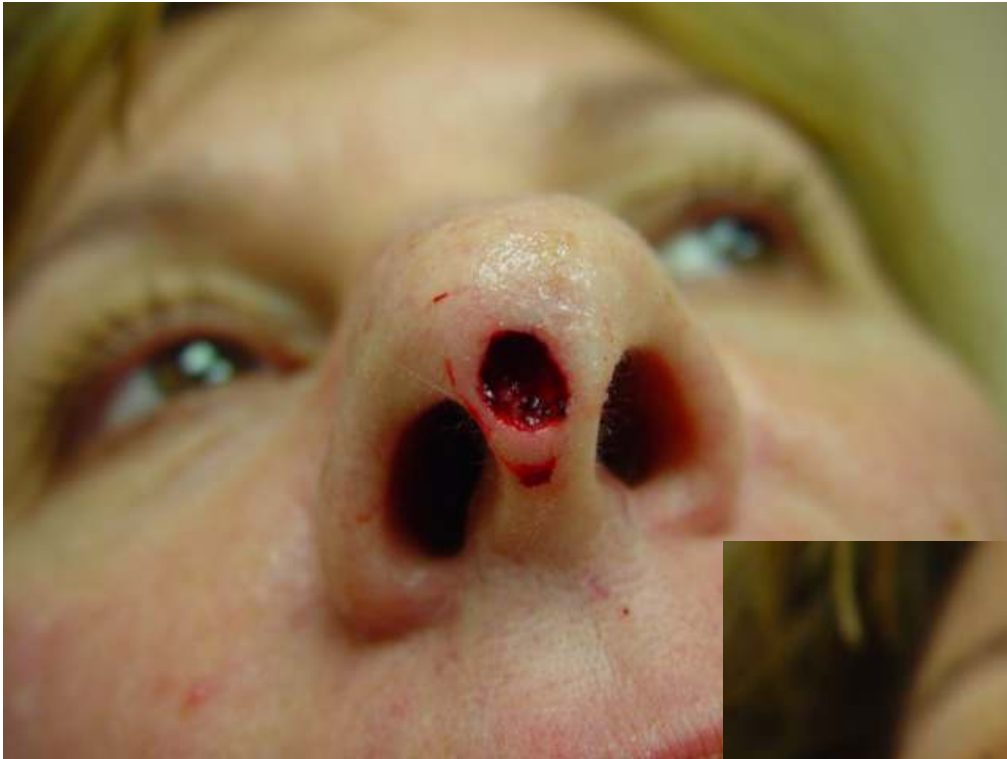
Three months later

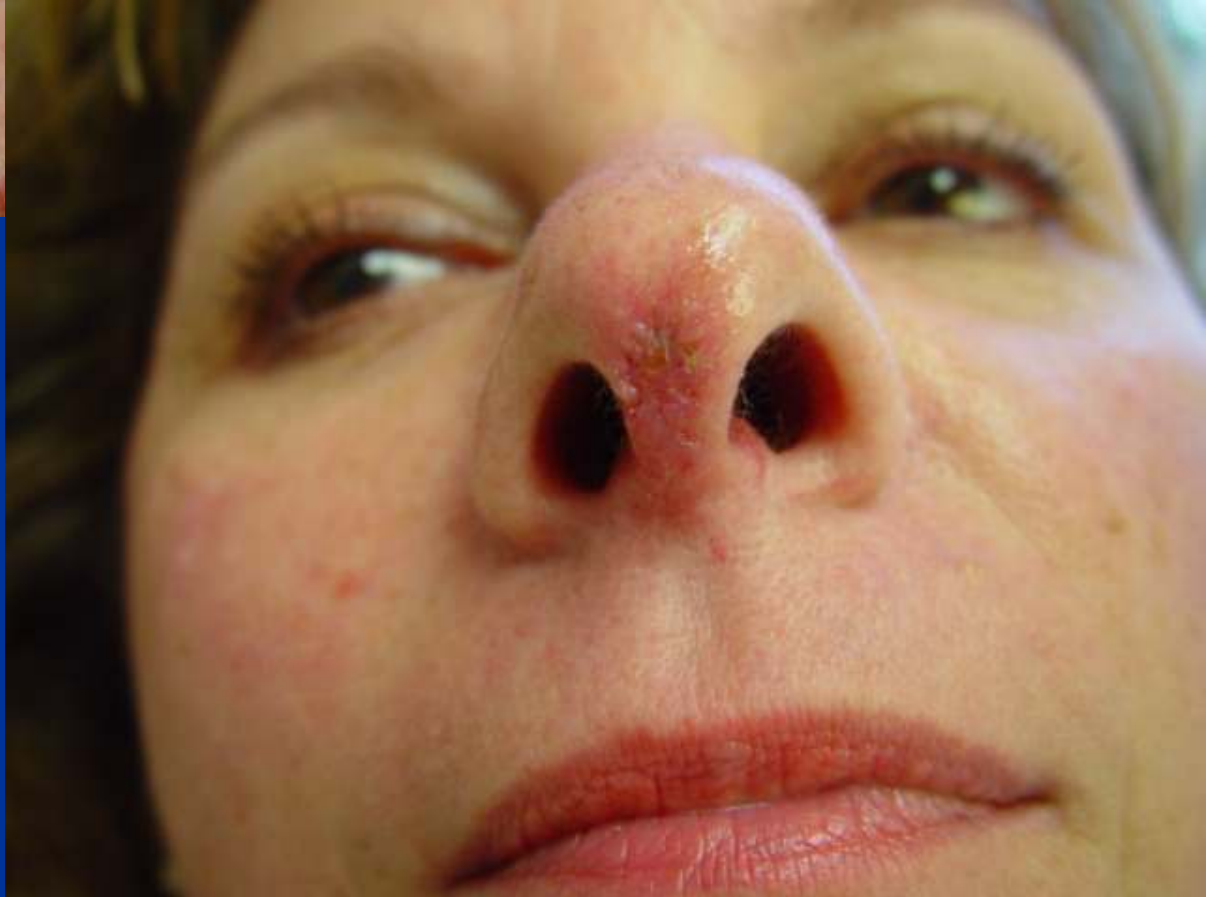

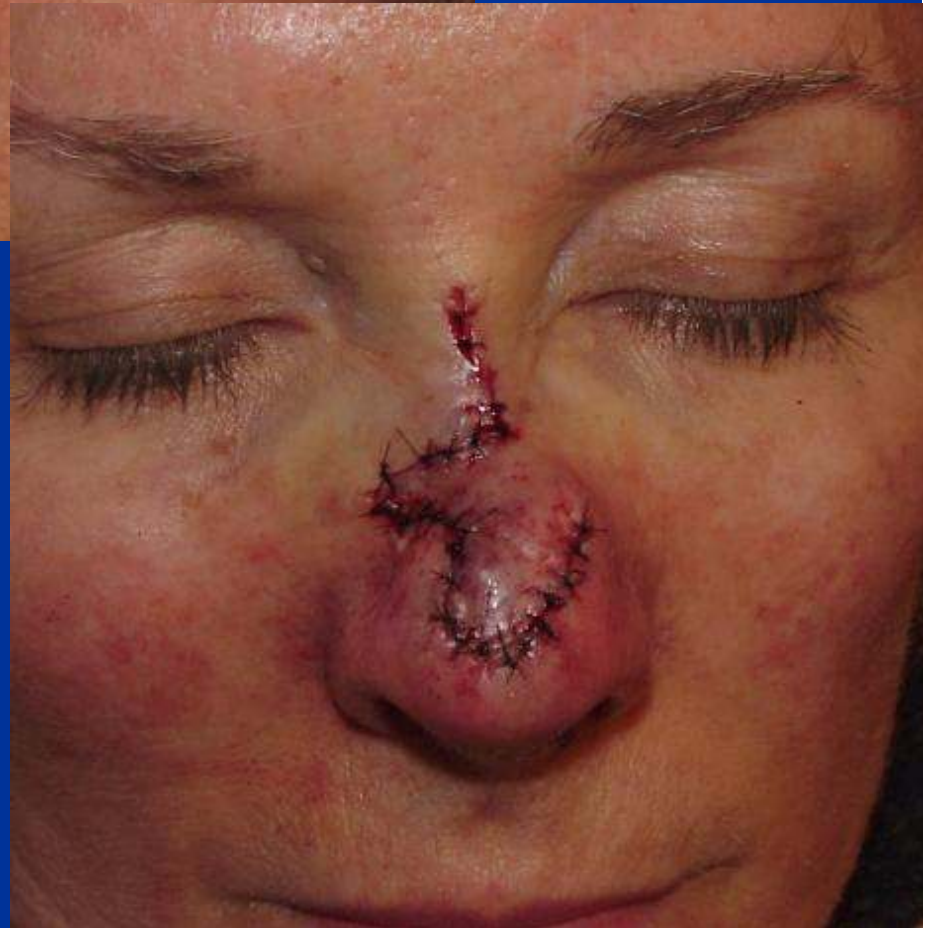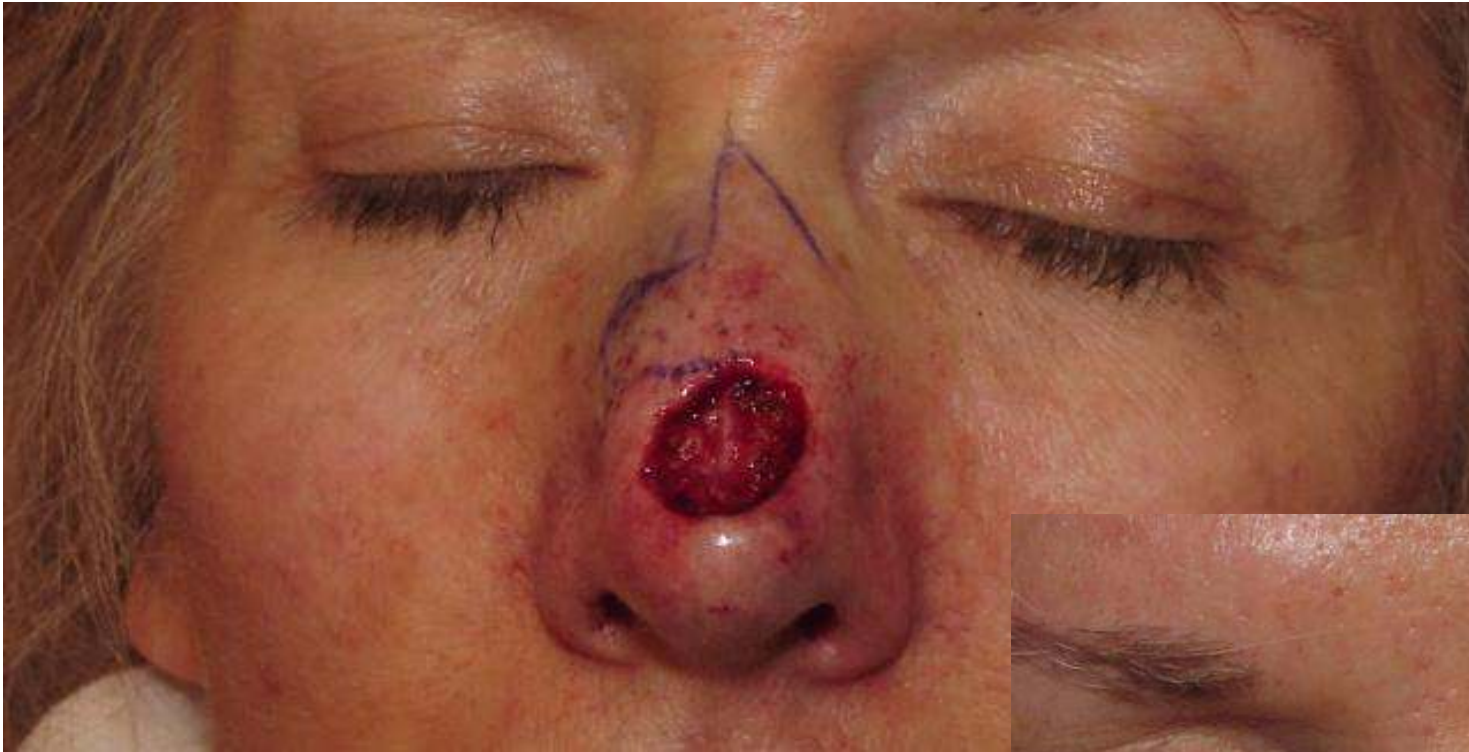Island pedicle flap

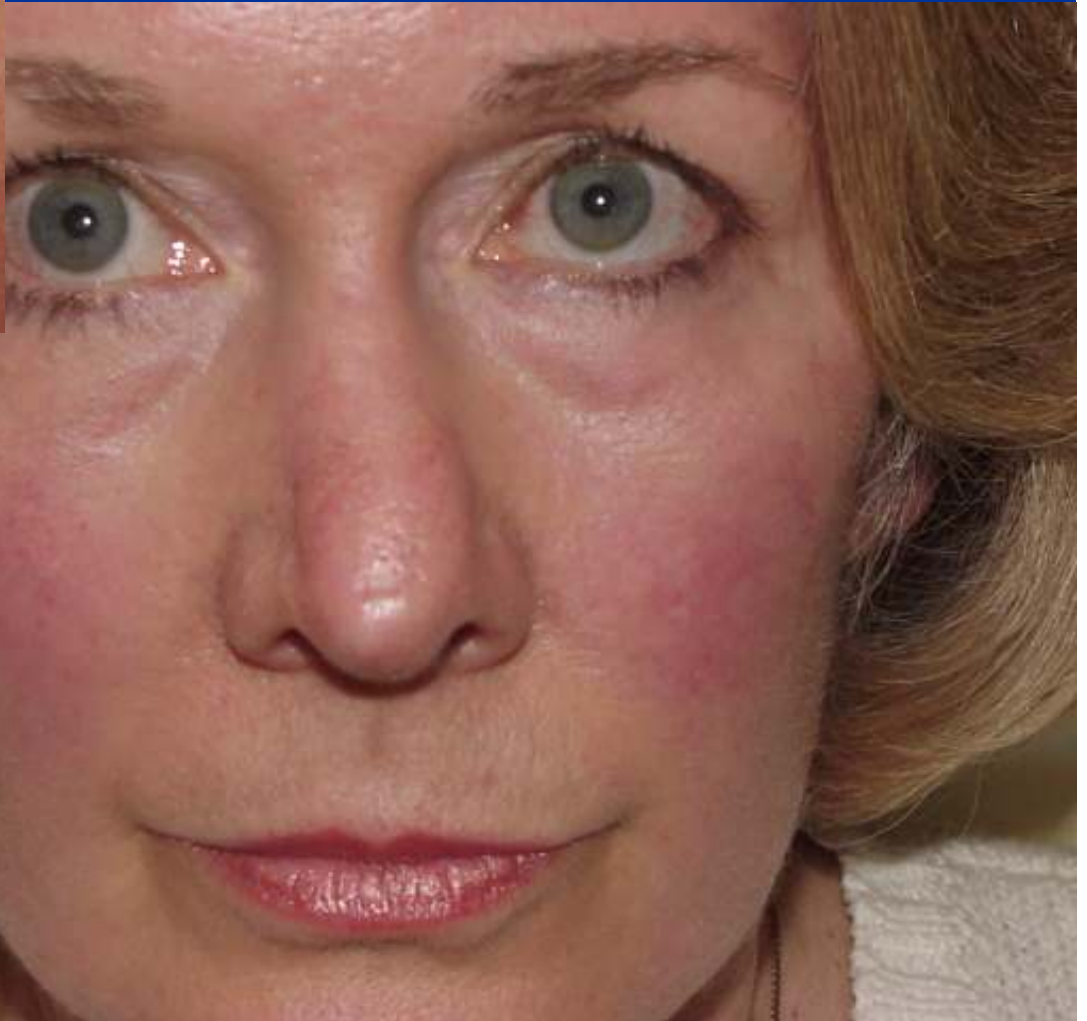
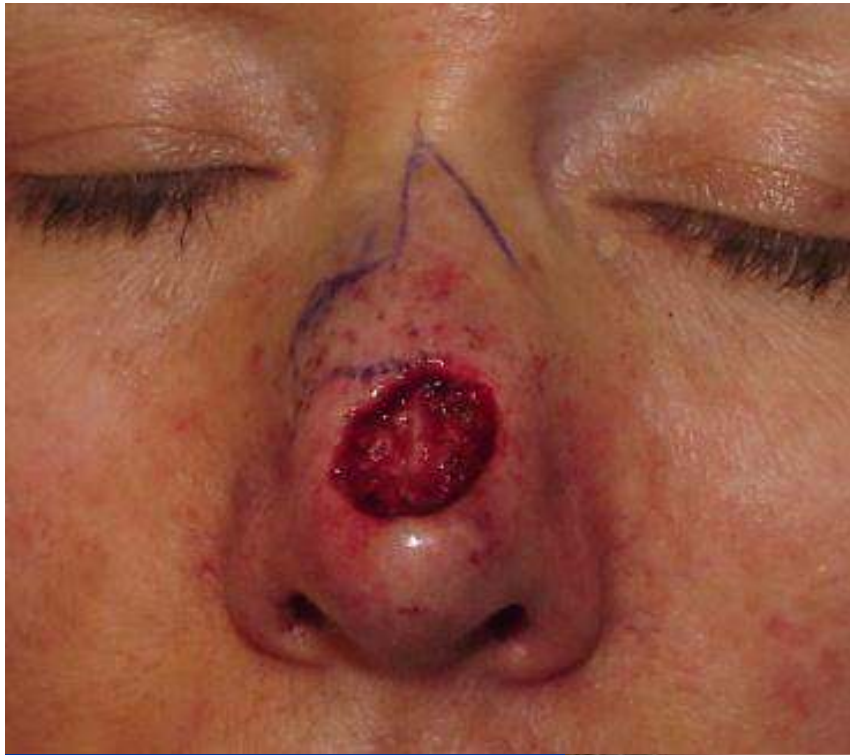


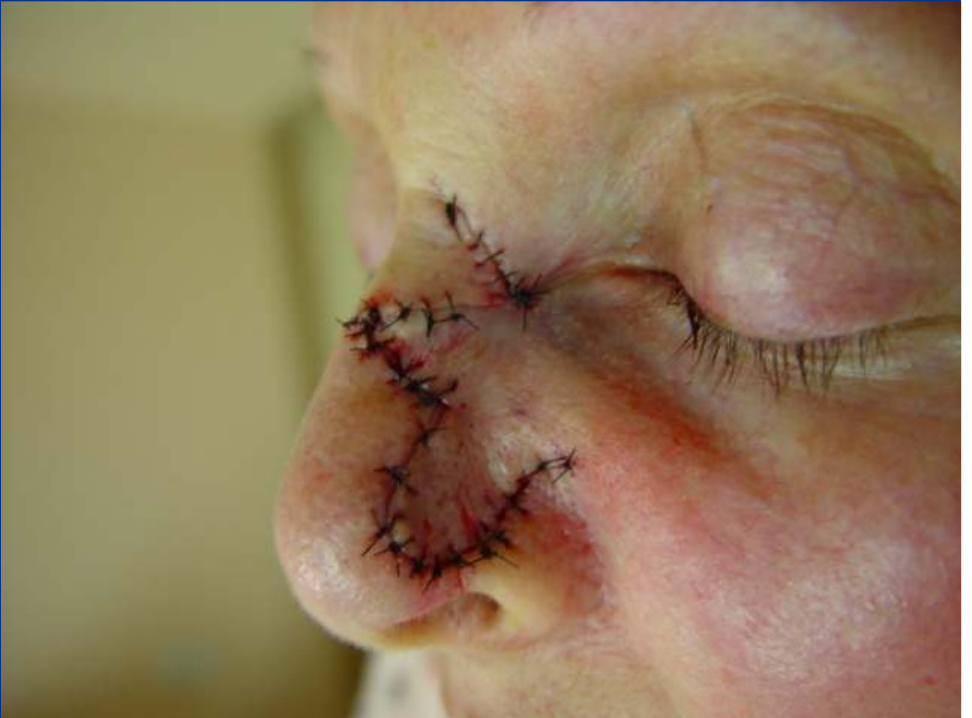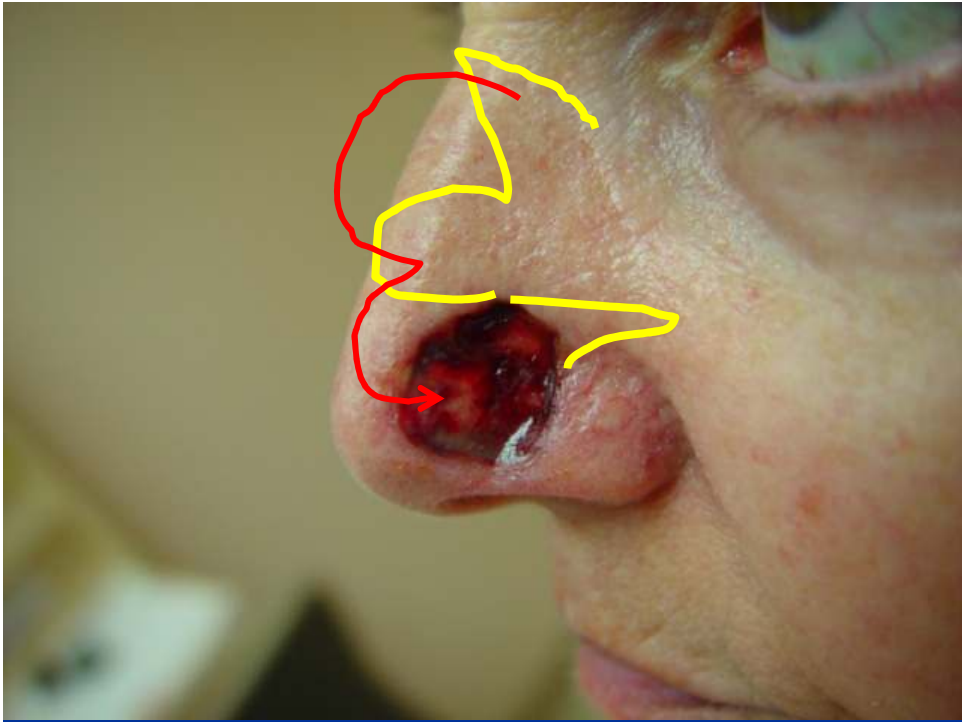
6 days later

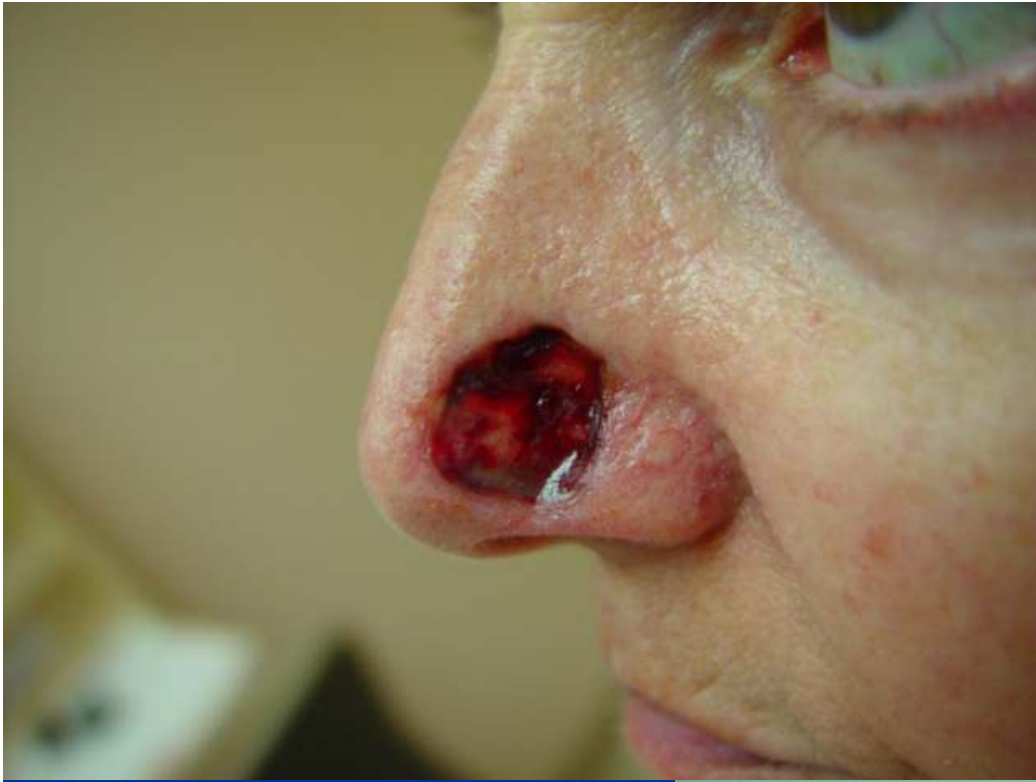




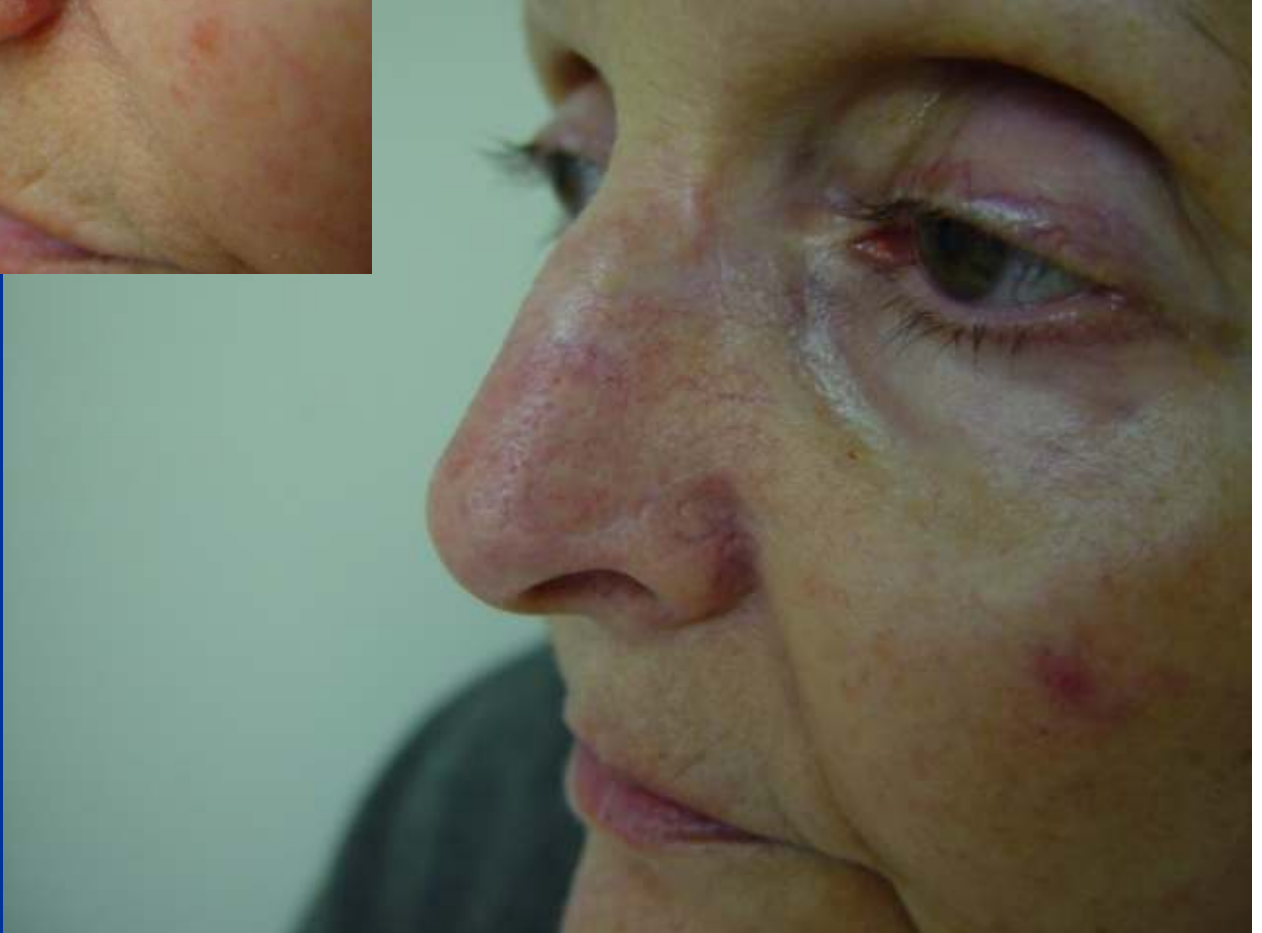
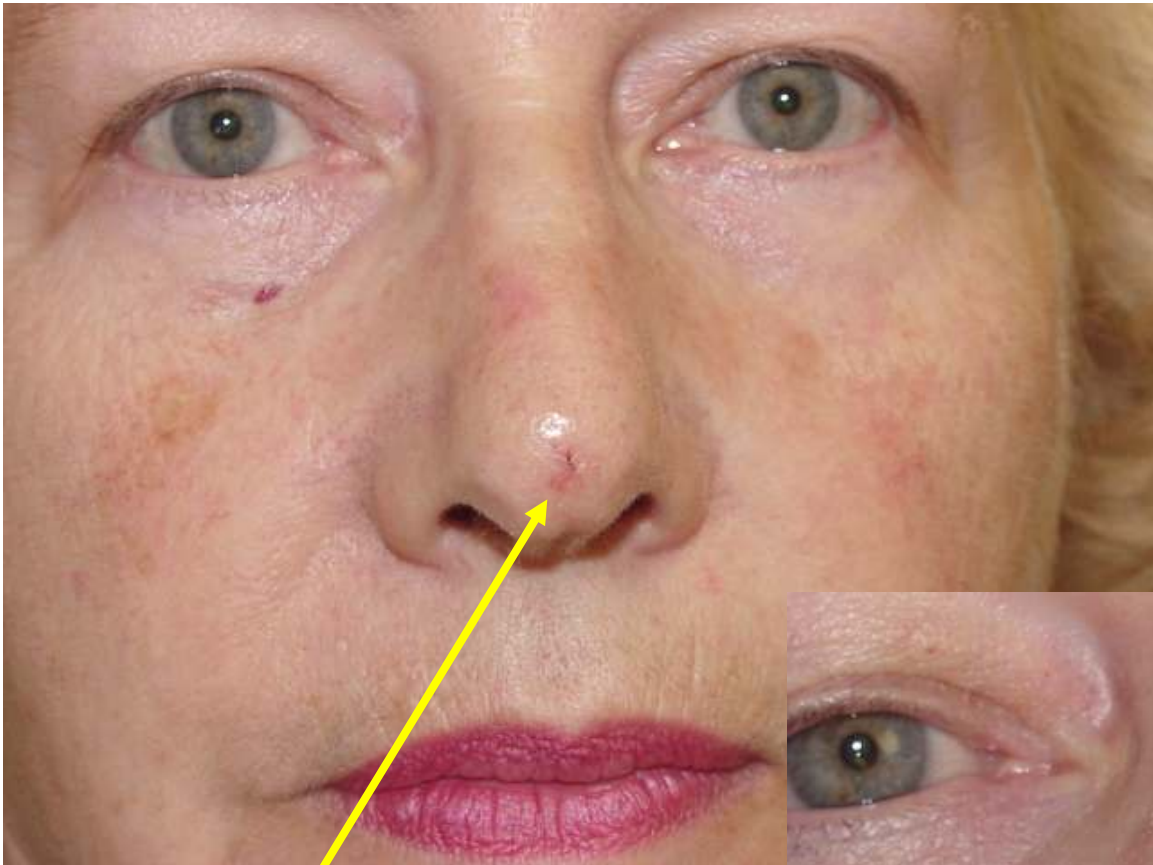Six months later



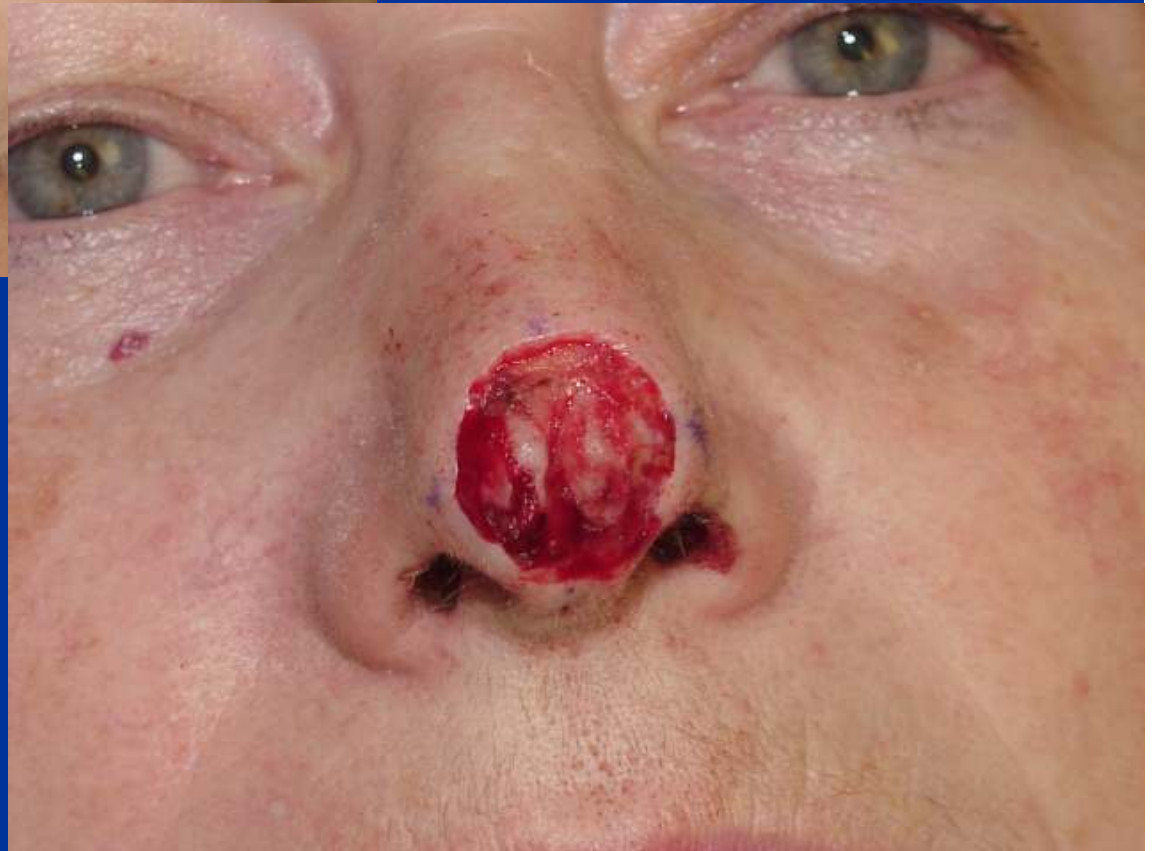

6 months later

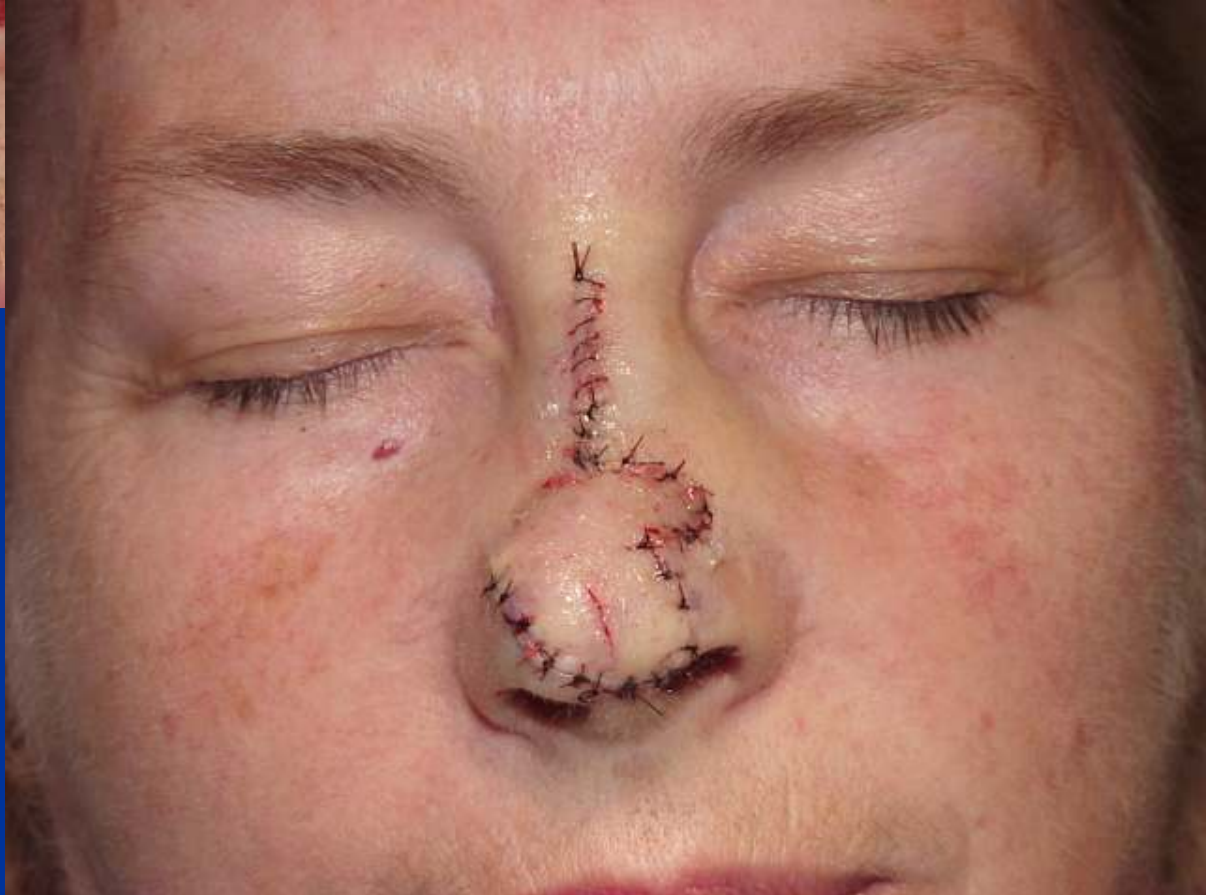
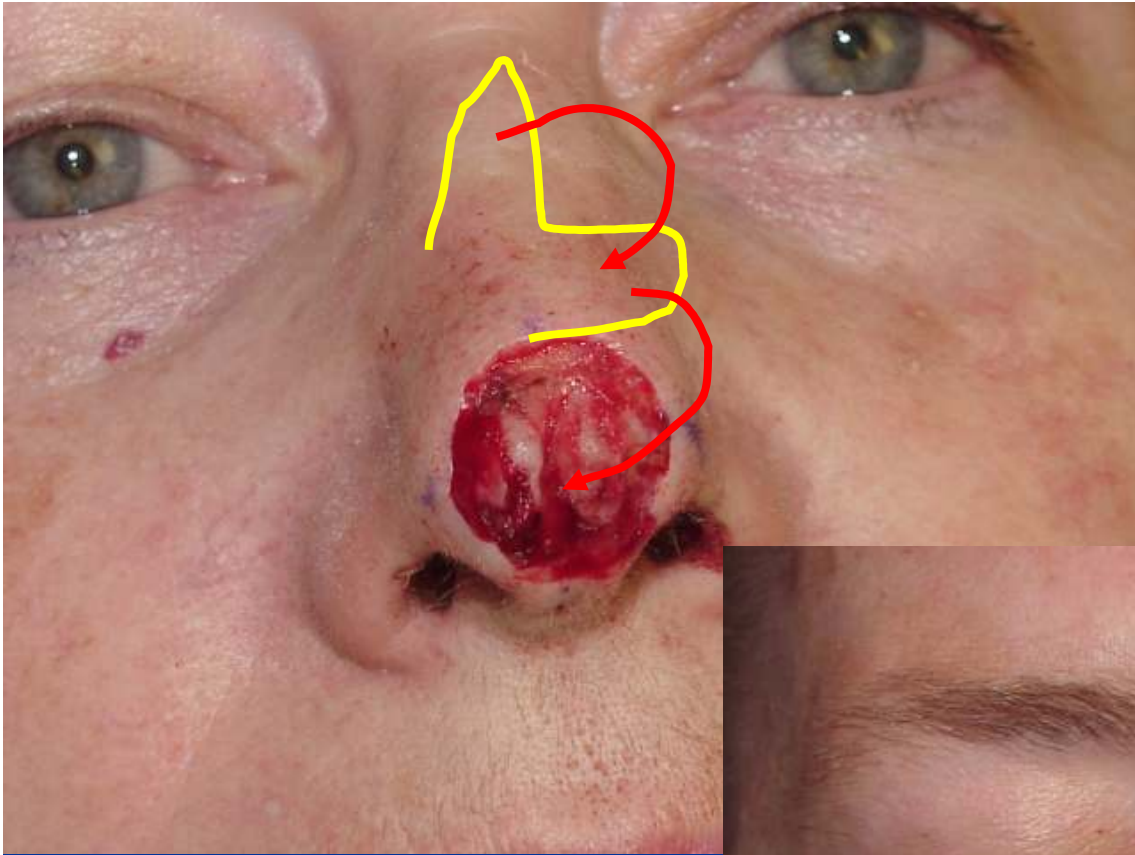


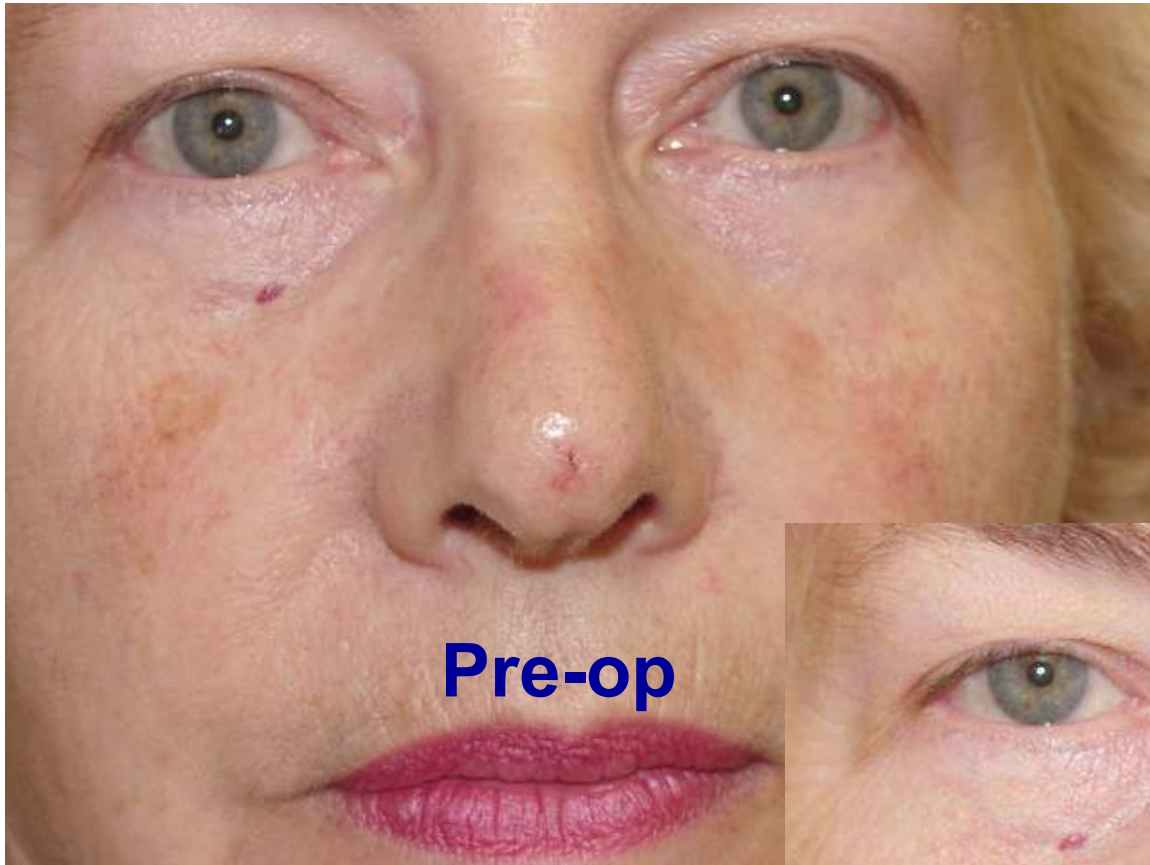**67-year-old woman  
BCC  
No prior treatment**

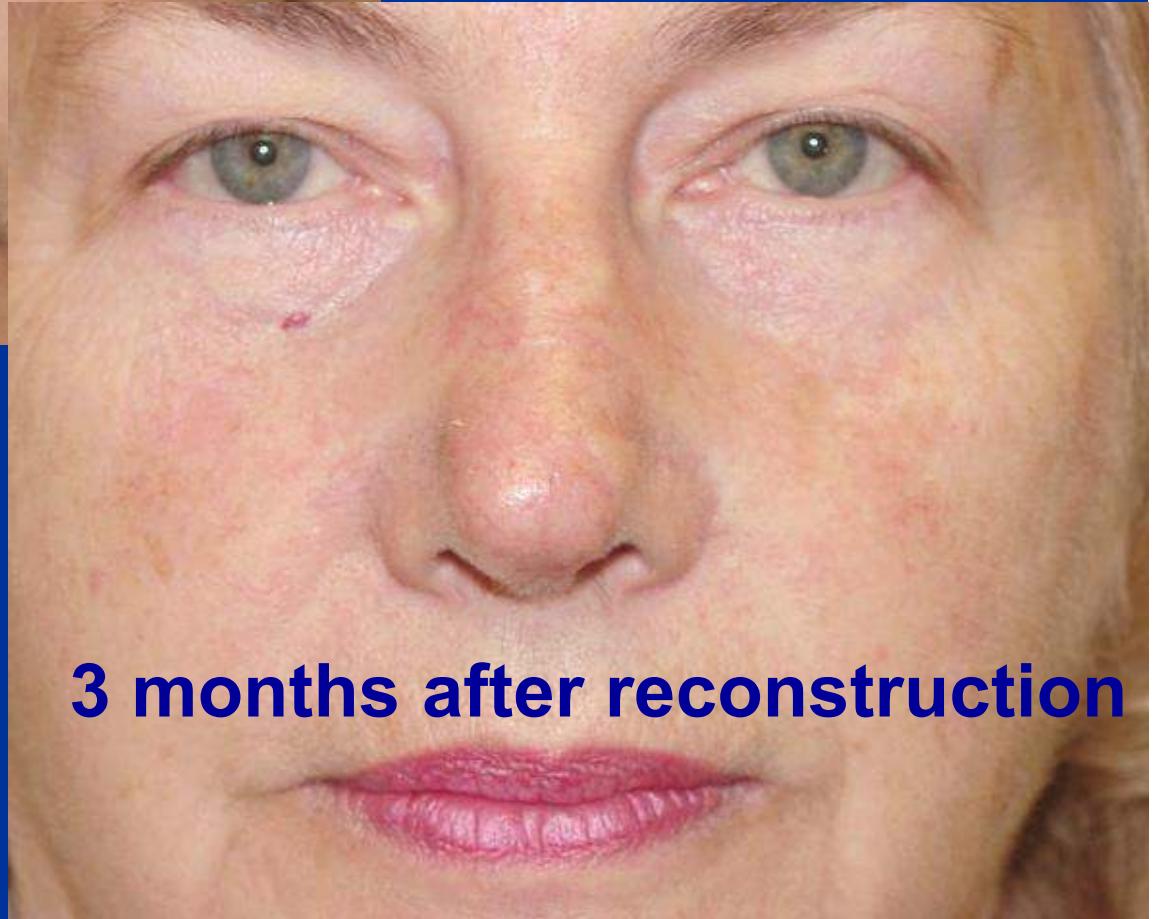

**6 stages / 12 sections**

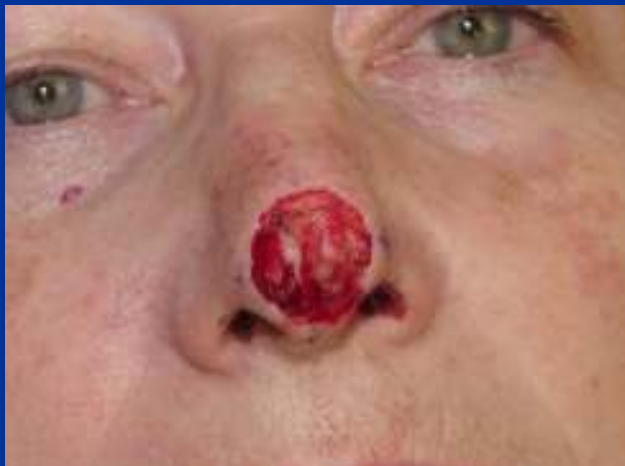


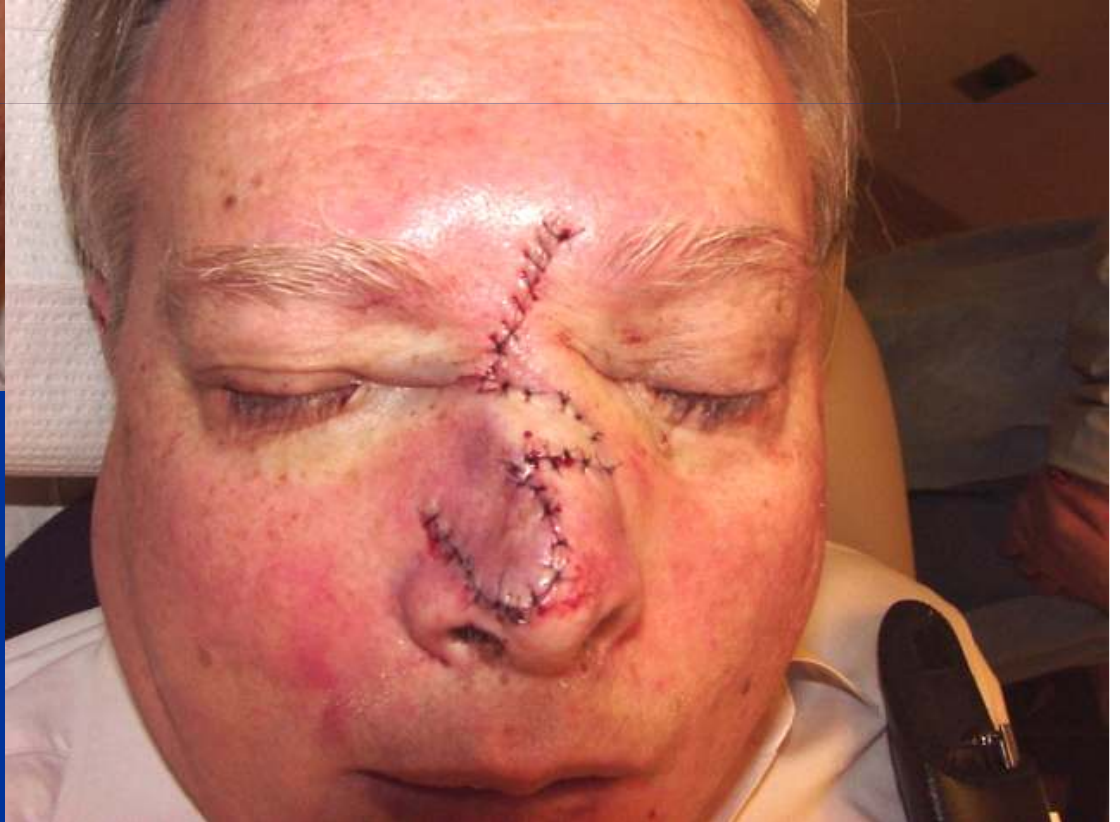
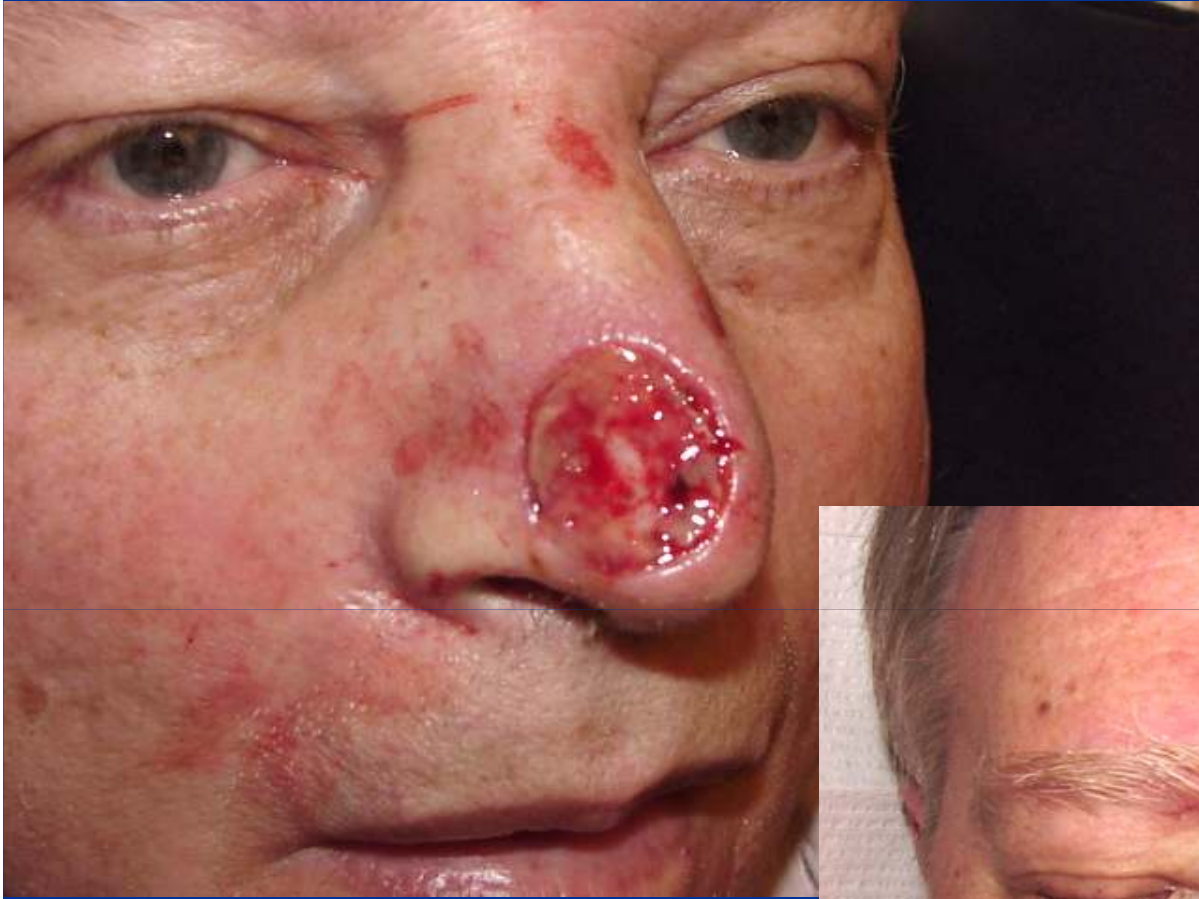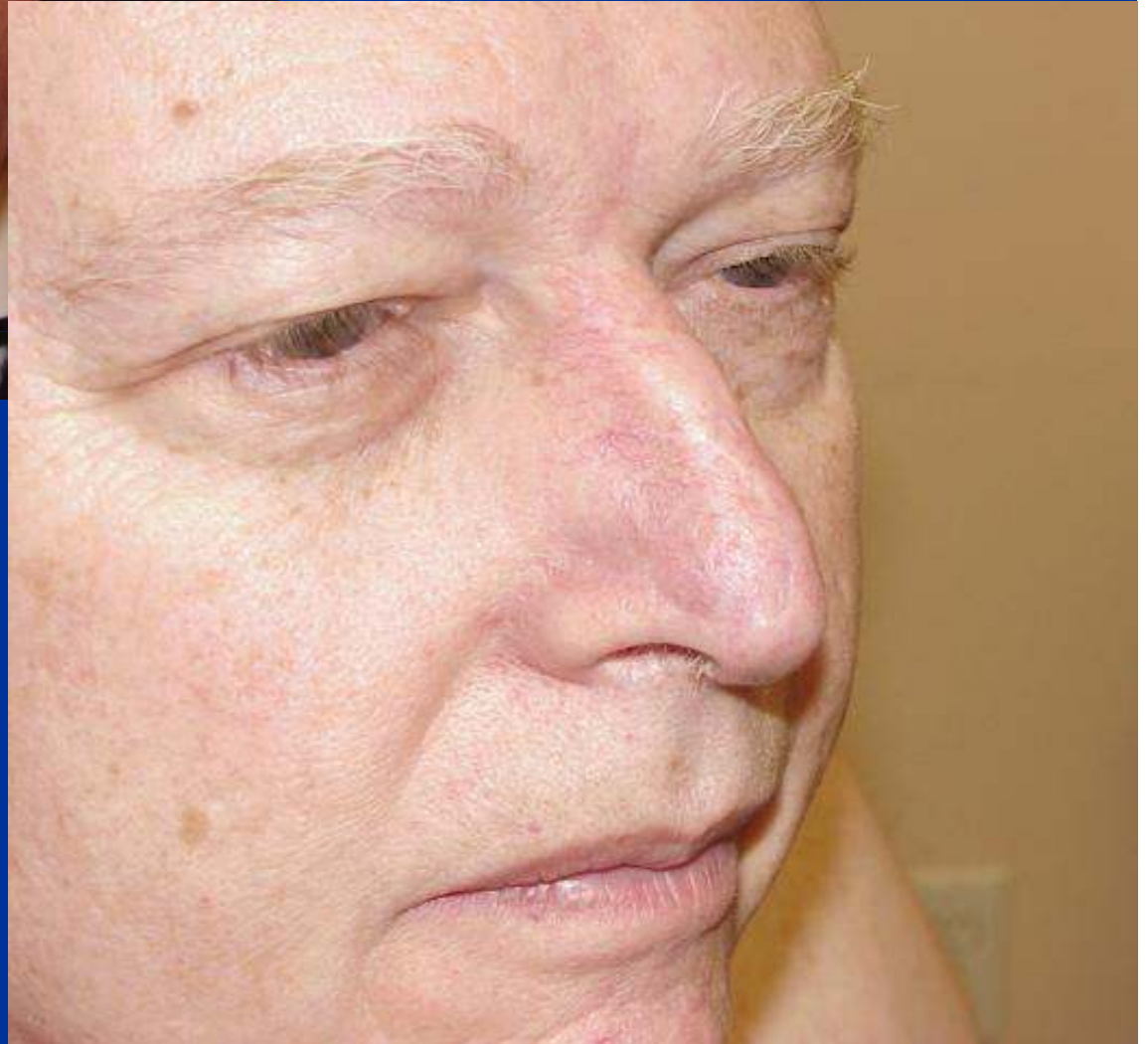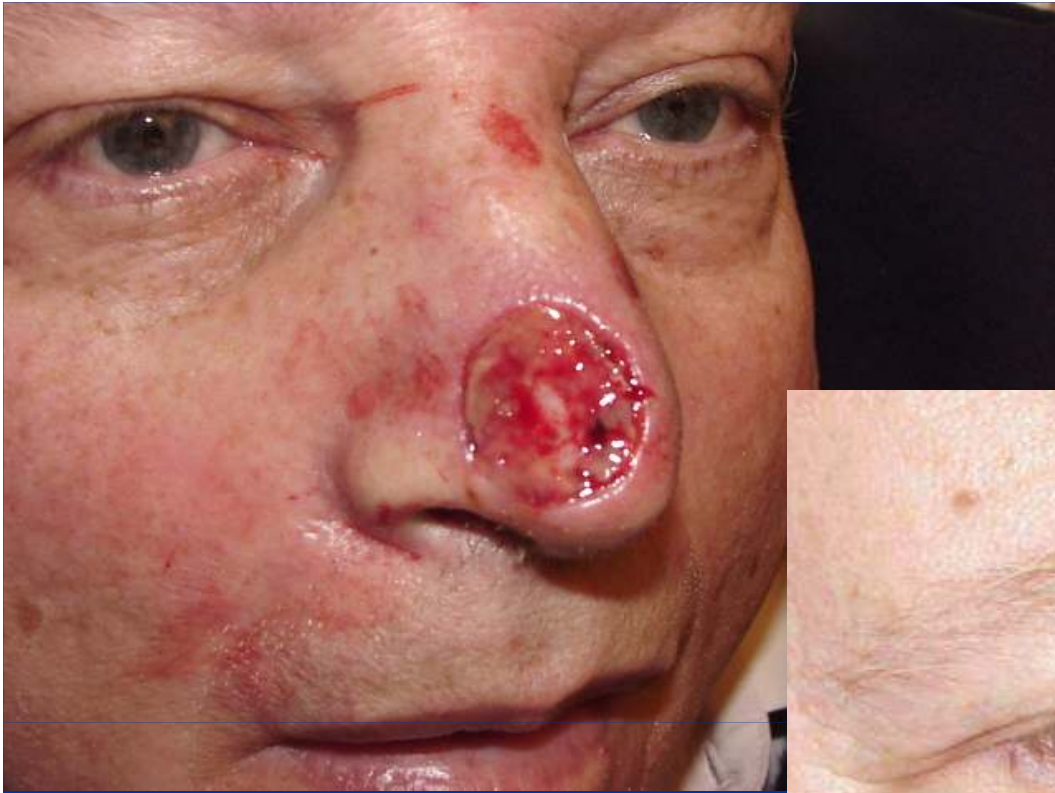**Pre-op**



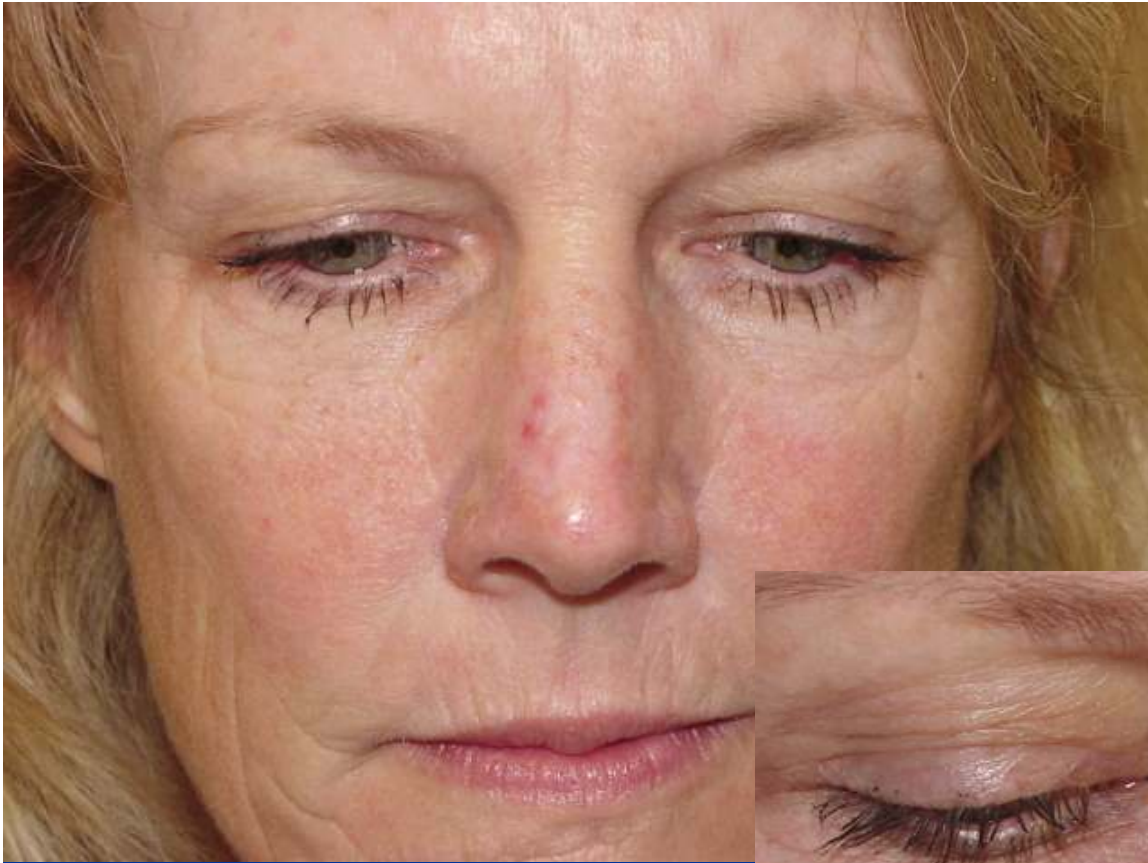**3 months after reconstruction**



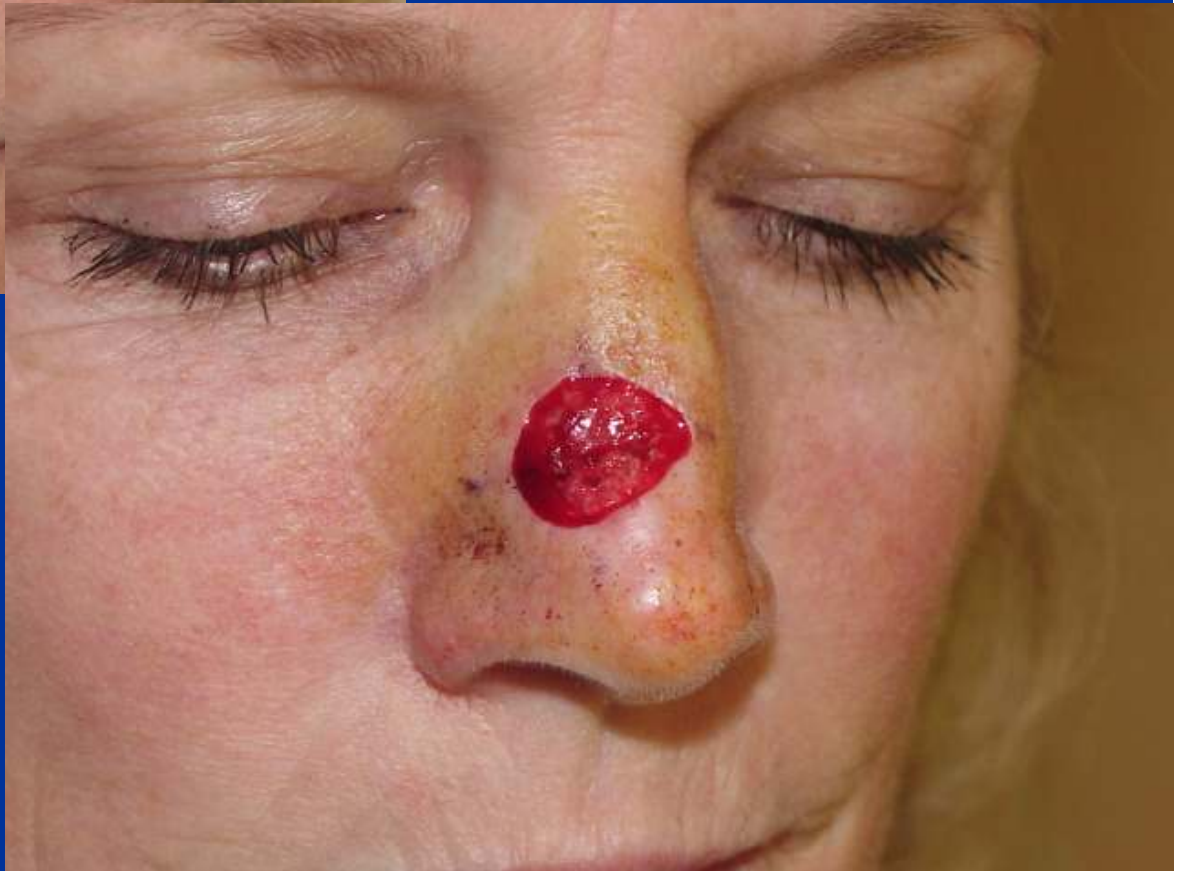



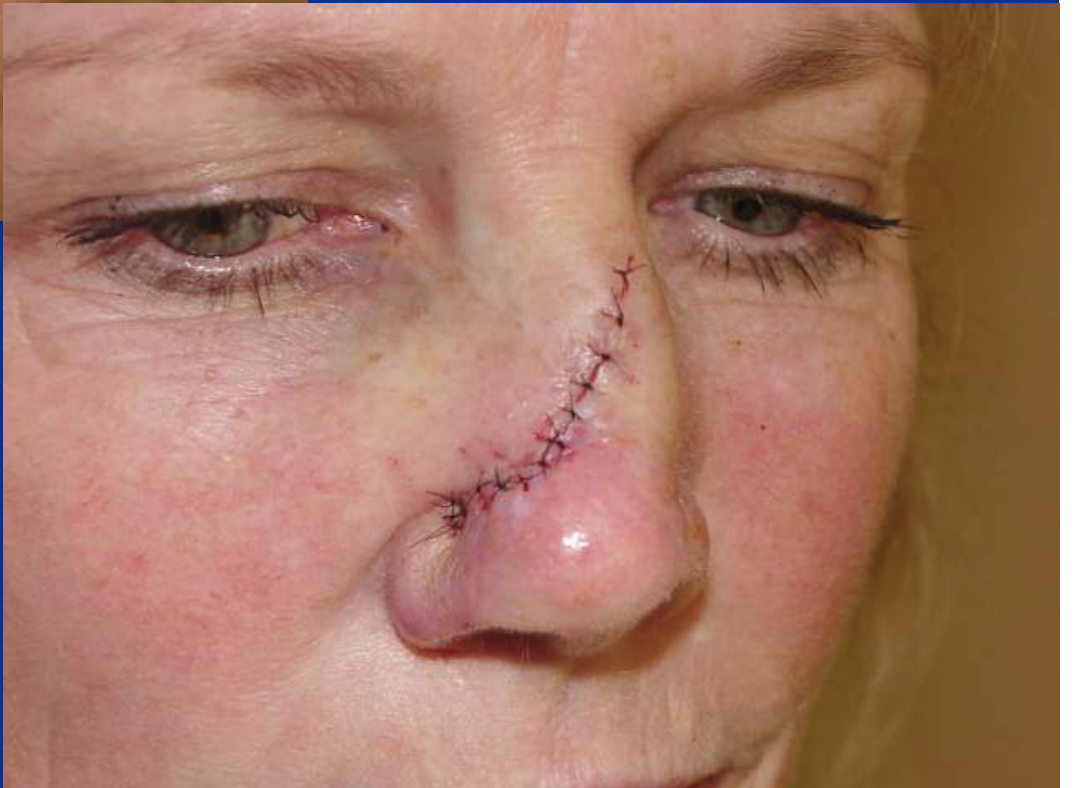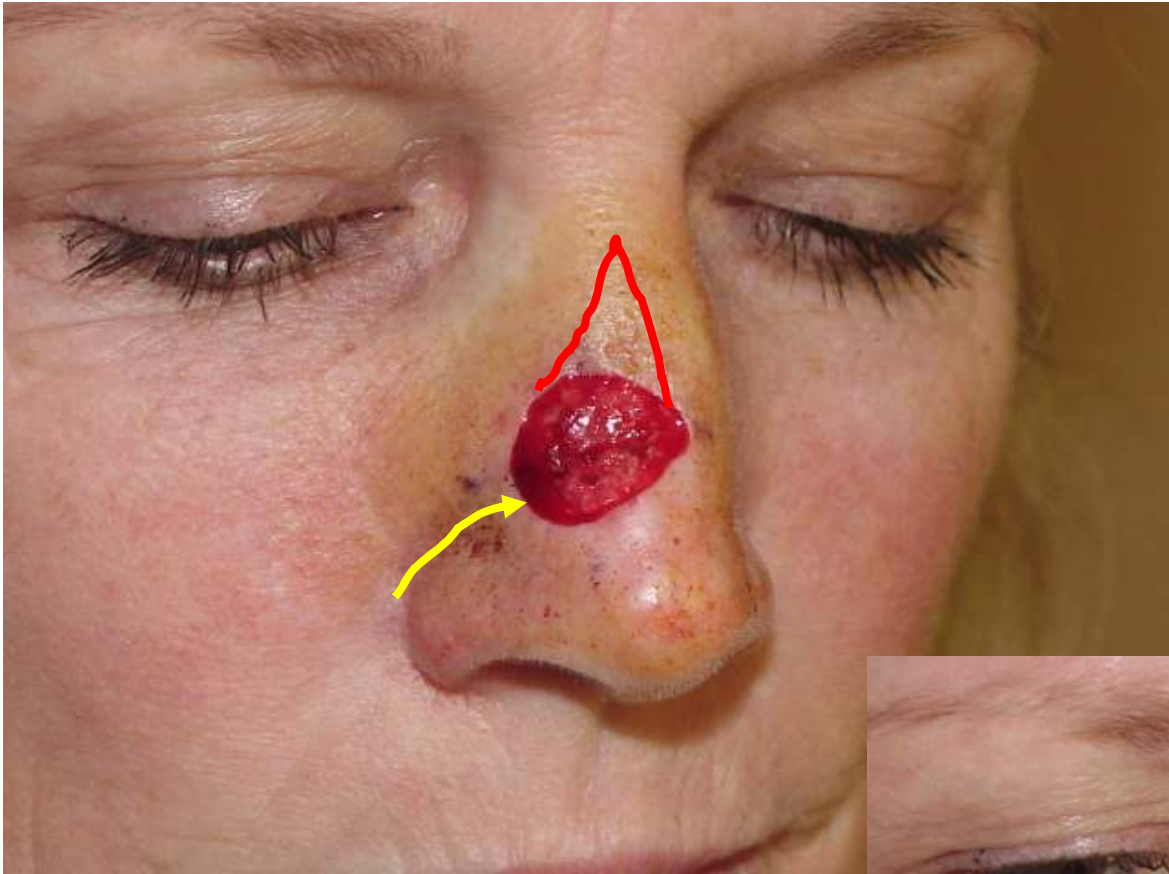Six months later

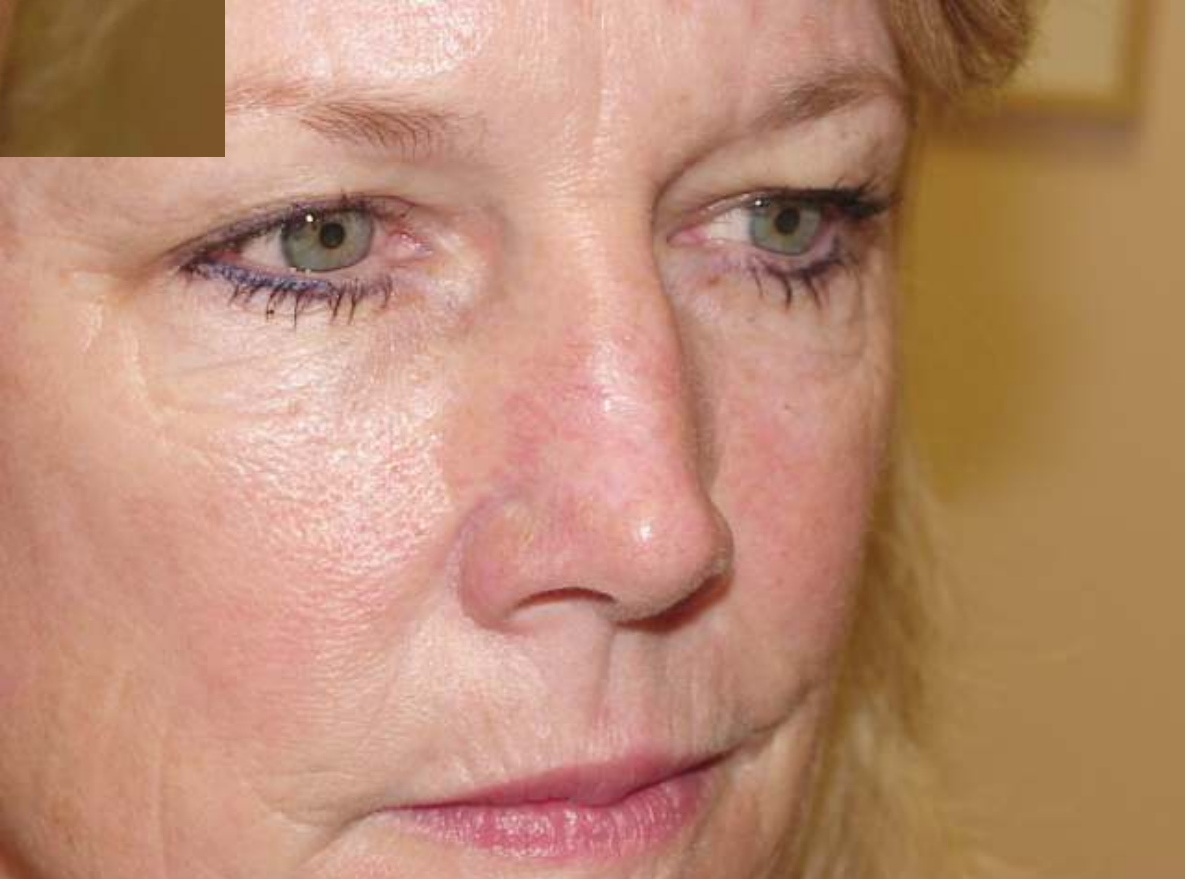
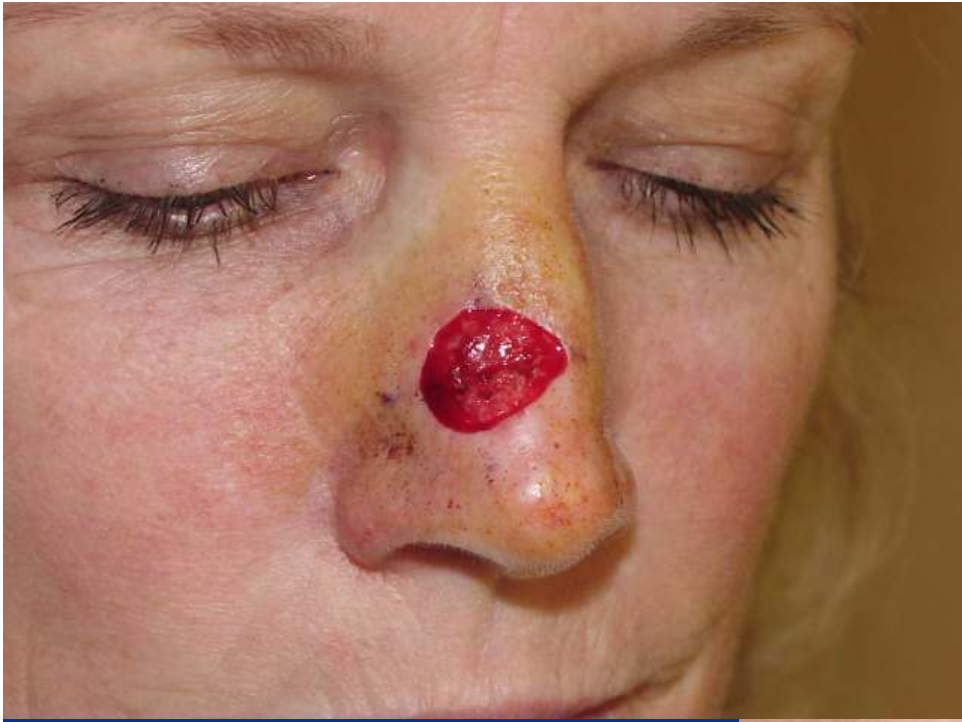
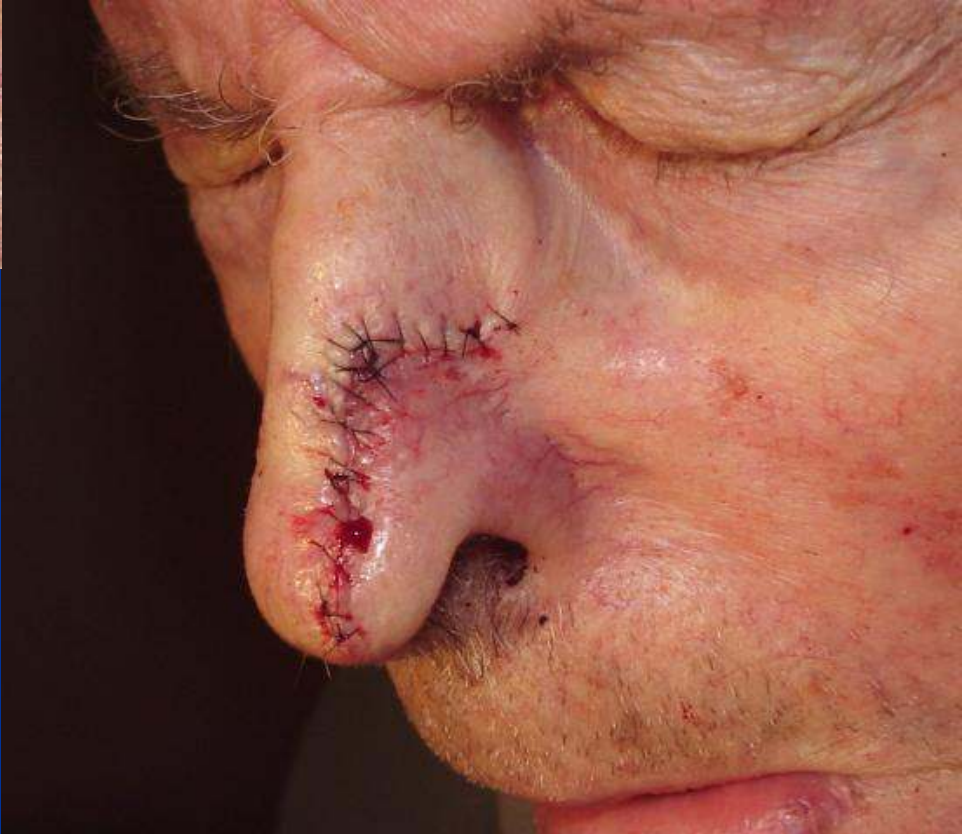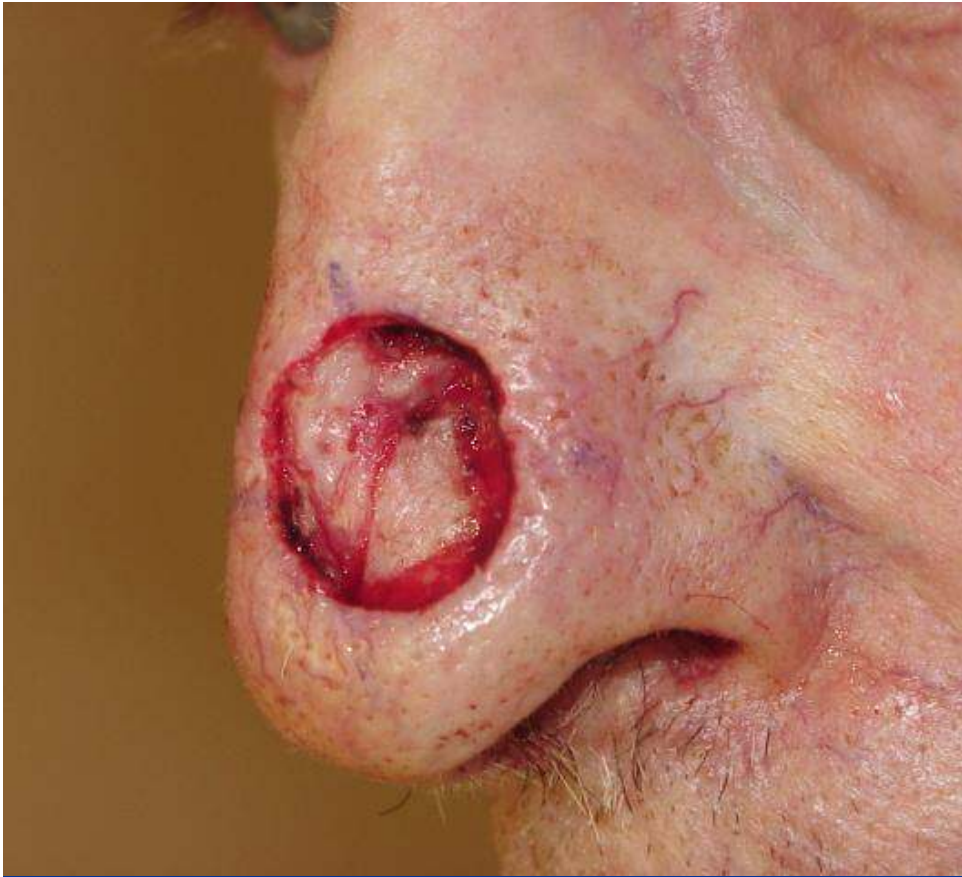
**50-year-old woman  
Recurrent BCC  
s/p cryosurgery + 5-FU**

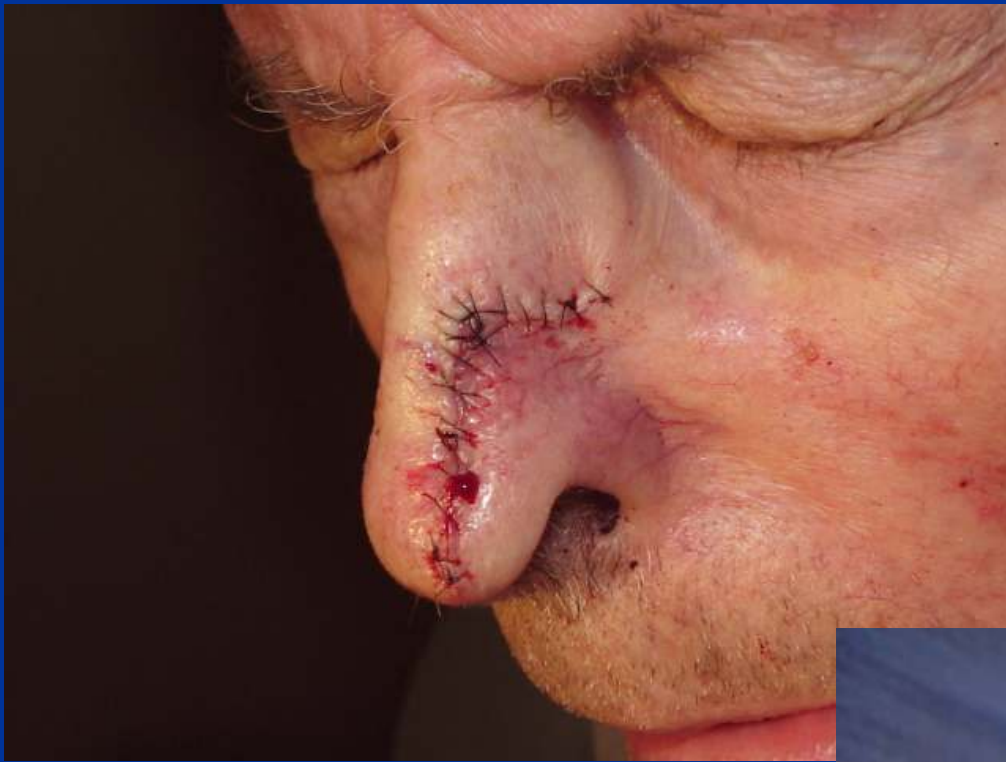

**4 stages / 9 sections**









3 months later



