


Facial Reconstruction

Greg S. Morganroth, MD

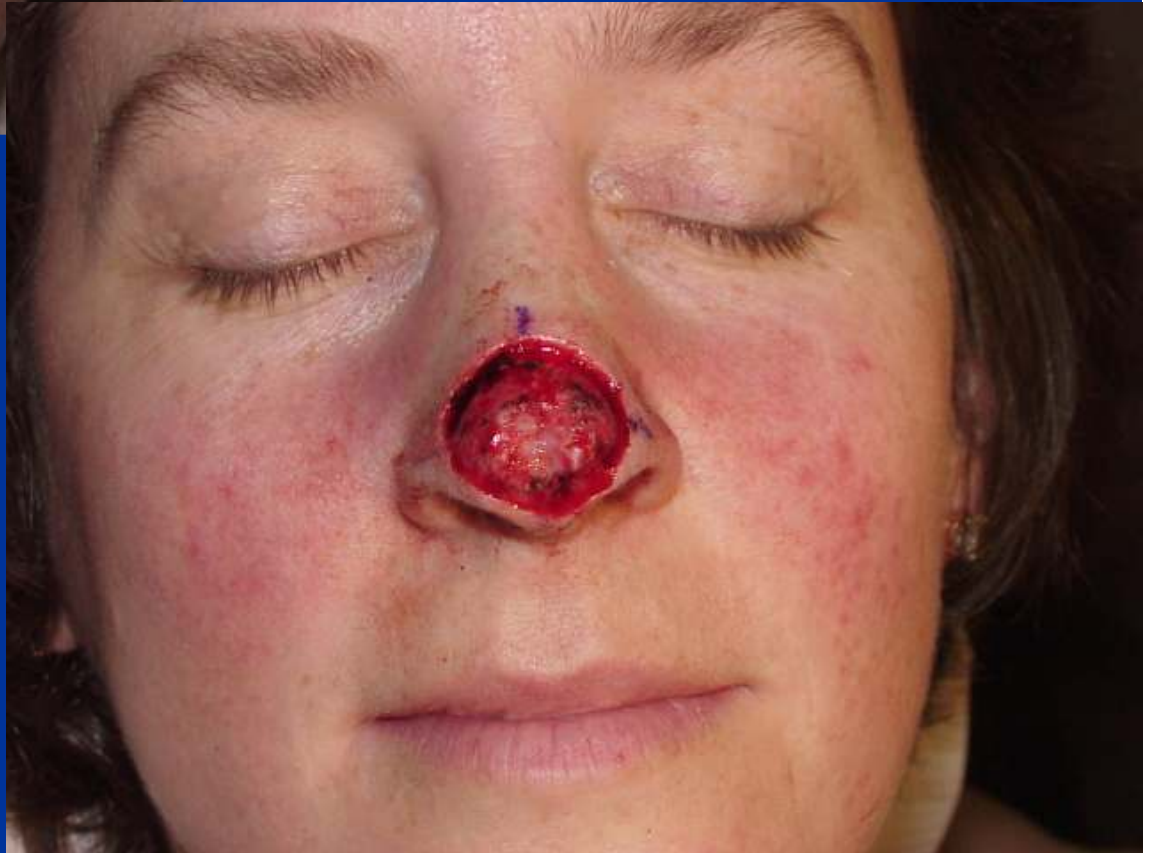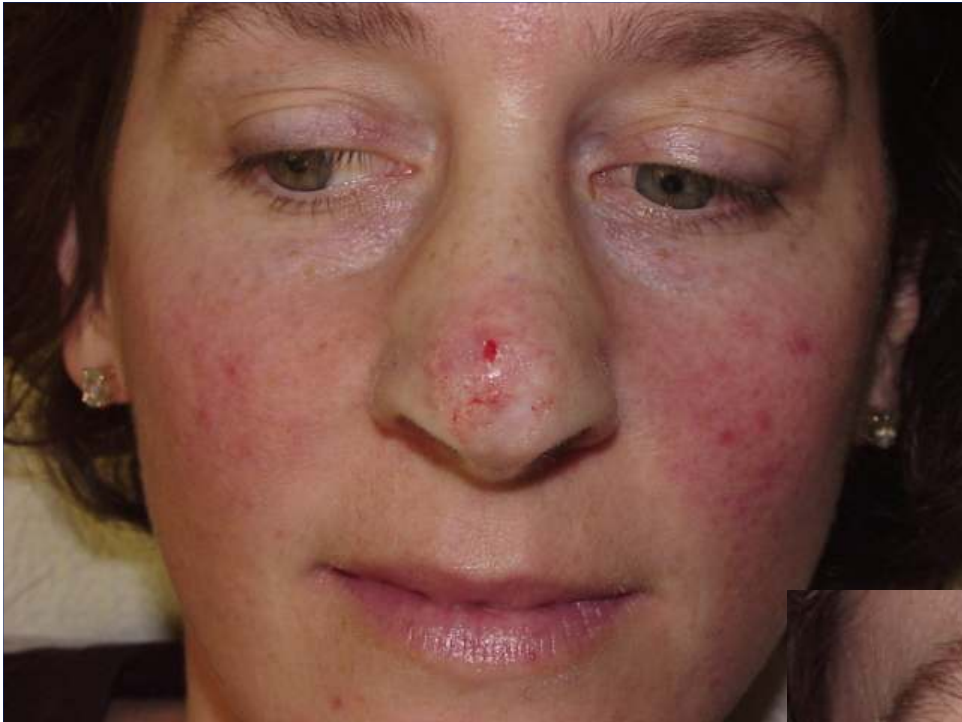Adjunct Clinical Professor of Otolaryngology/Head and Neck Surgery, Stanford University

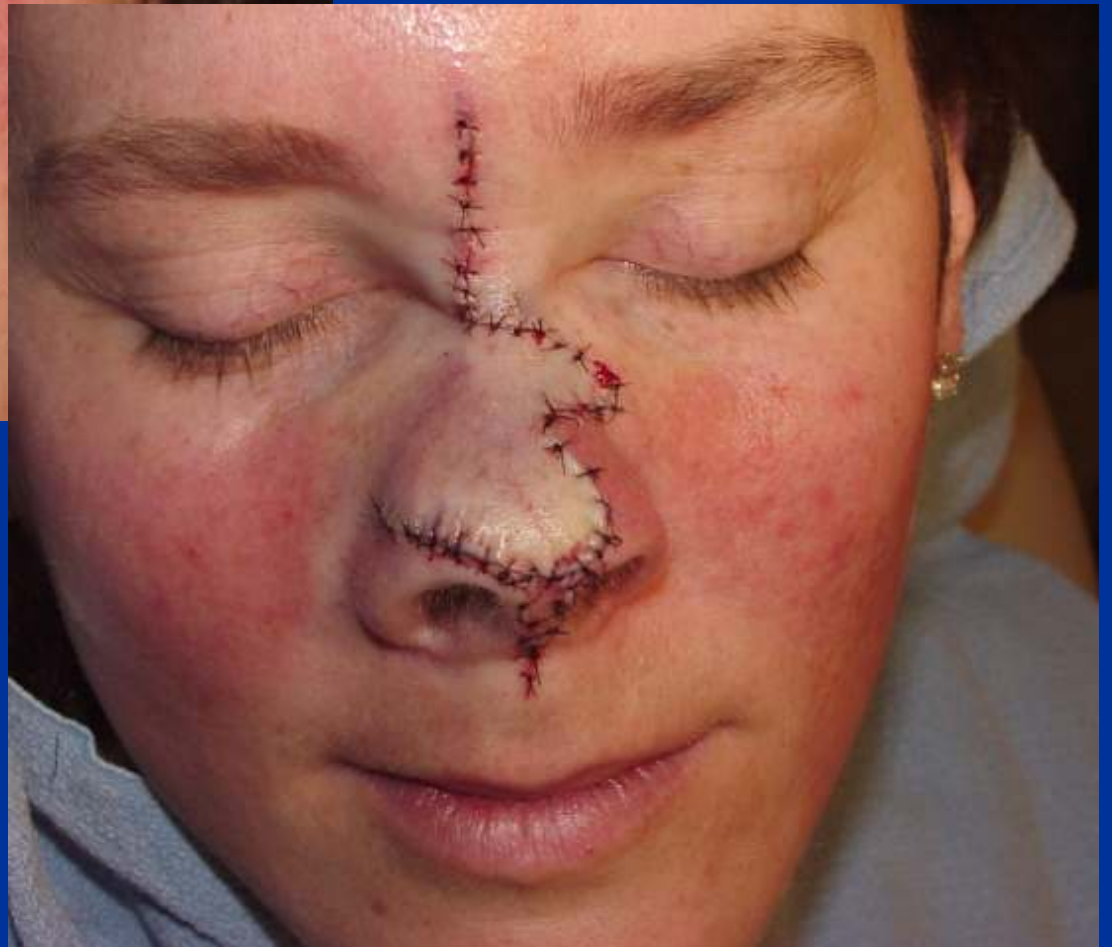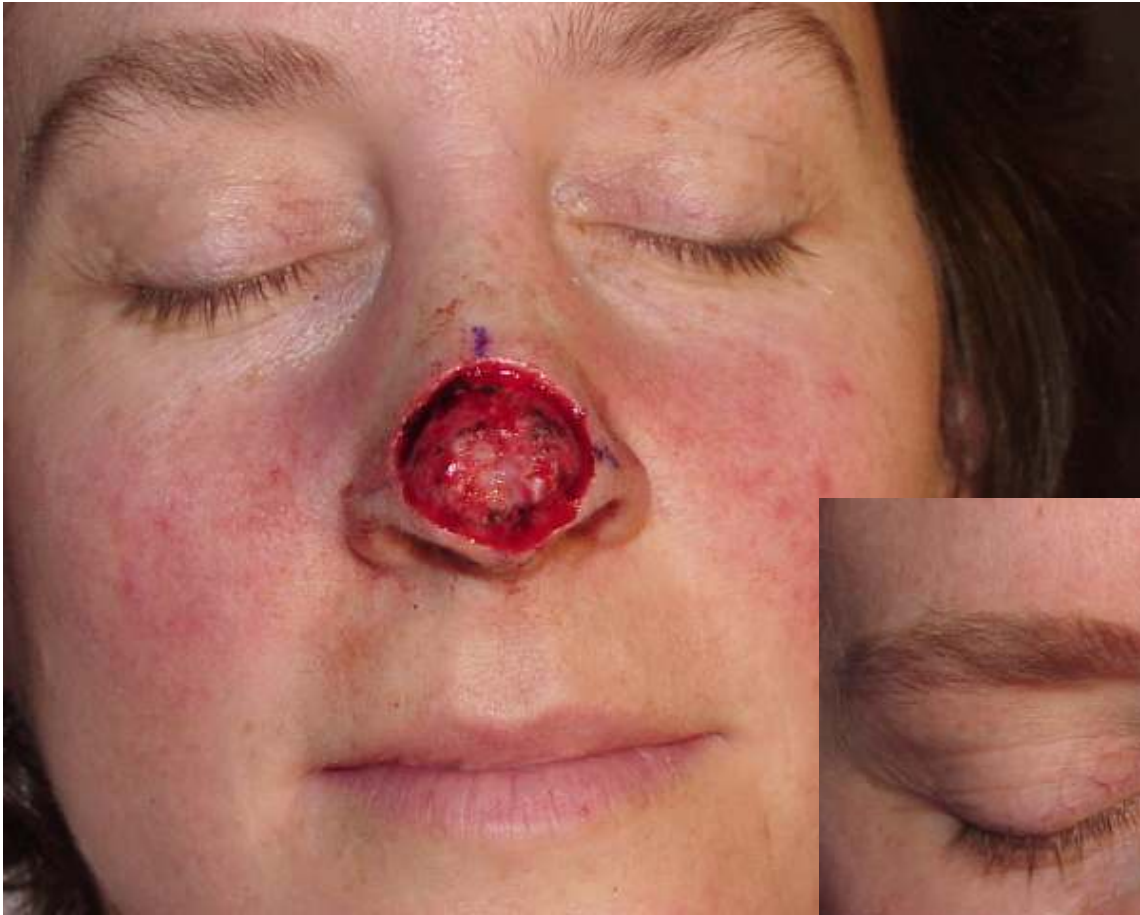Assistant Clinical Professor of Dermatology, University of California, San Francisco

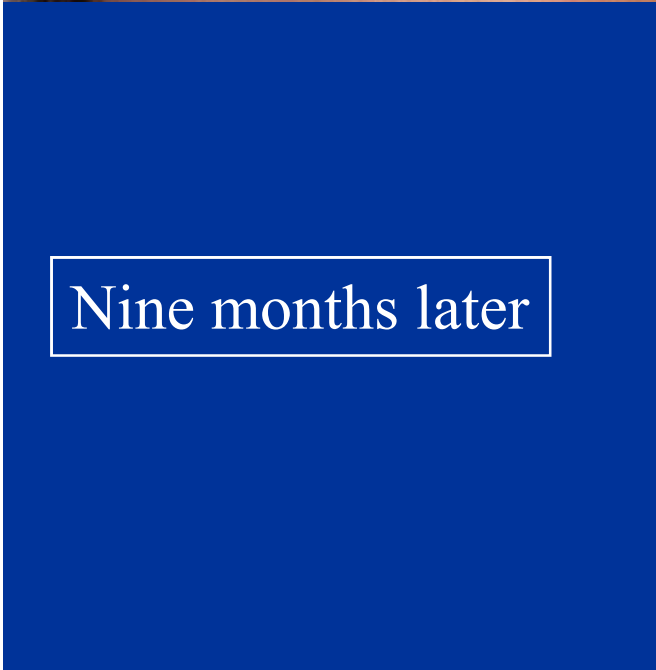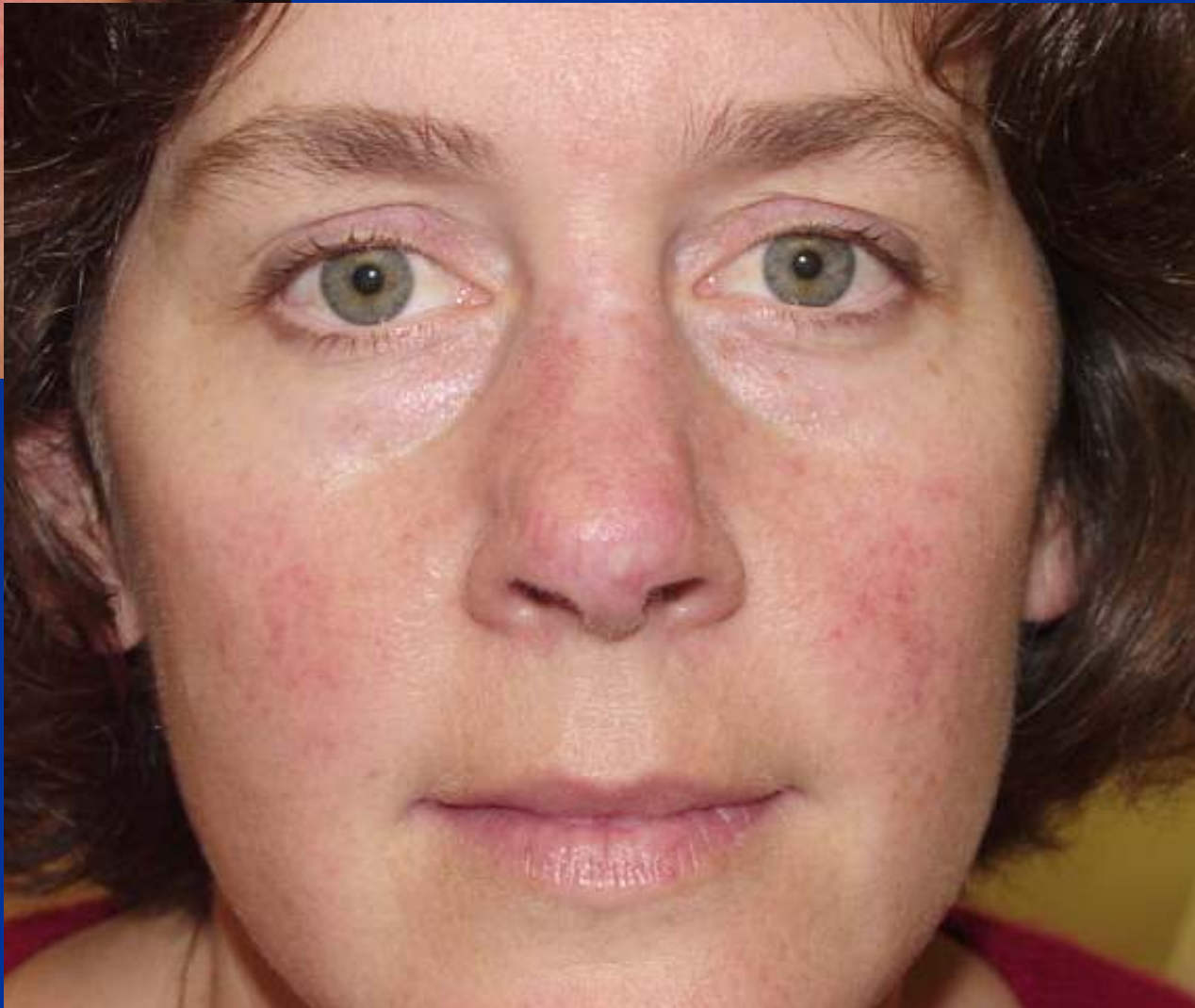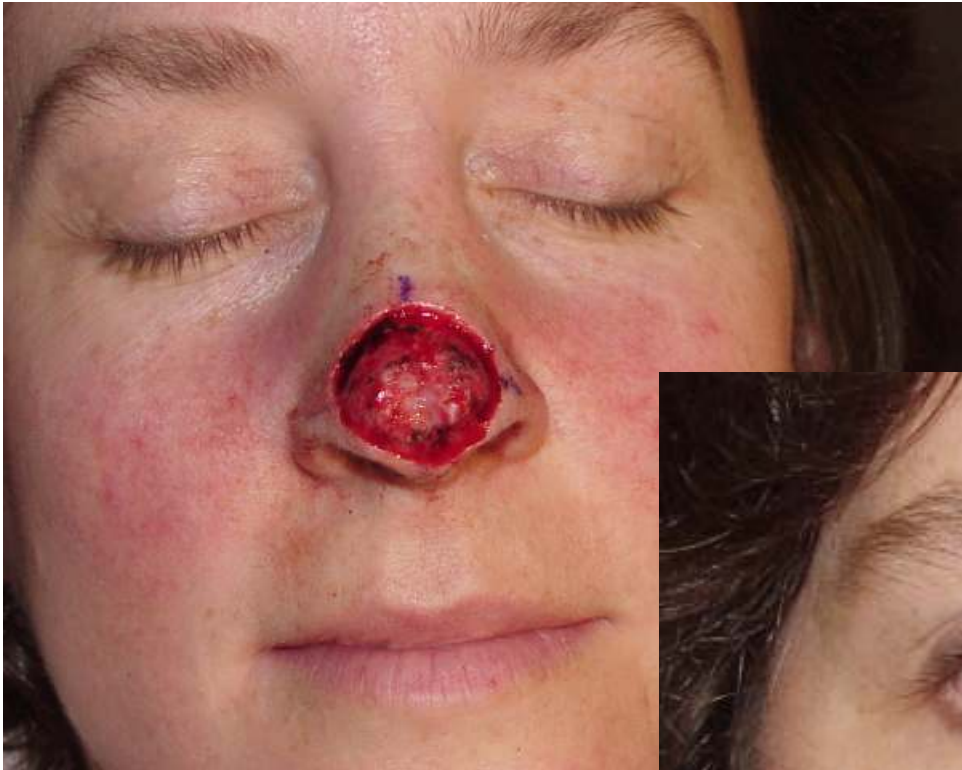Fellowship Director, American College of Mohs Surgery



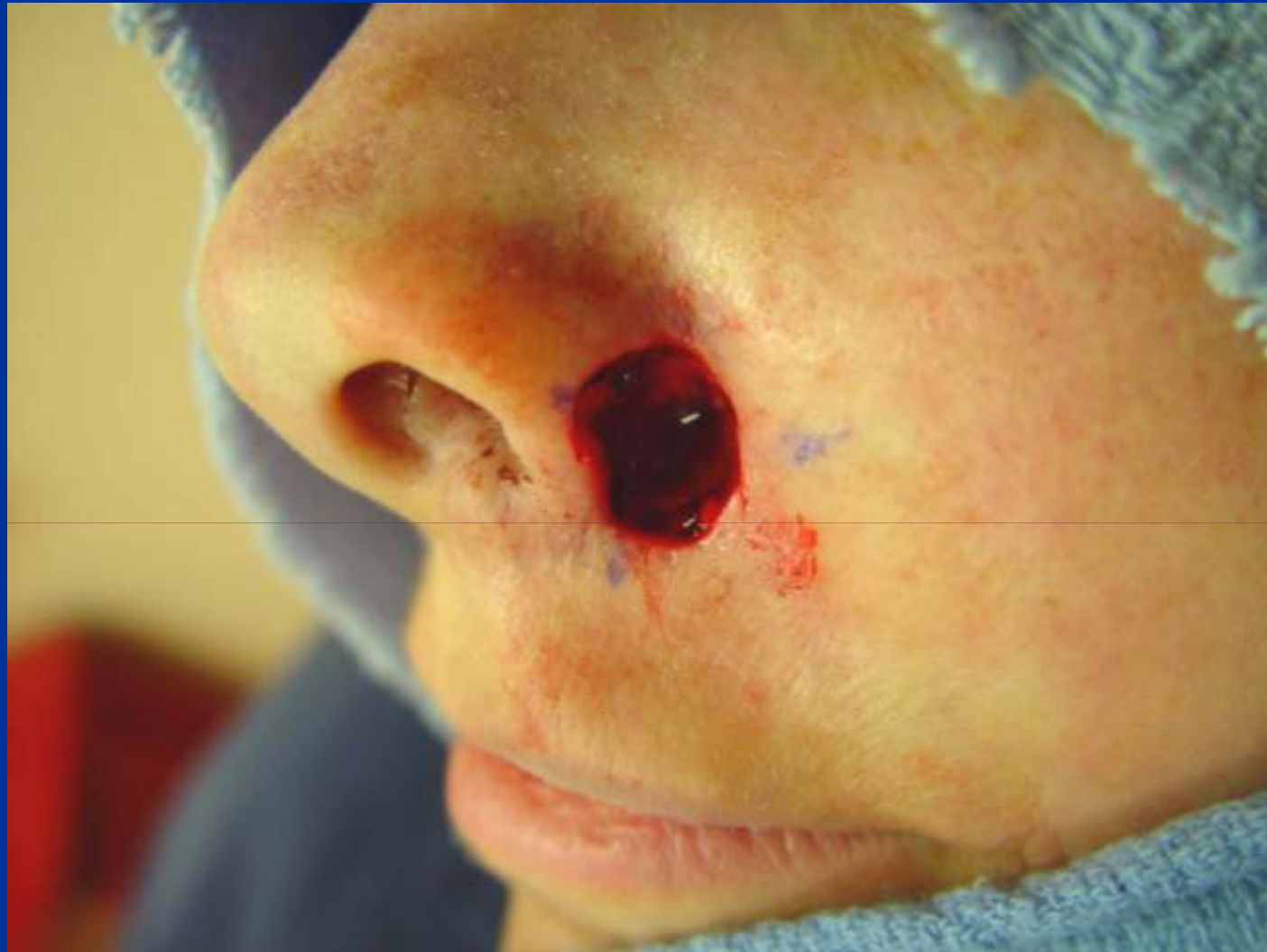Combination Repairs for the Nose







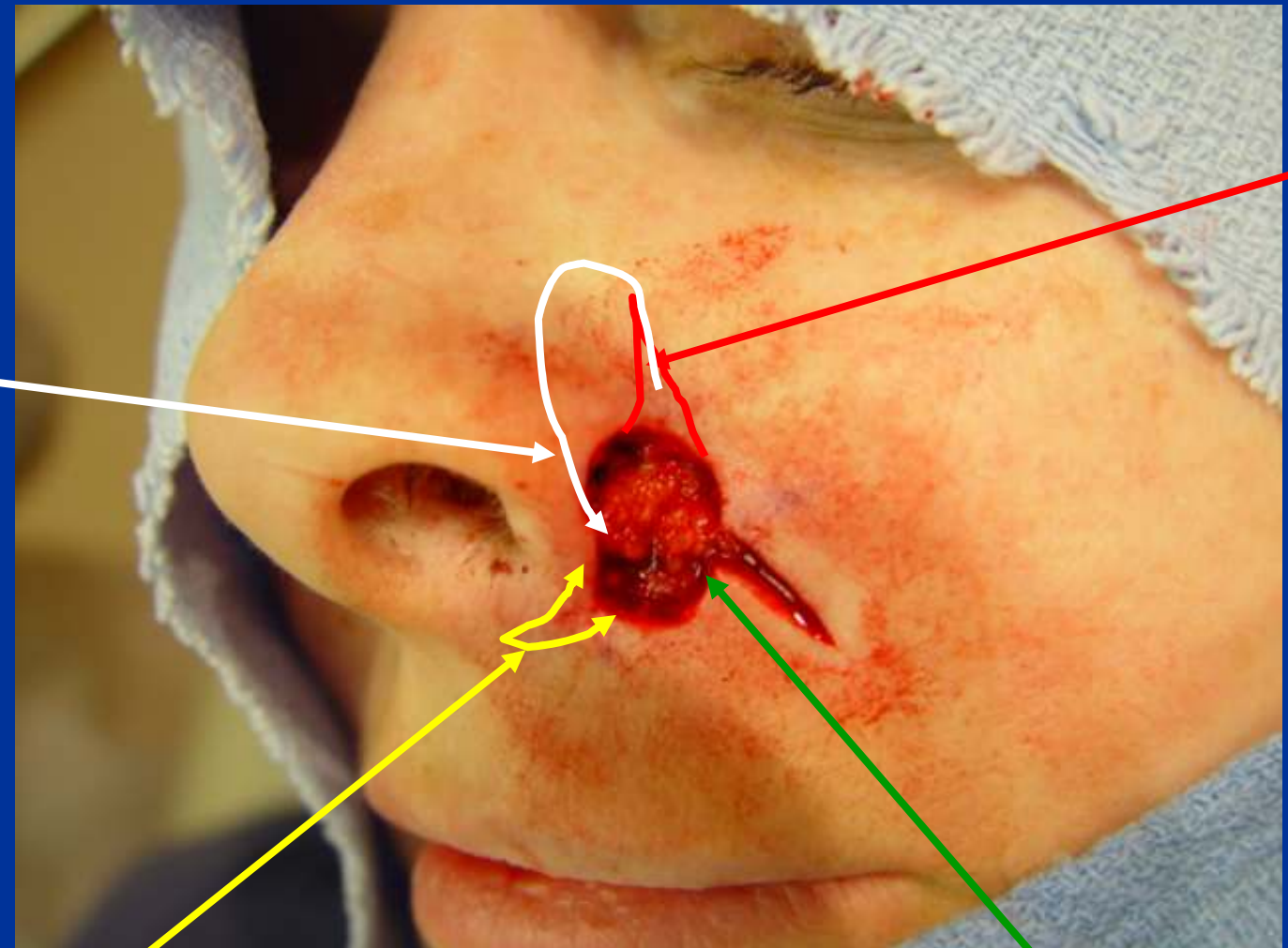
Nine months later



Defect involving ala & nasolabial fold extending to pyriform aperture within mm of bone

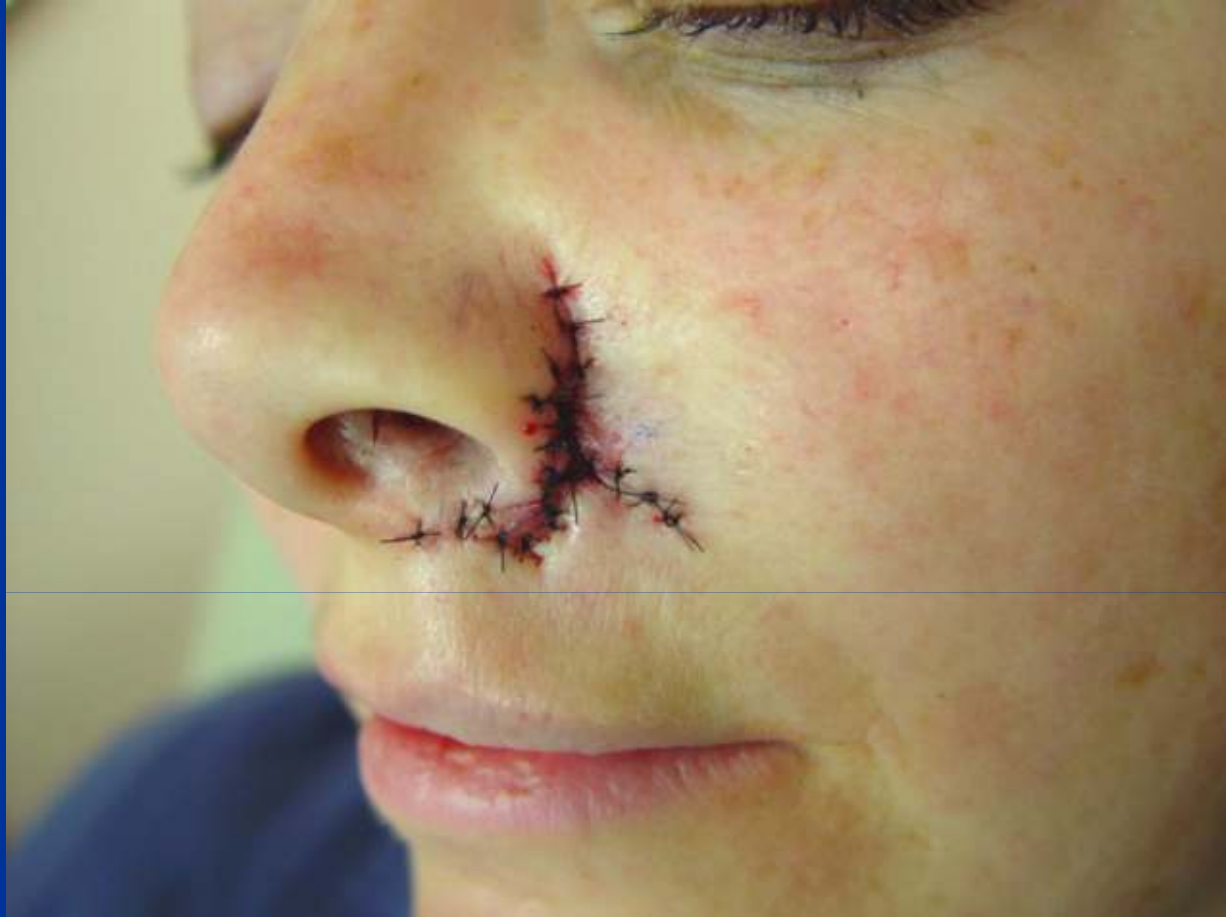FTSG

Superior
Dog
Ear

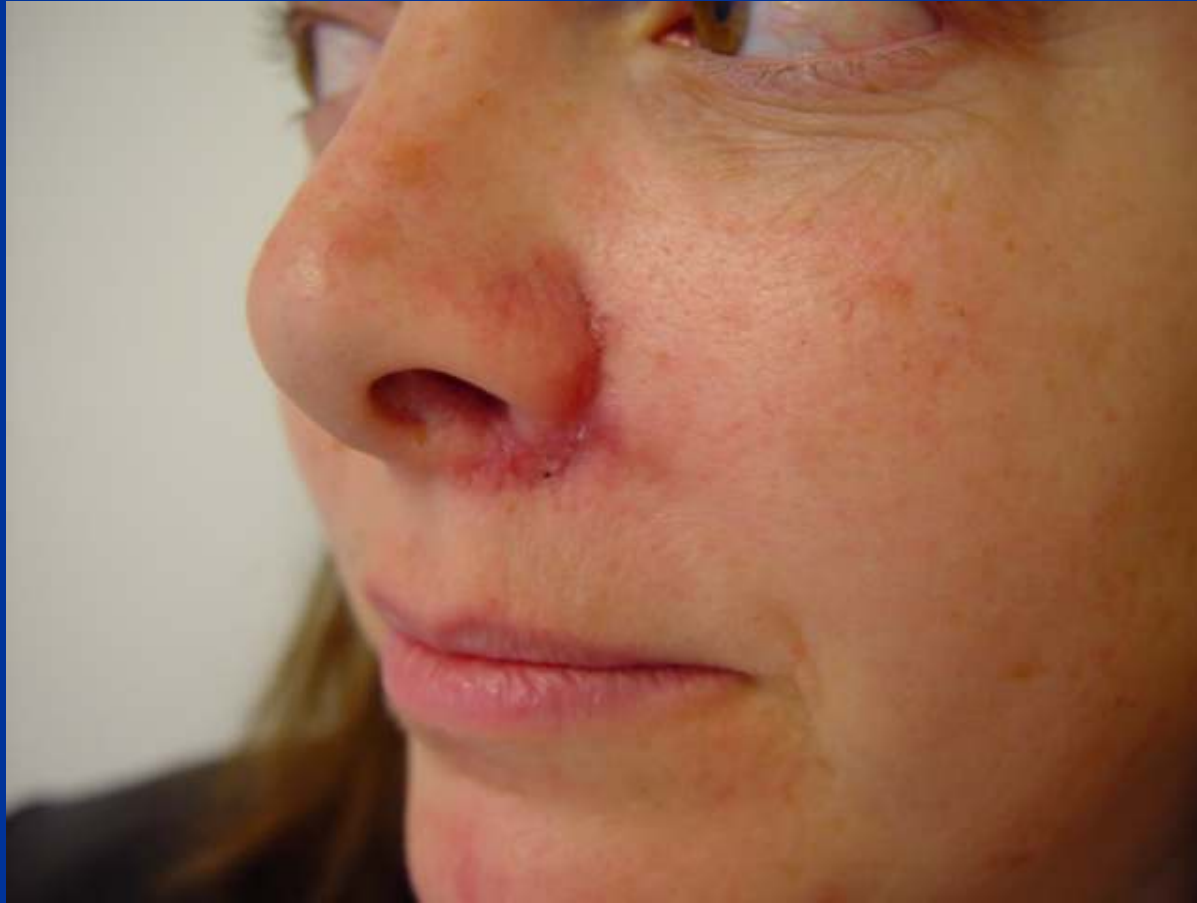

Island pedicle flap

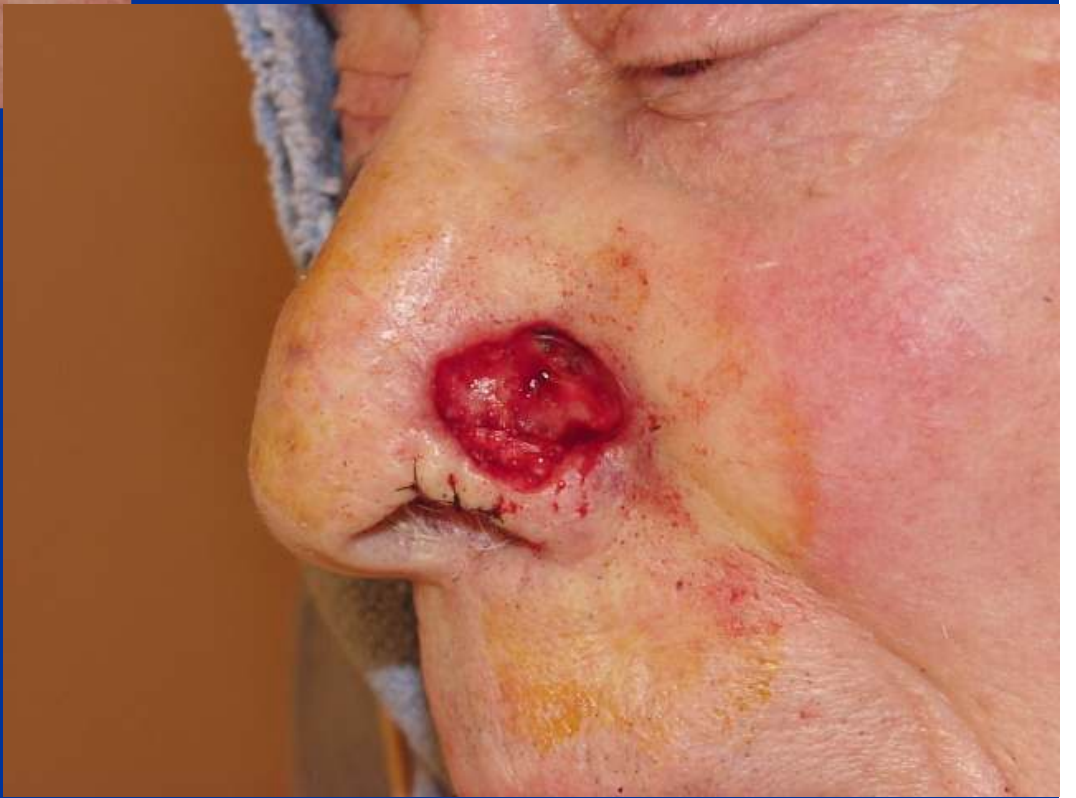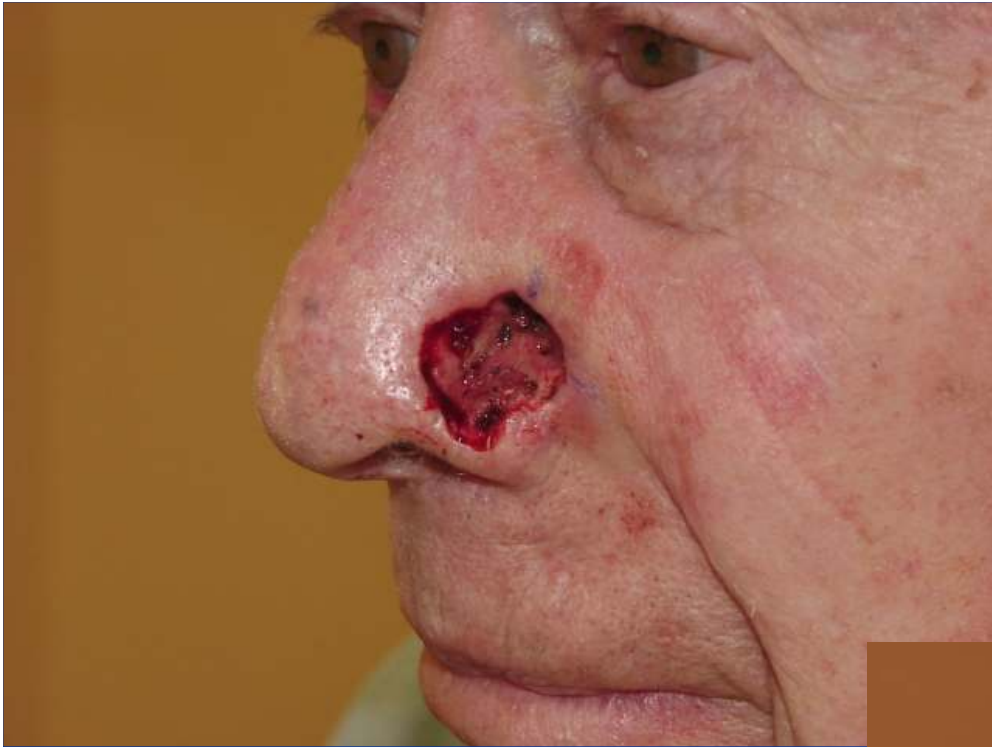Movement of advancement
flap

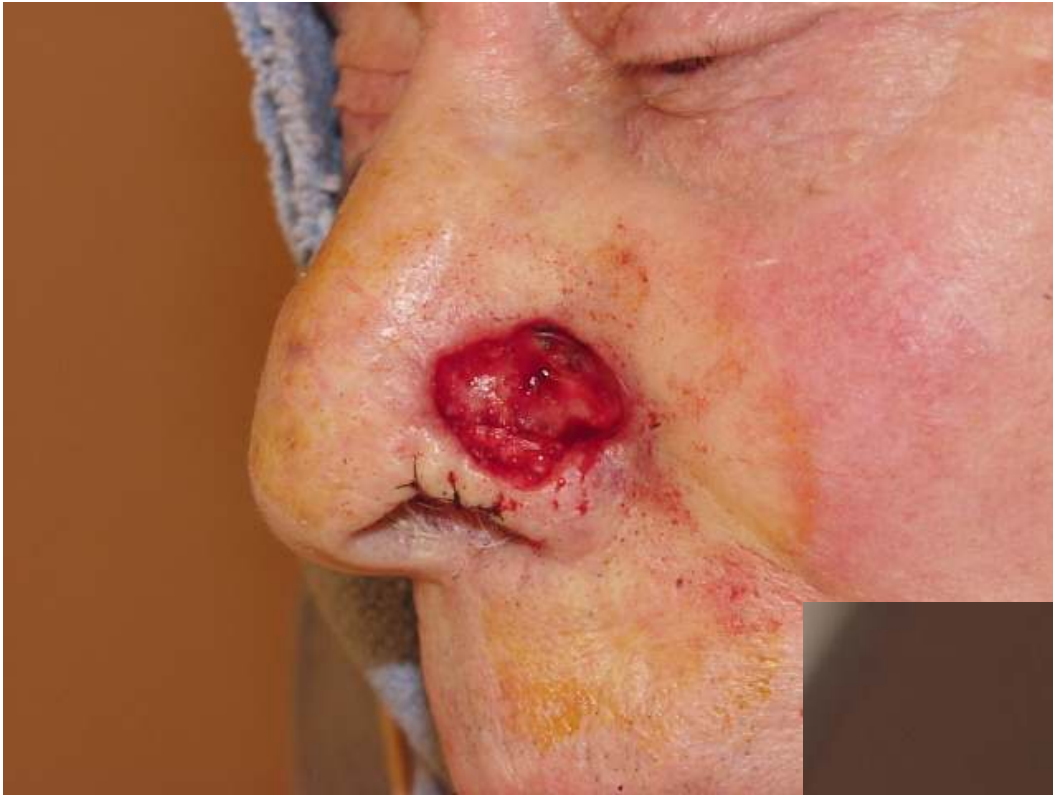

Flap + Flap + Fat Flap + Graft



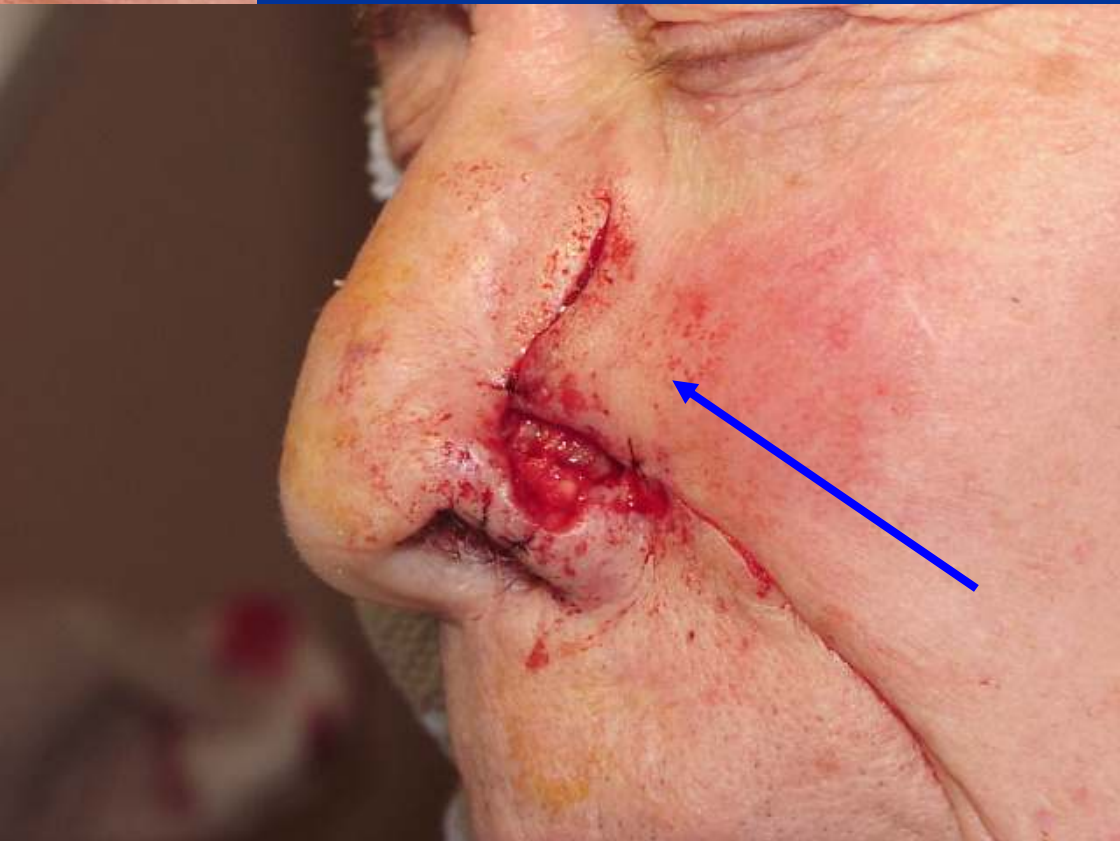Four weeks later with restored nasal sill,
nasolabial fold, and ala

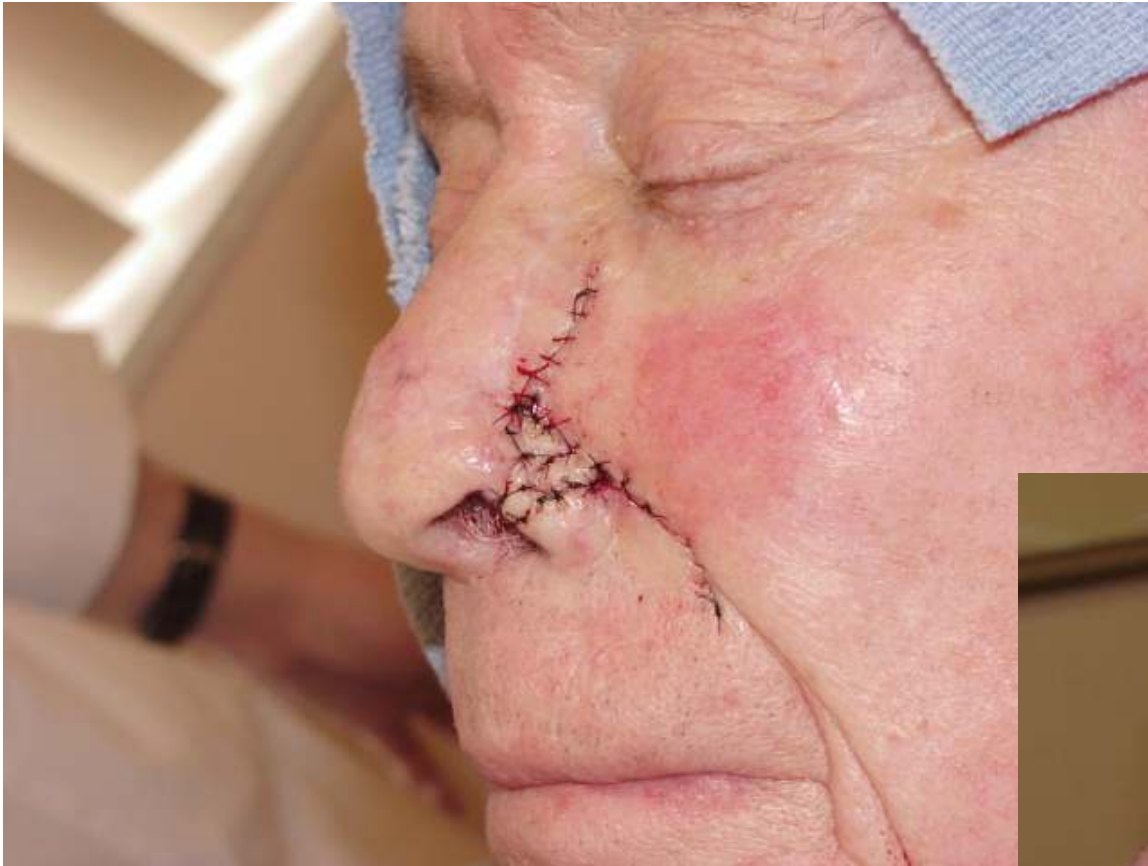



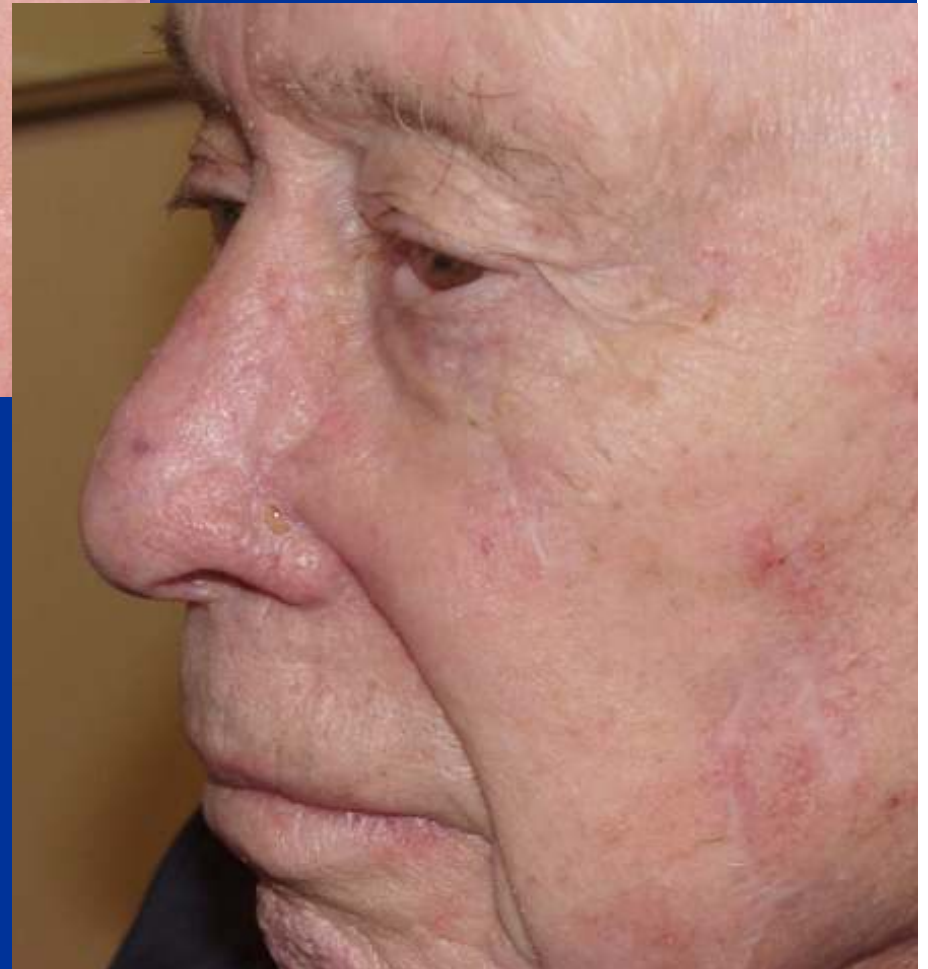**Superior Dog Ear
Serves as Full
Thickness Skin Graft**

**Advancement flap along
nasolabial crease**



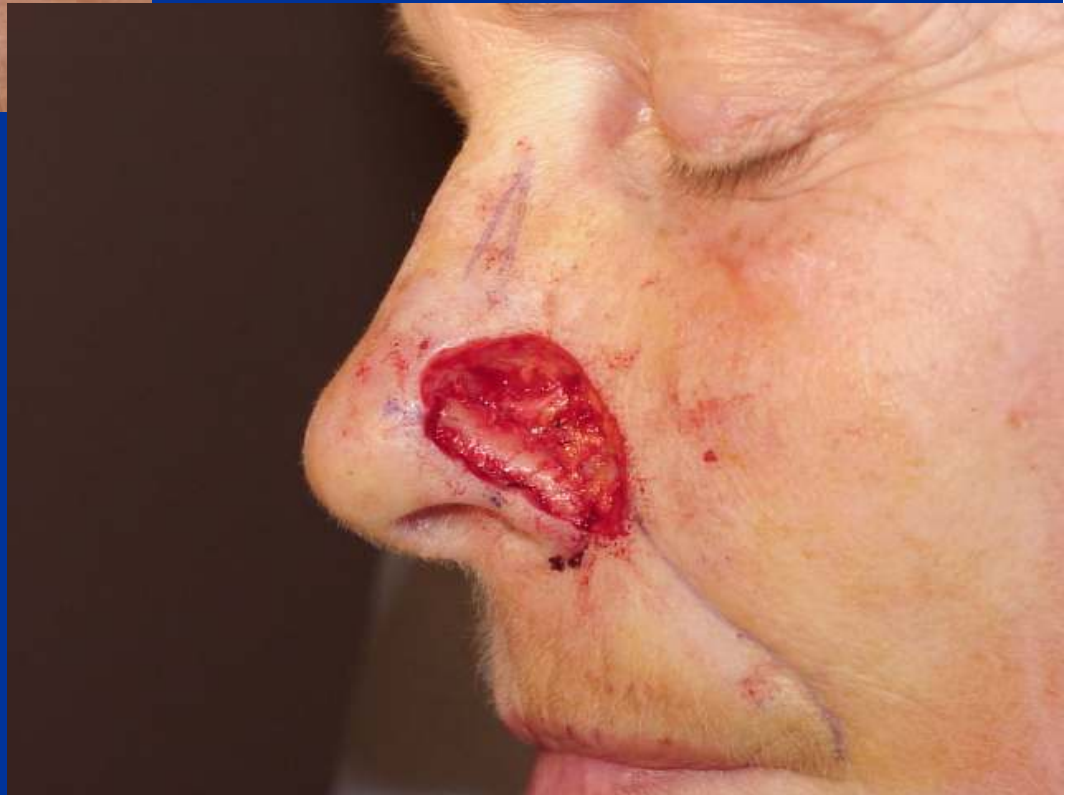
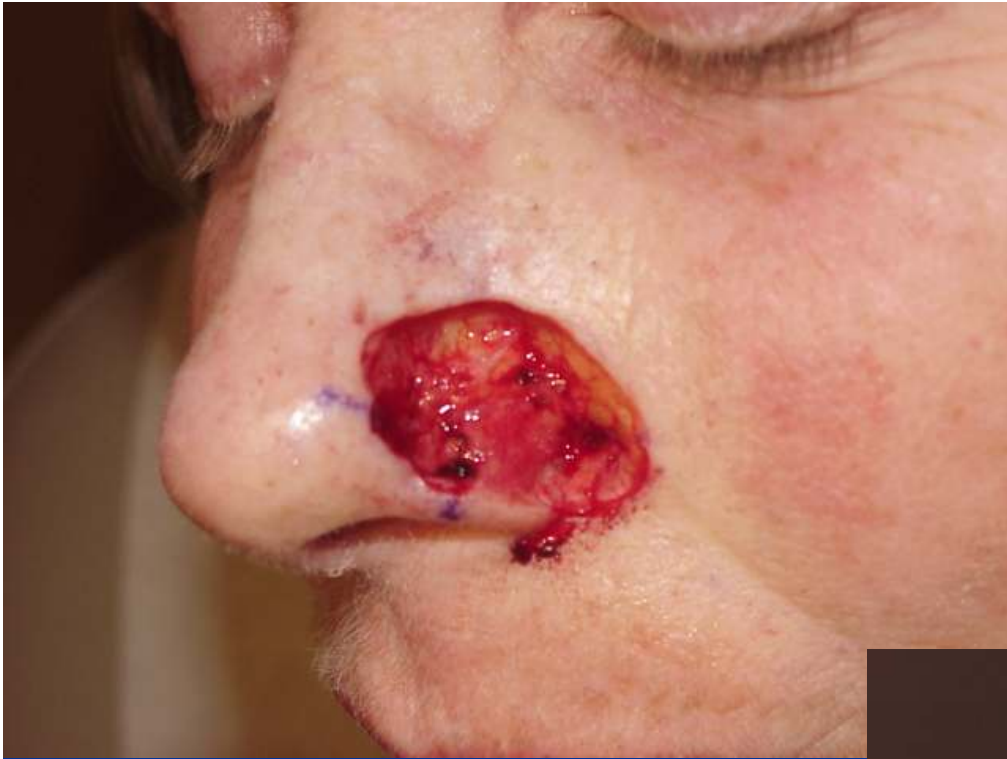
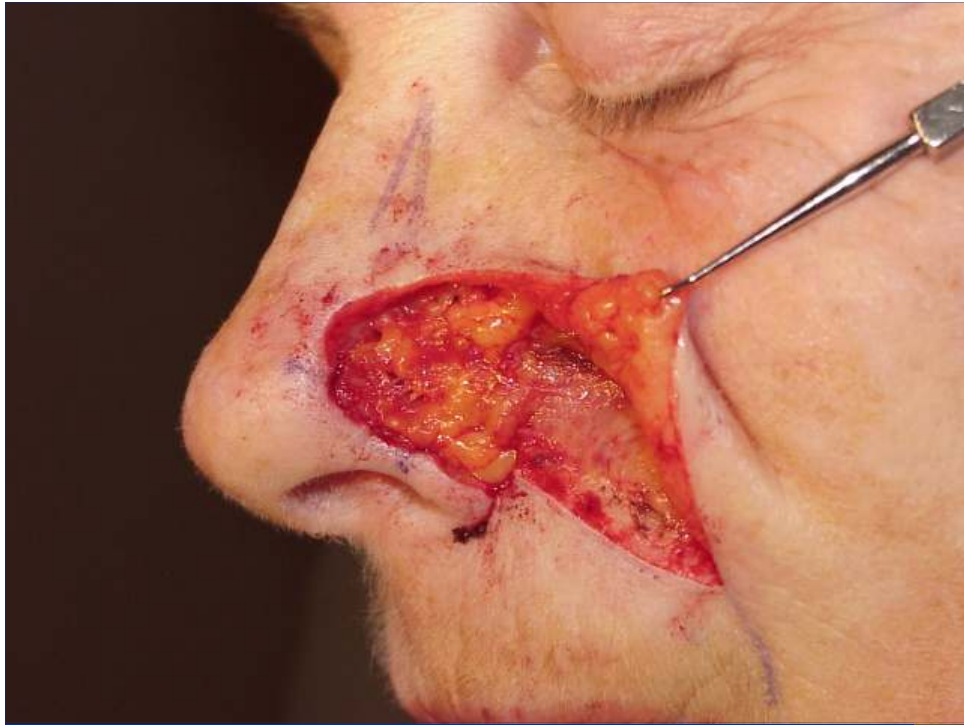
Full thickness skin graft
from the superior dog
ear



One Month Later

Defect extends
through alar wall

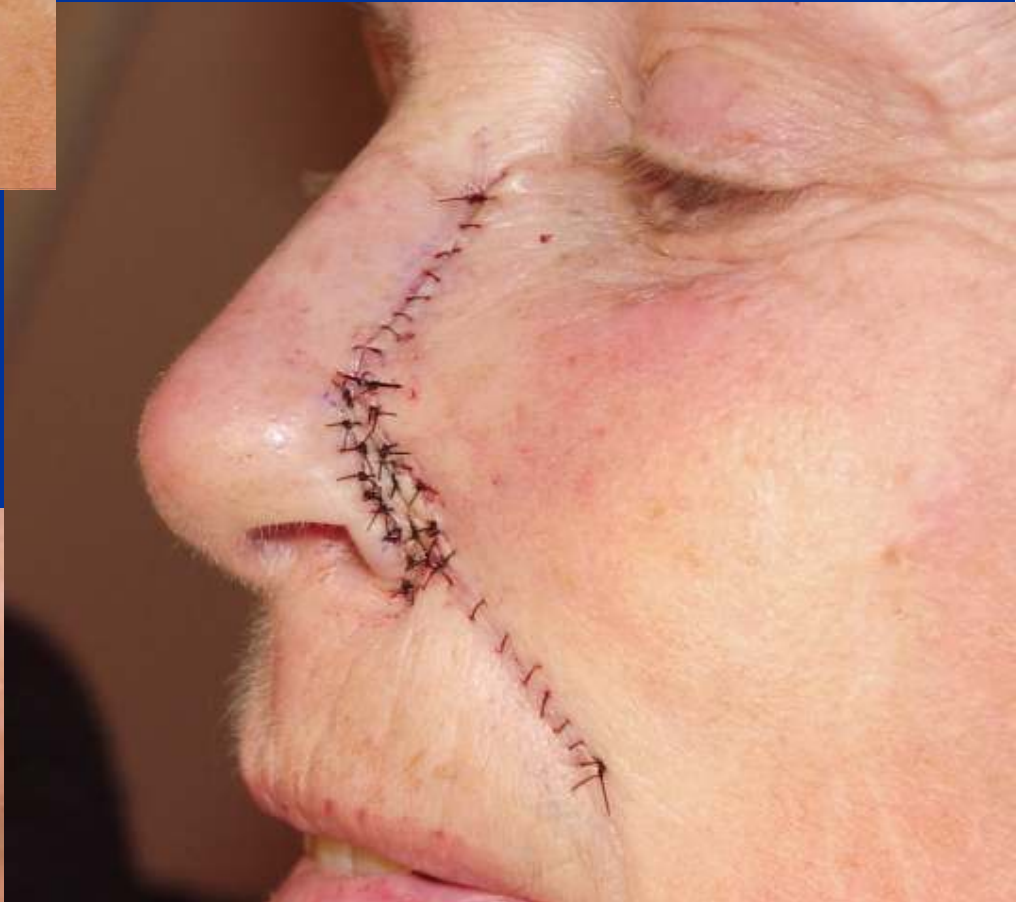
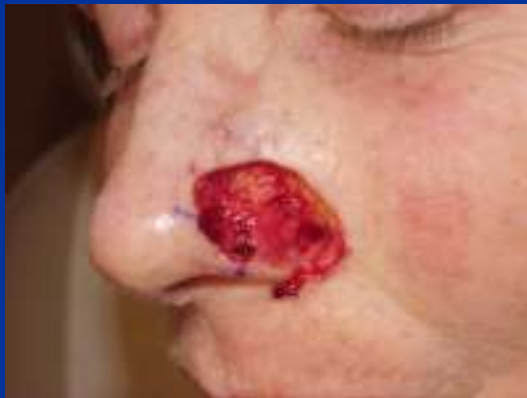


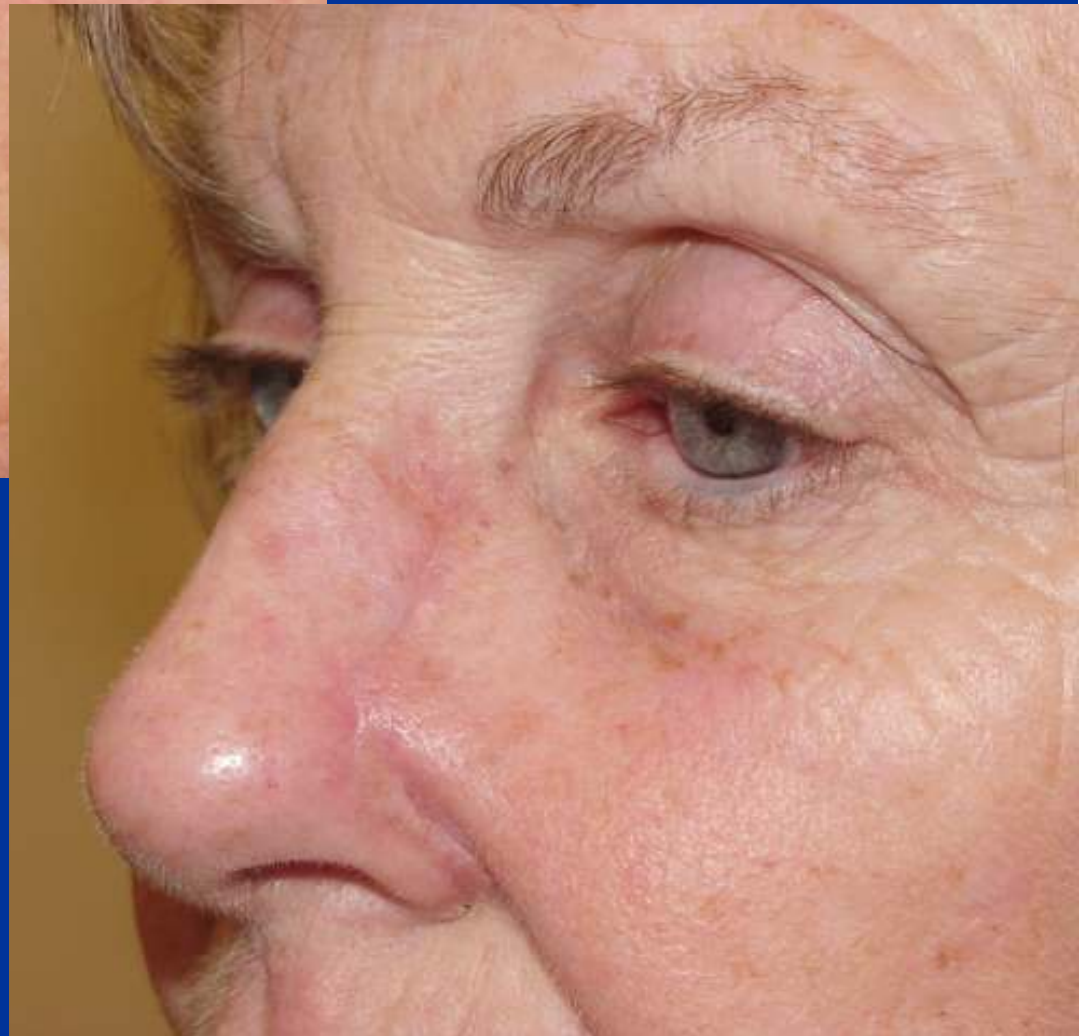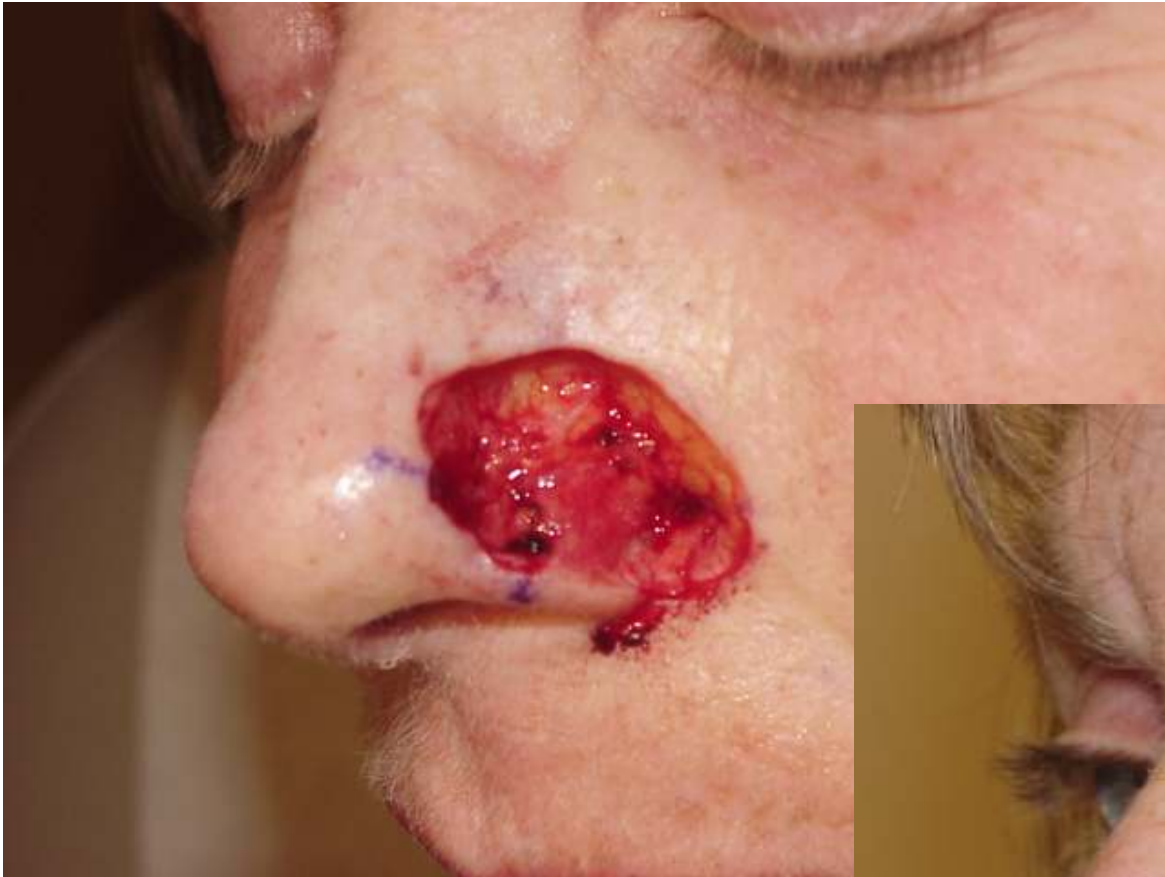Advancement flap along the nasolabial fold is advanced to nasal sidewall

A superior dog ear forms

Alar defect is repaired with graft from superior dog ear.





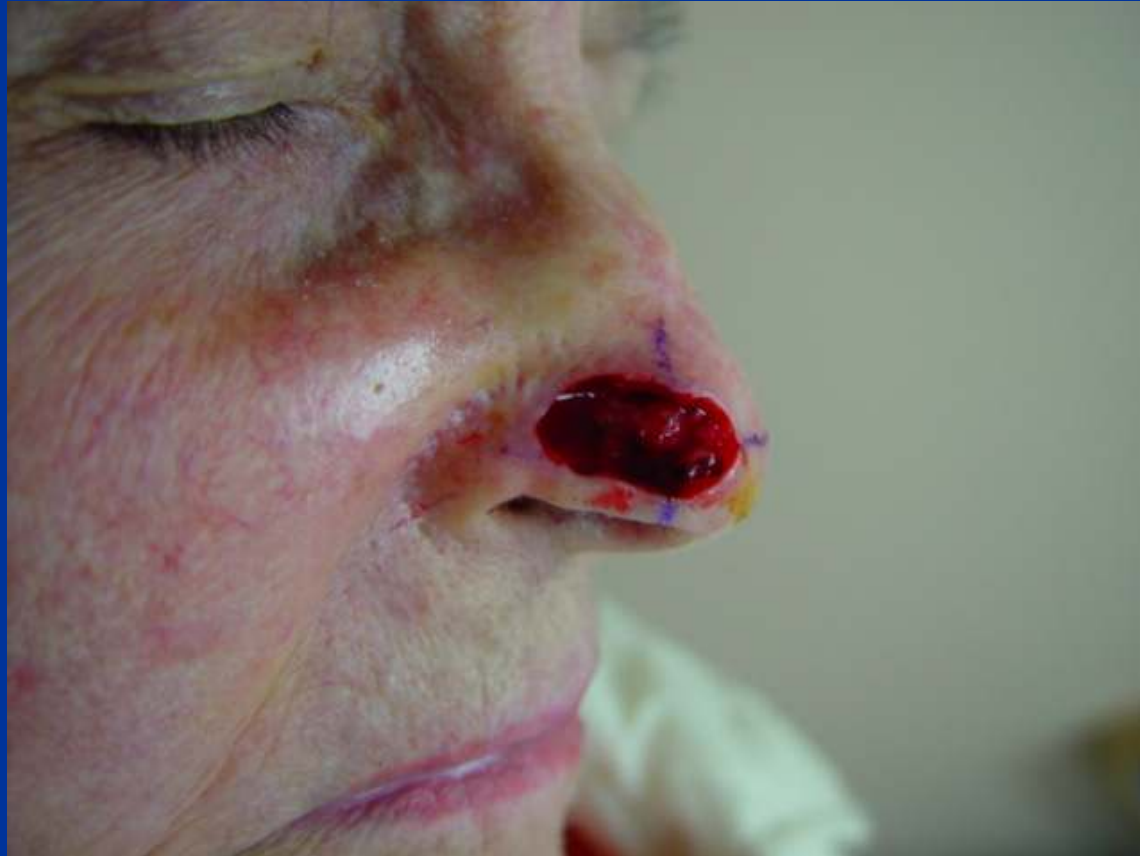Three months later

Two-Stage Repairs

Greg S. Morganroth, MD

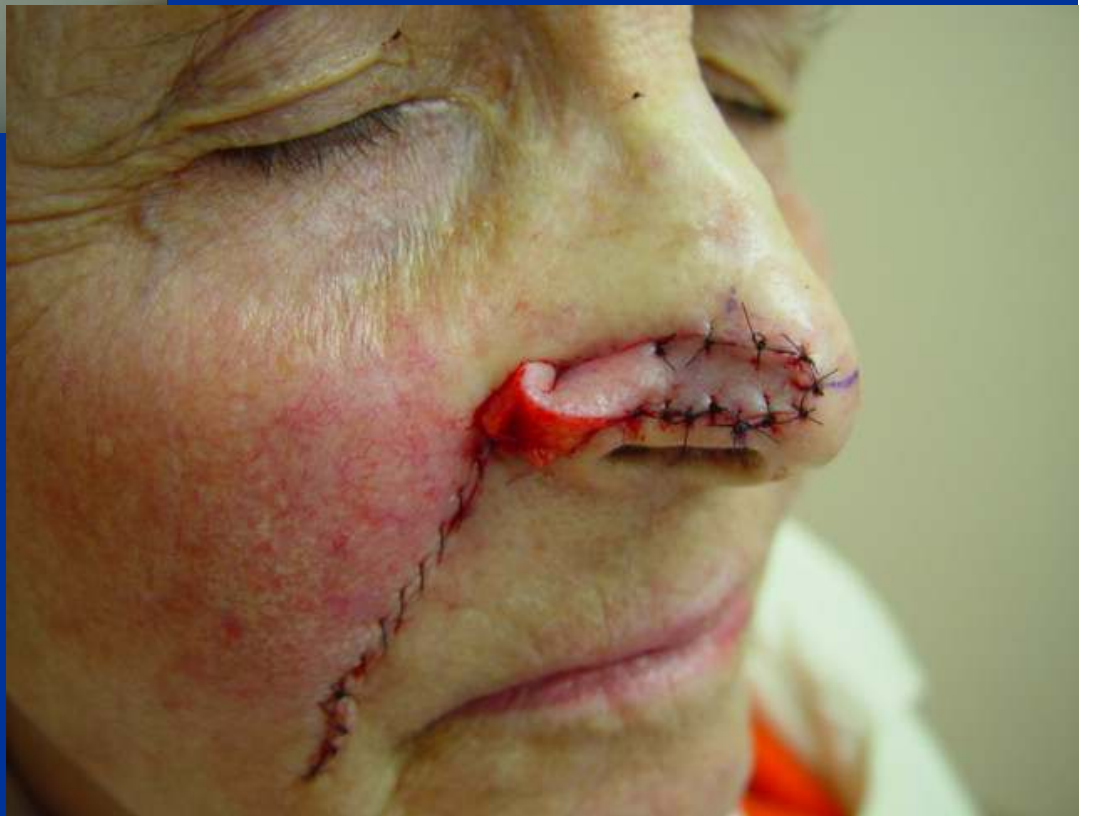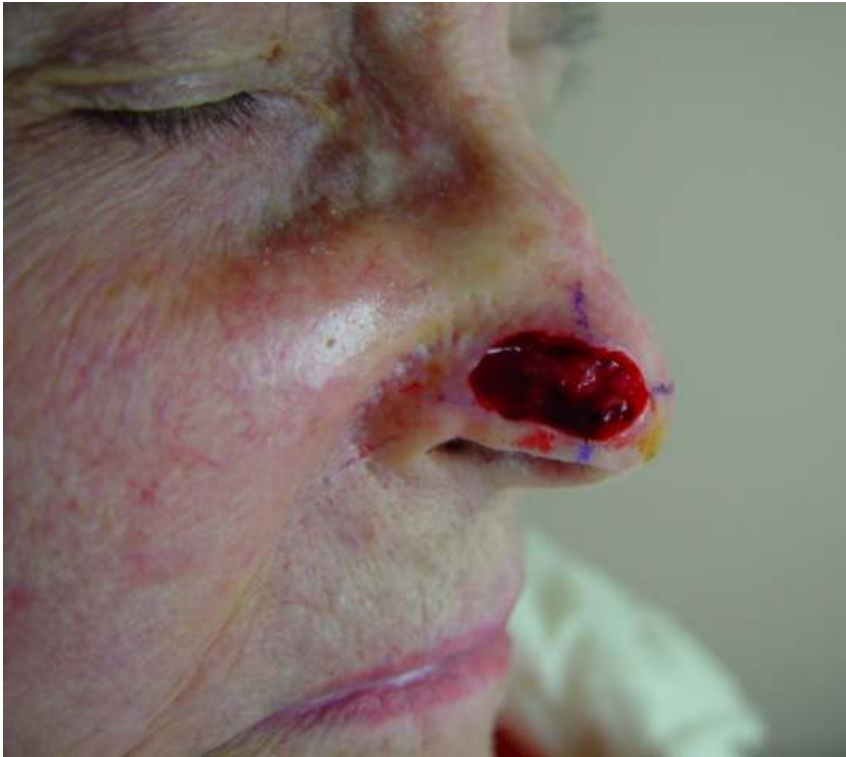The Nasolabial Pedicle Flap

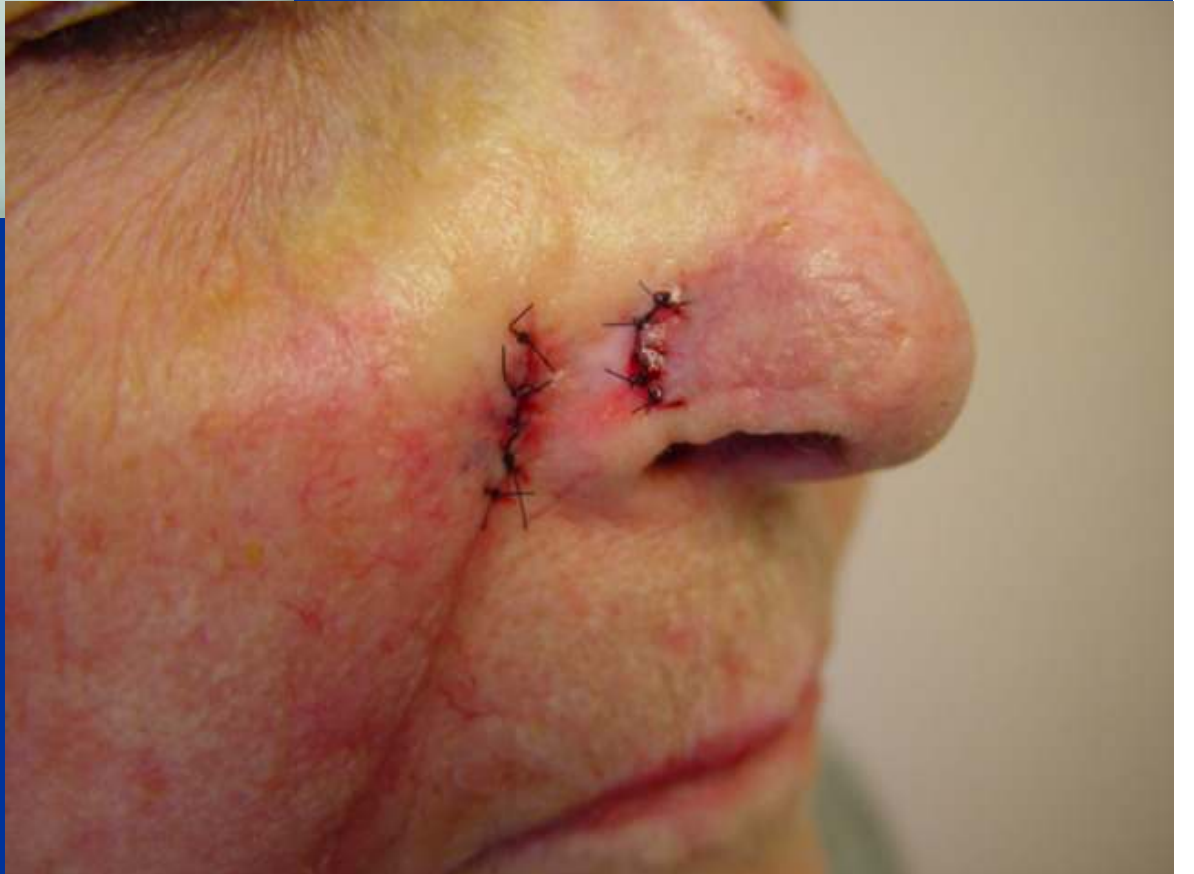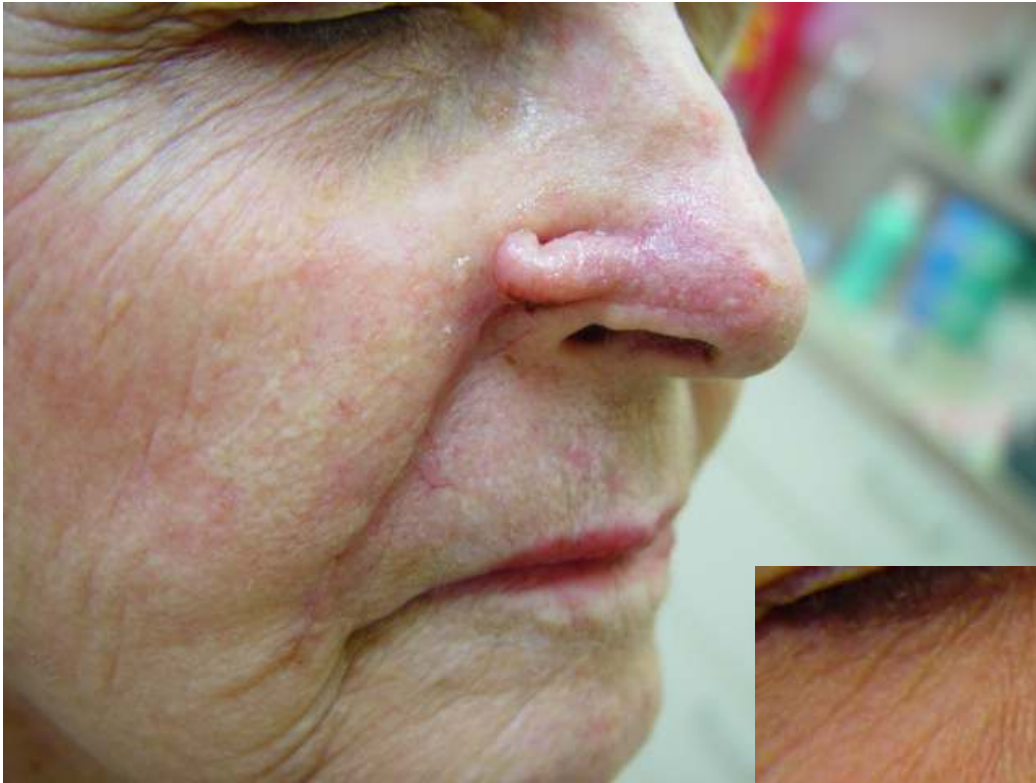Greg S. Morganroth, MD



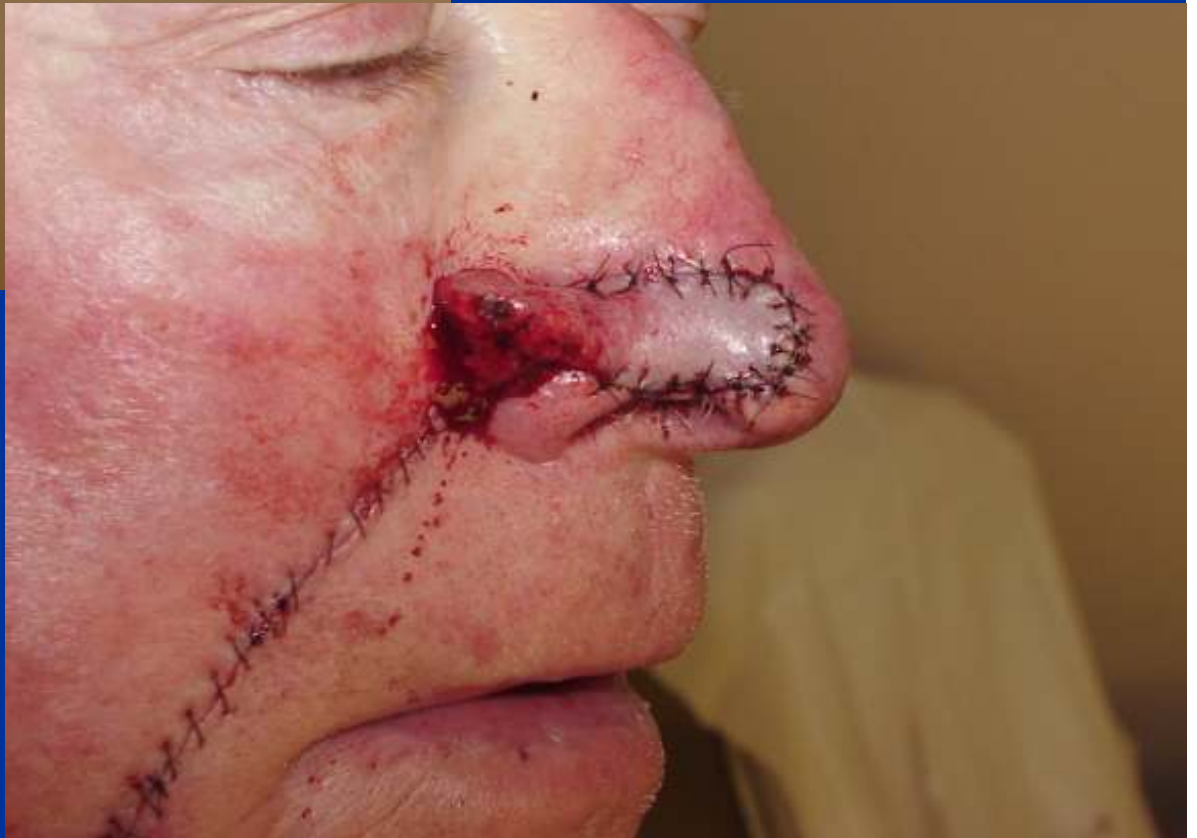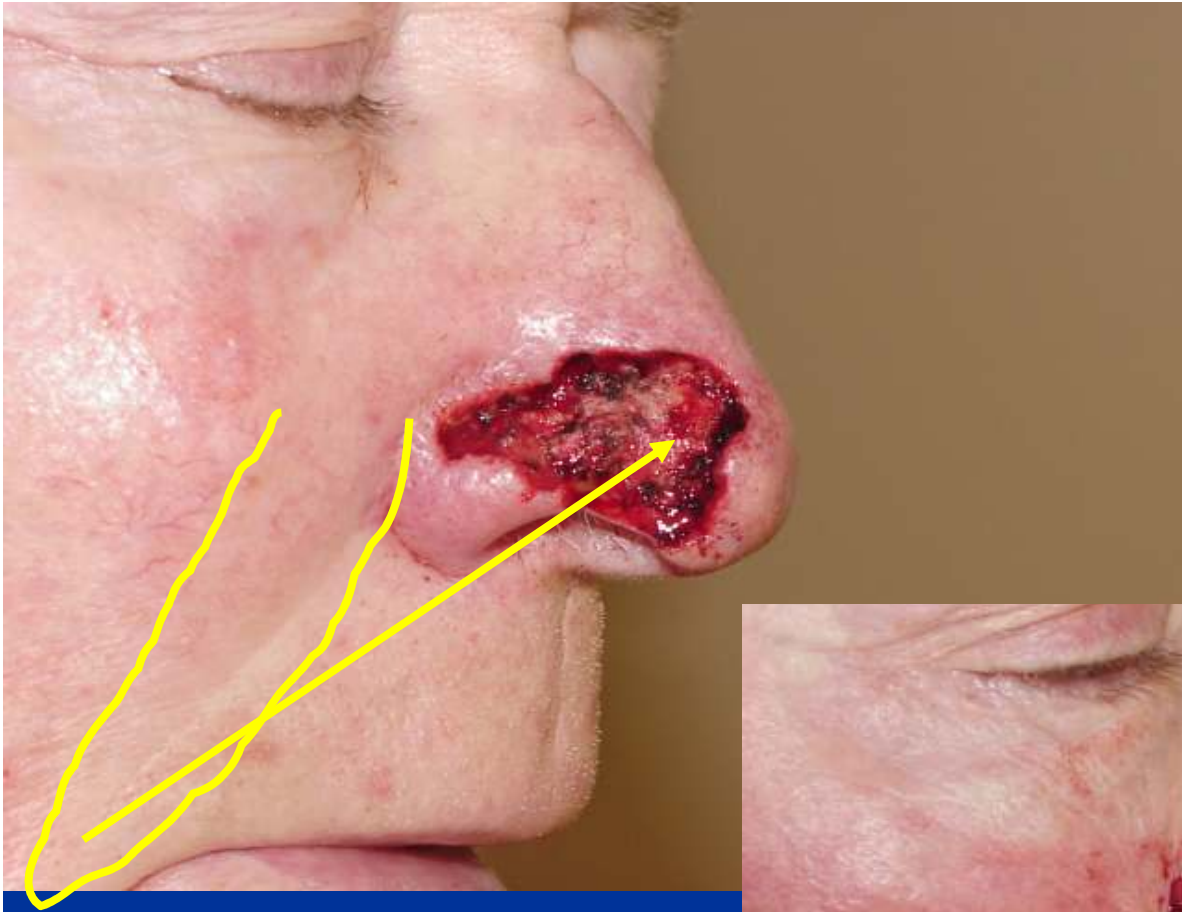Options:

Local flap, forehead flap or pedicle flap, full thickness skin graft

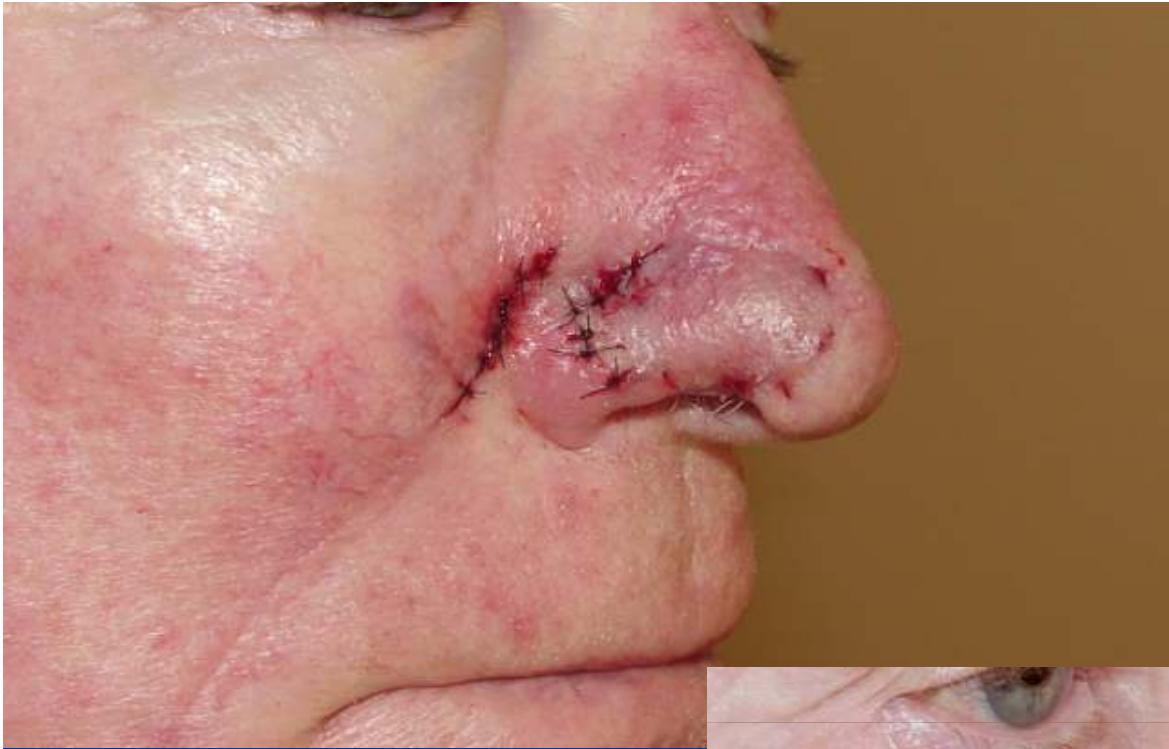



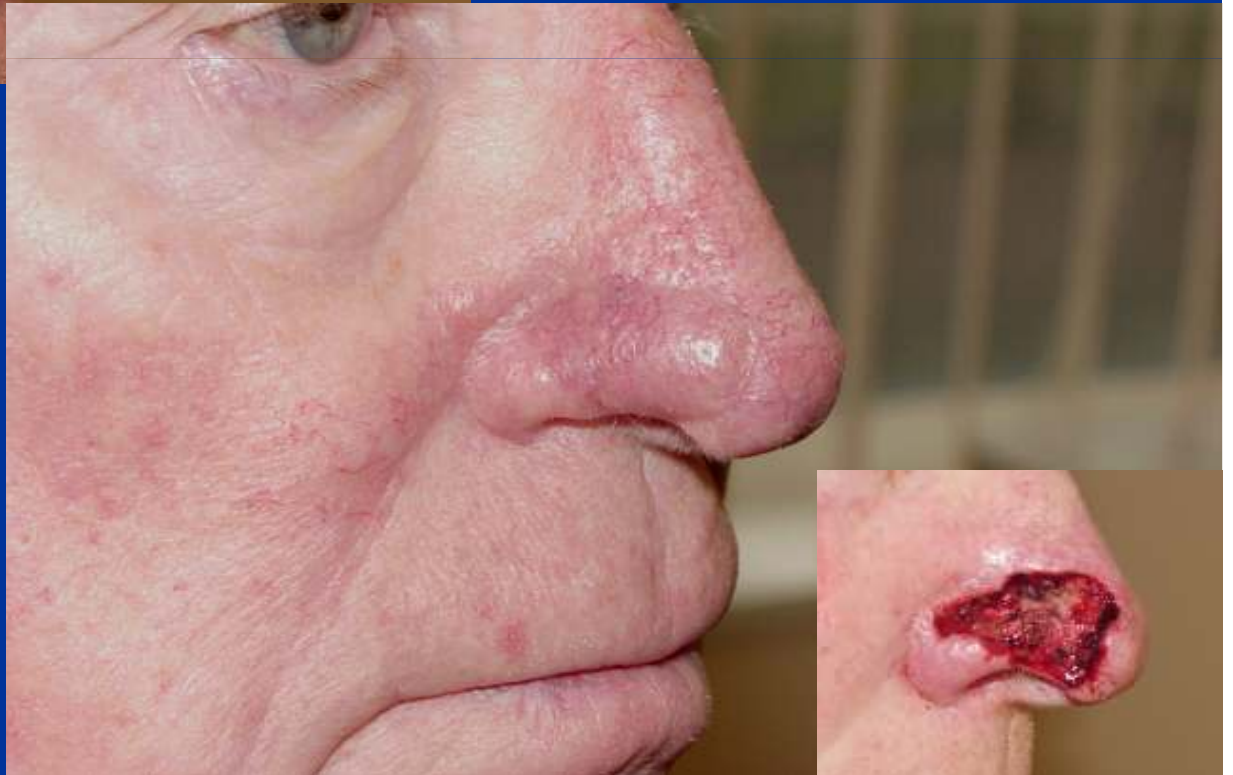Three weeks later

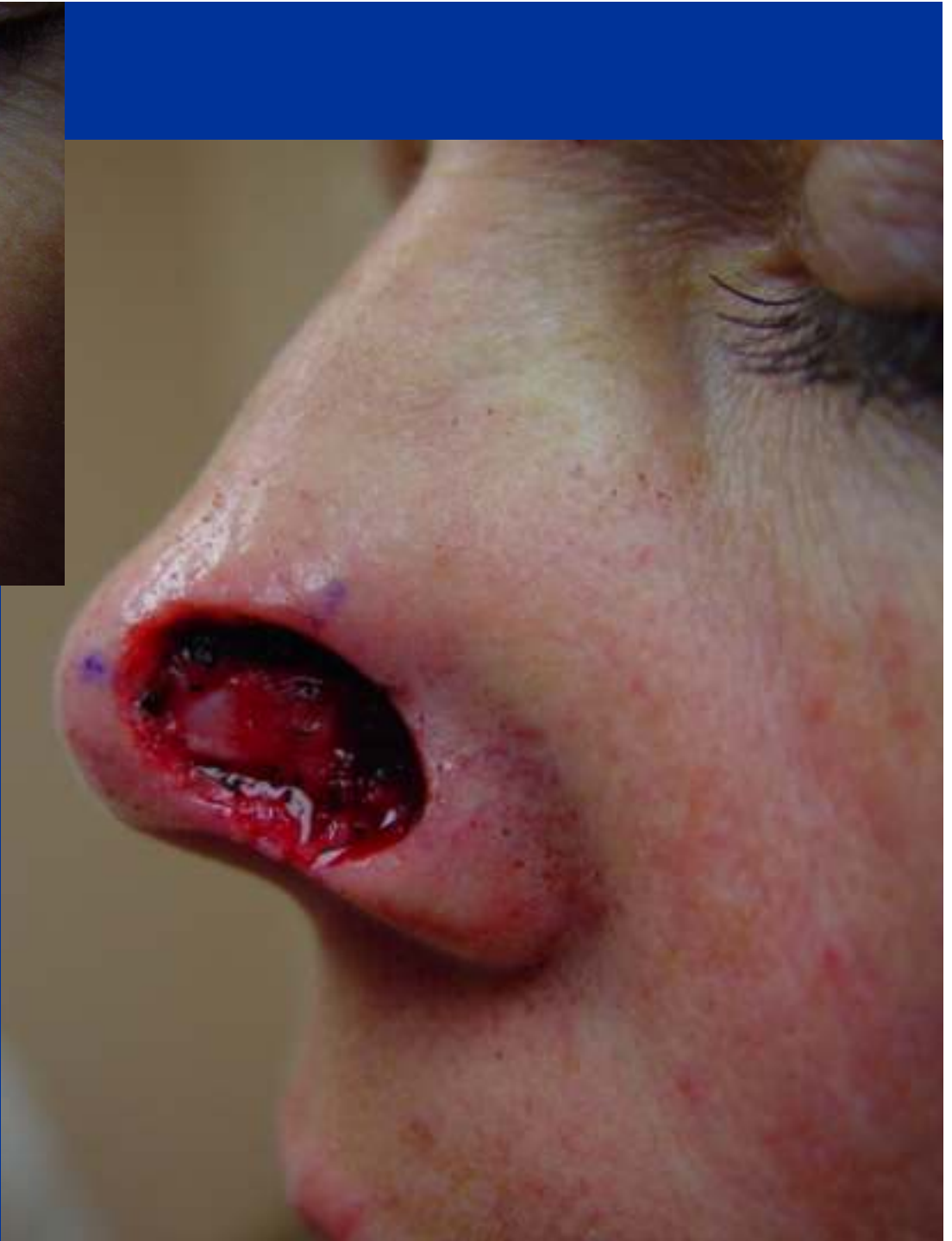
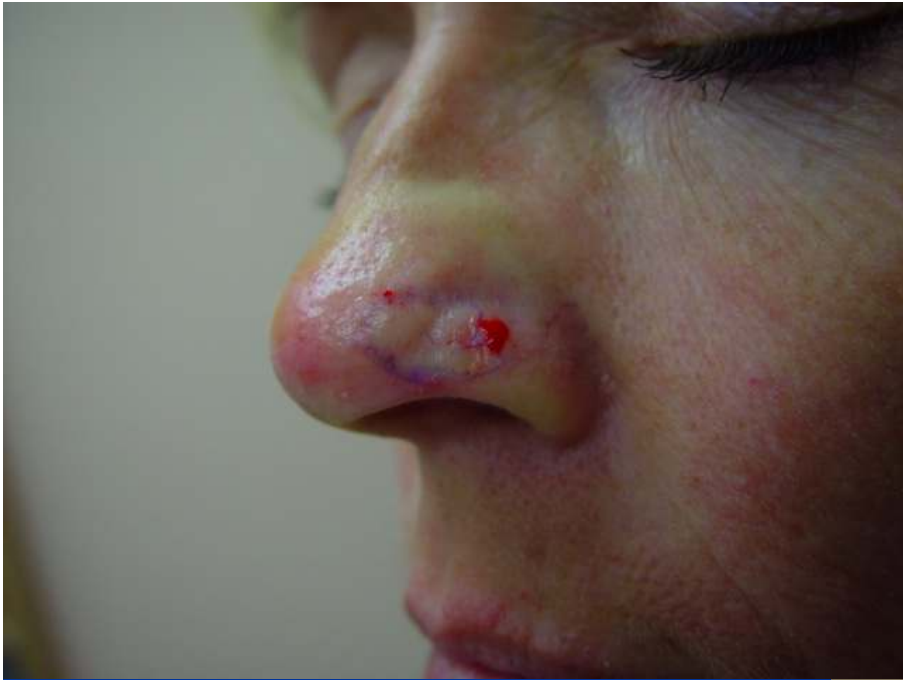
Three weeks later



One month later





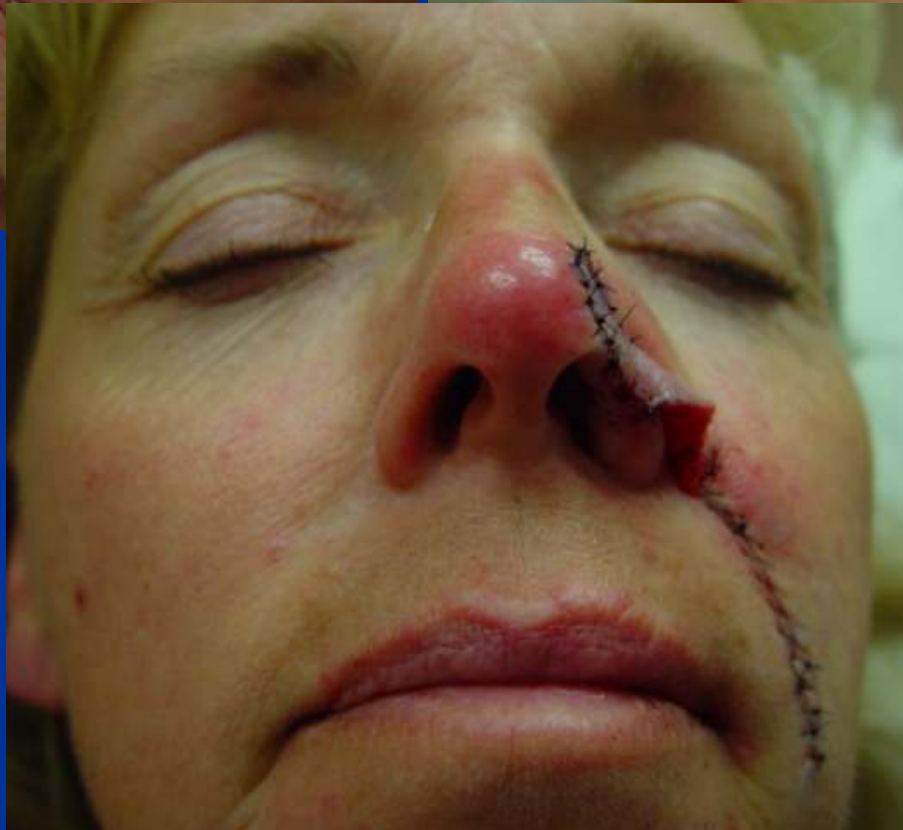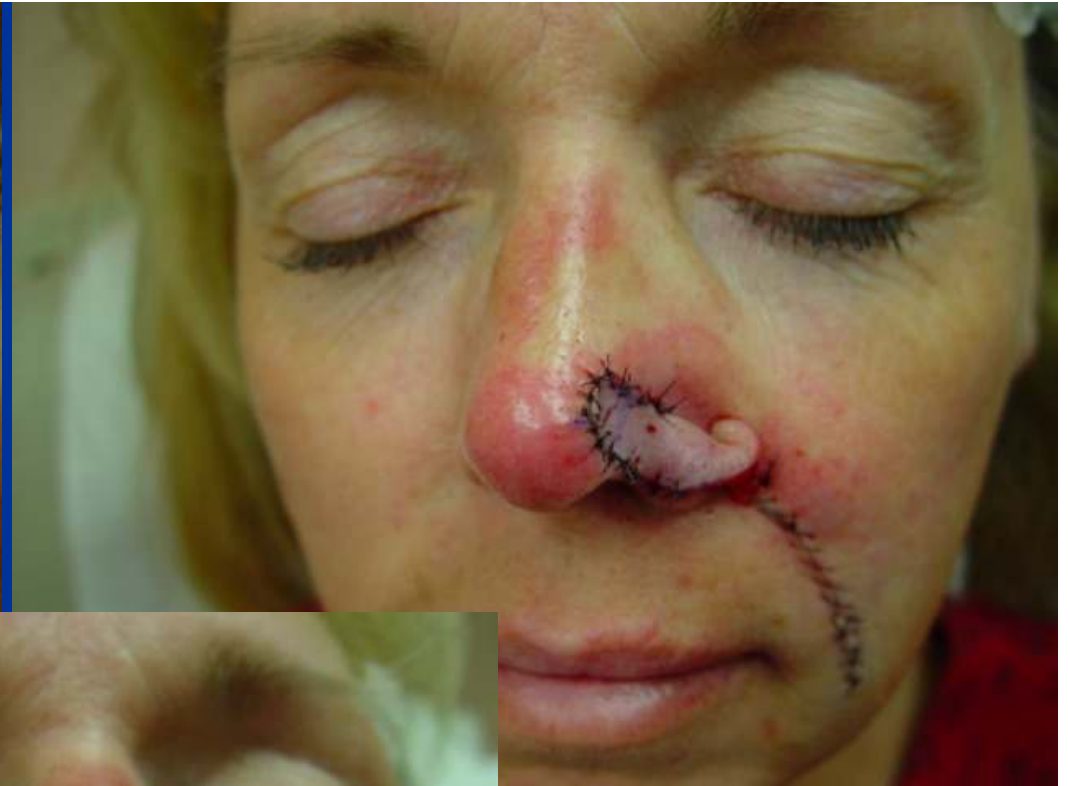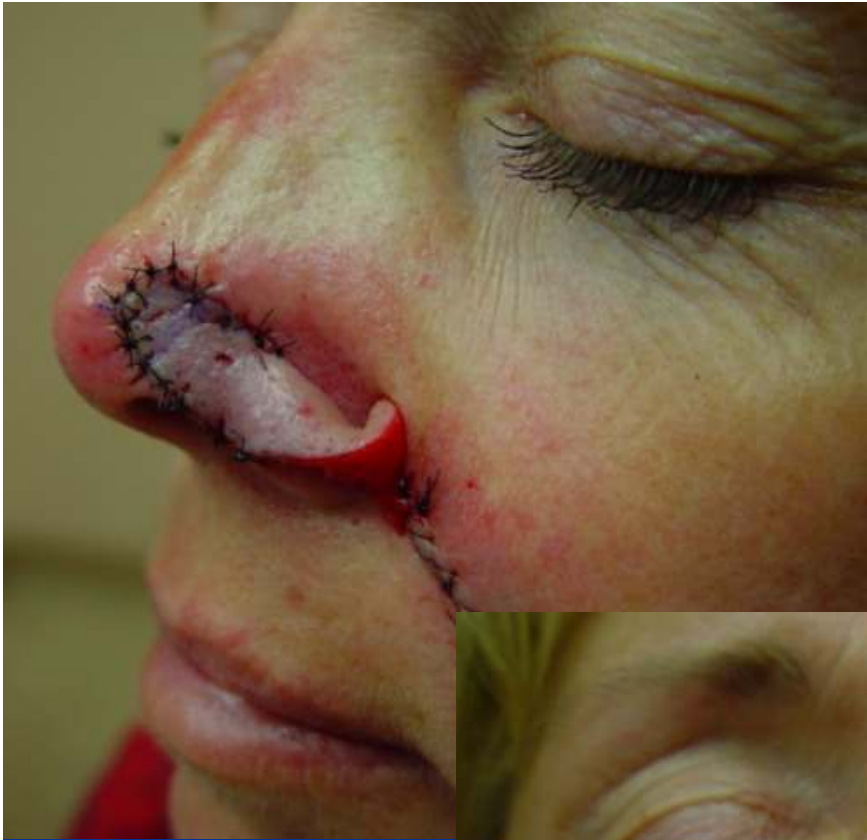**Mohs Surgery
defect to cartilage
for morpheaform
BCC**



**Cartilage graft
from ipsilateral
antihelix**

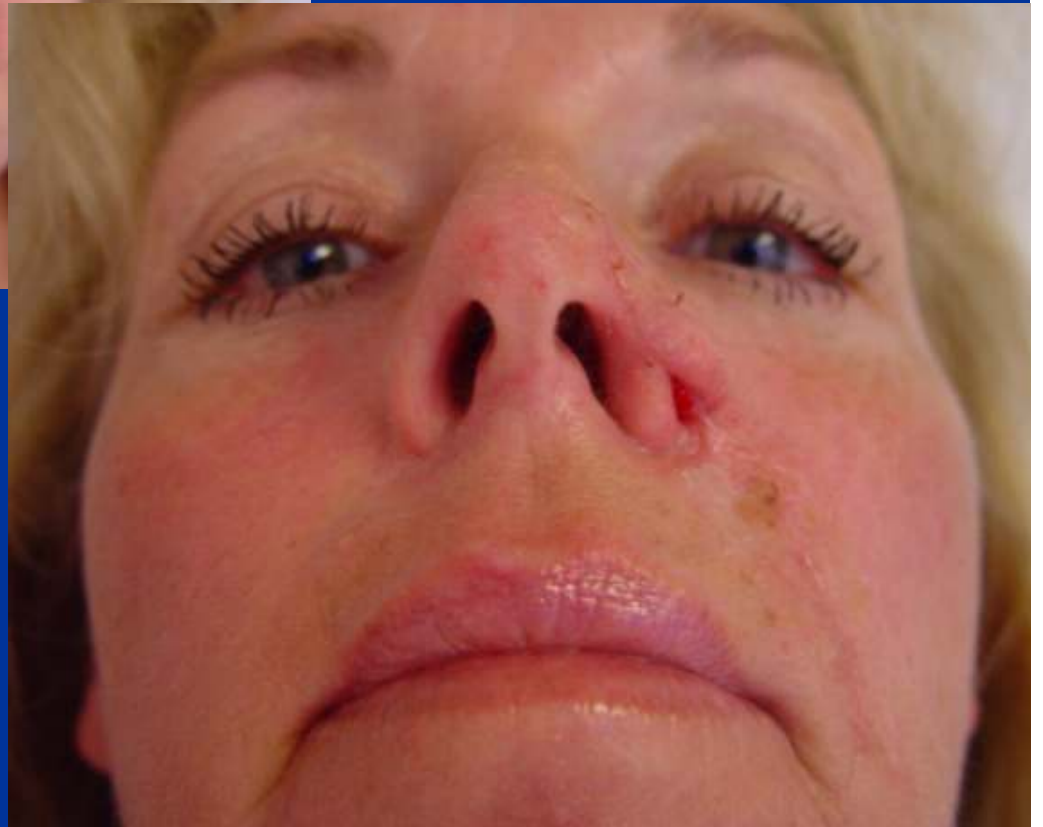
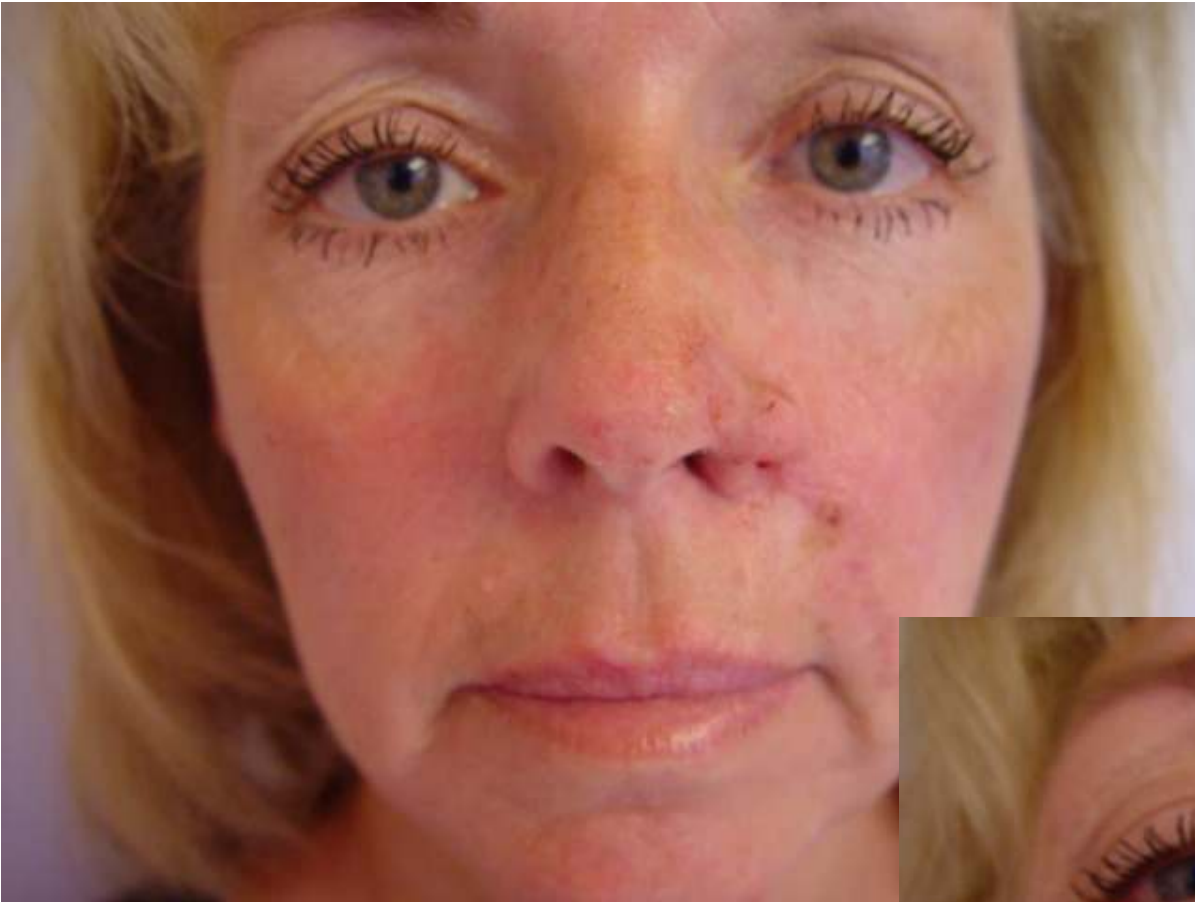
**Nasolabial pedicle flap
is thinned to dermis**

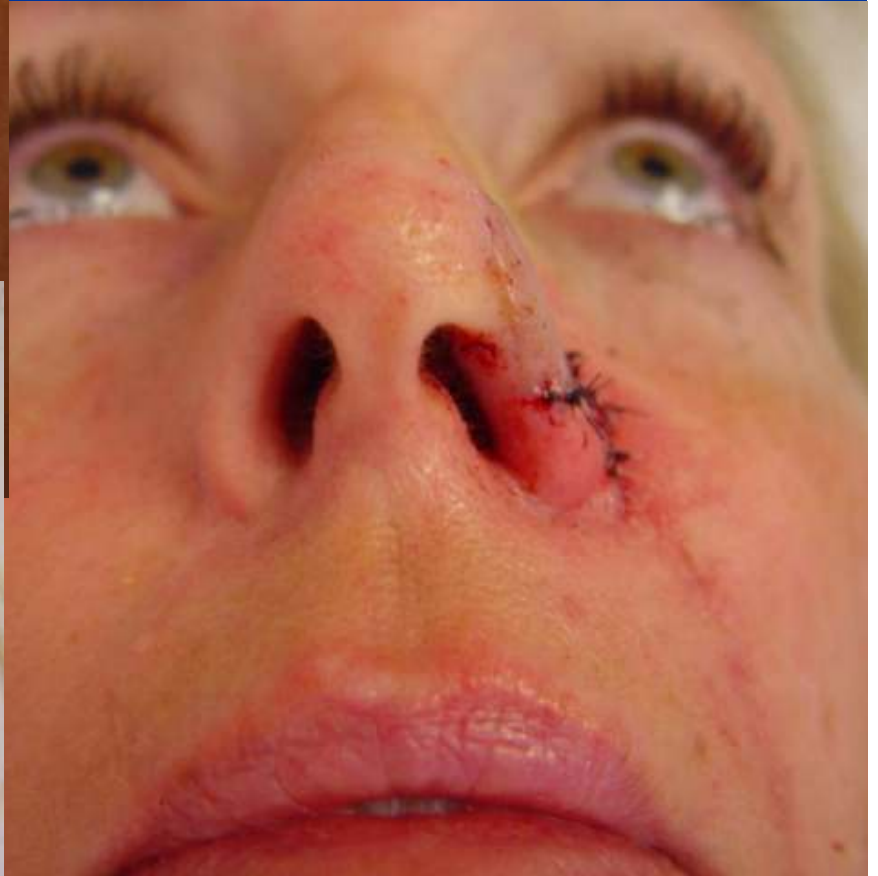
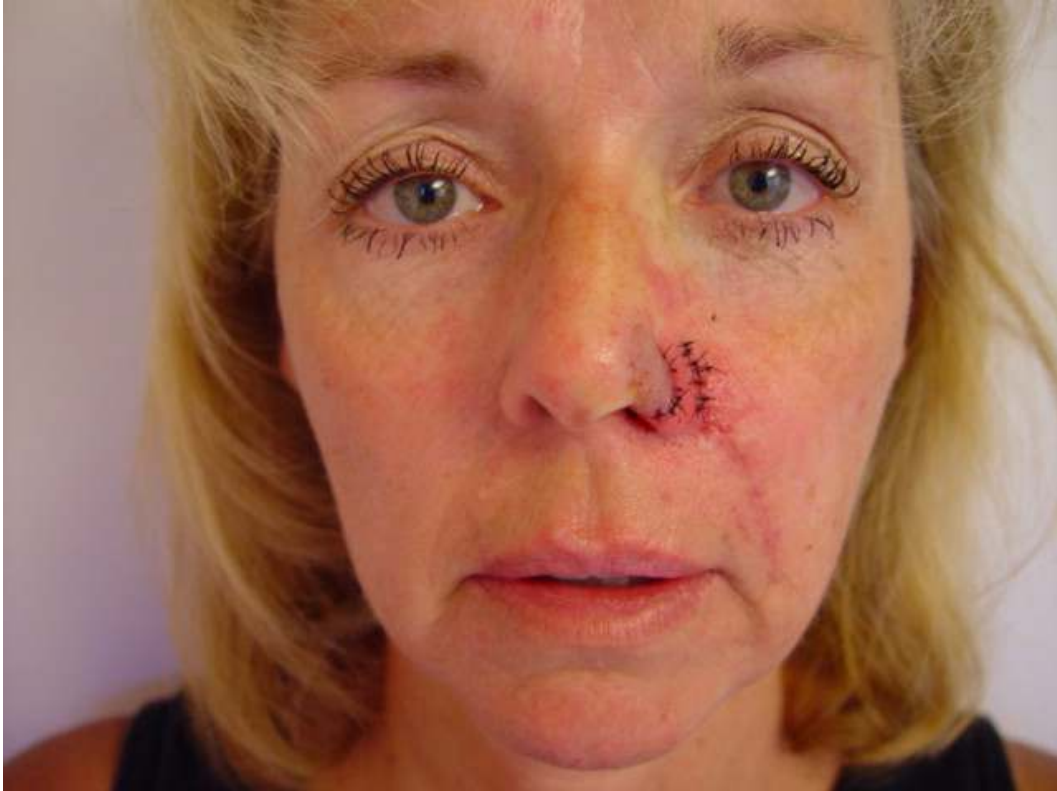
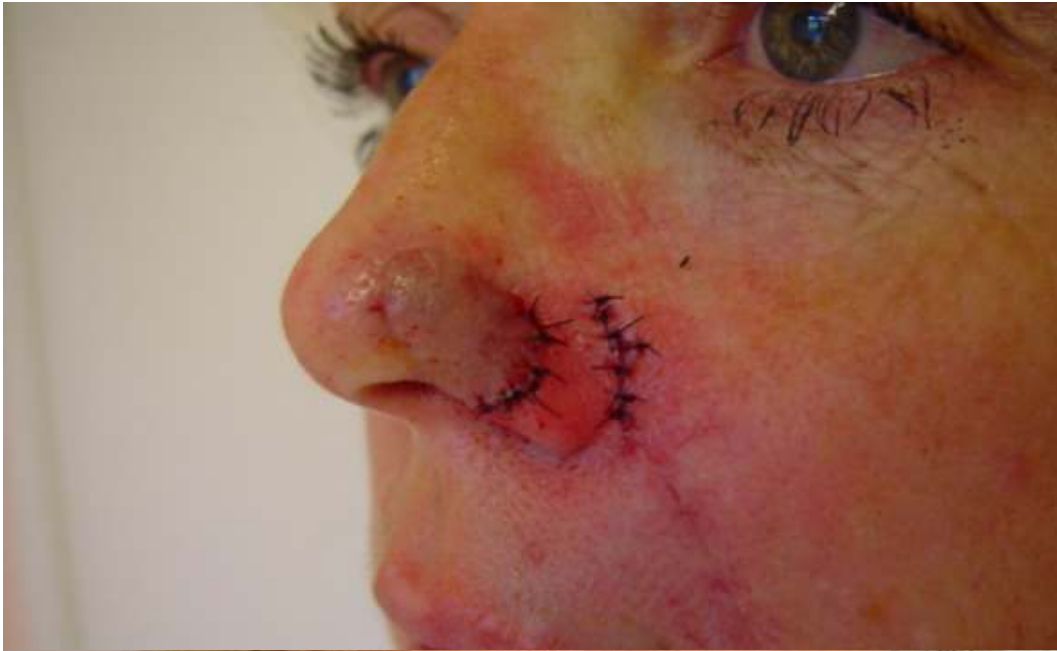
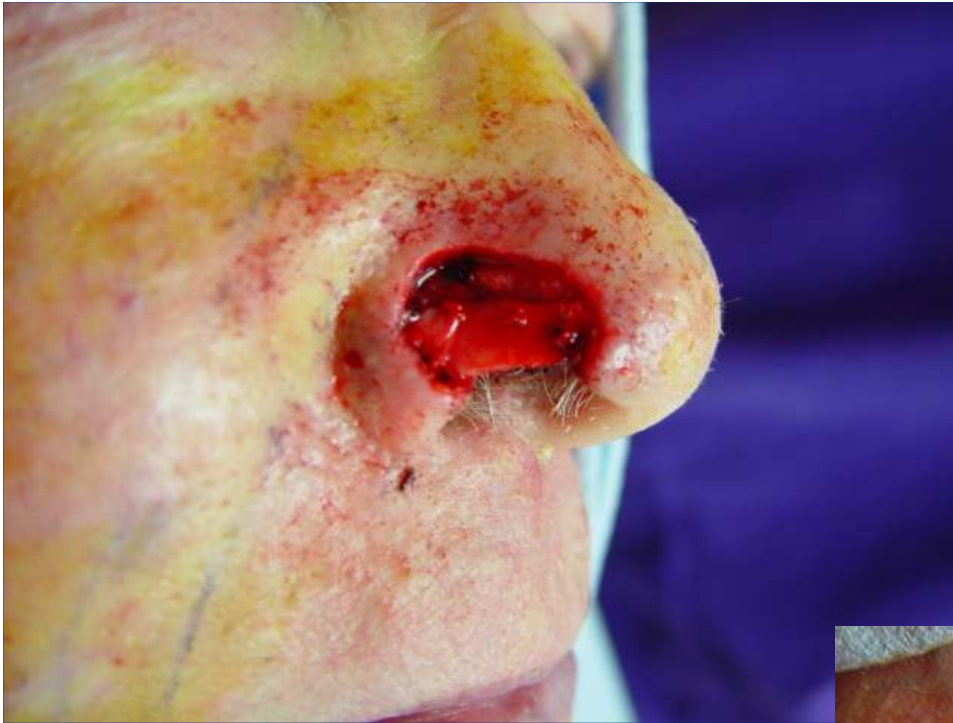**Immediately
post-op**

Three weeks later



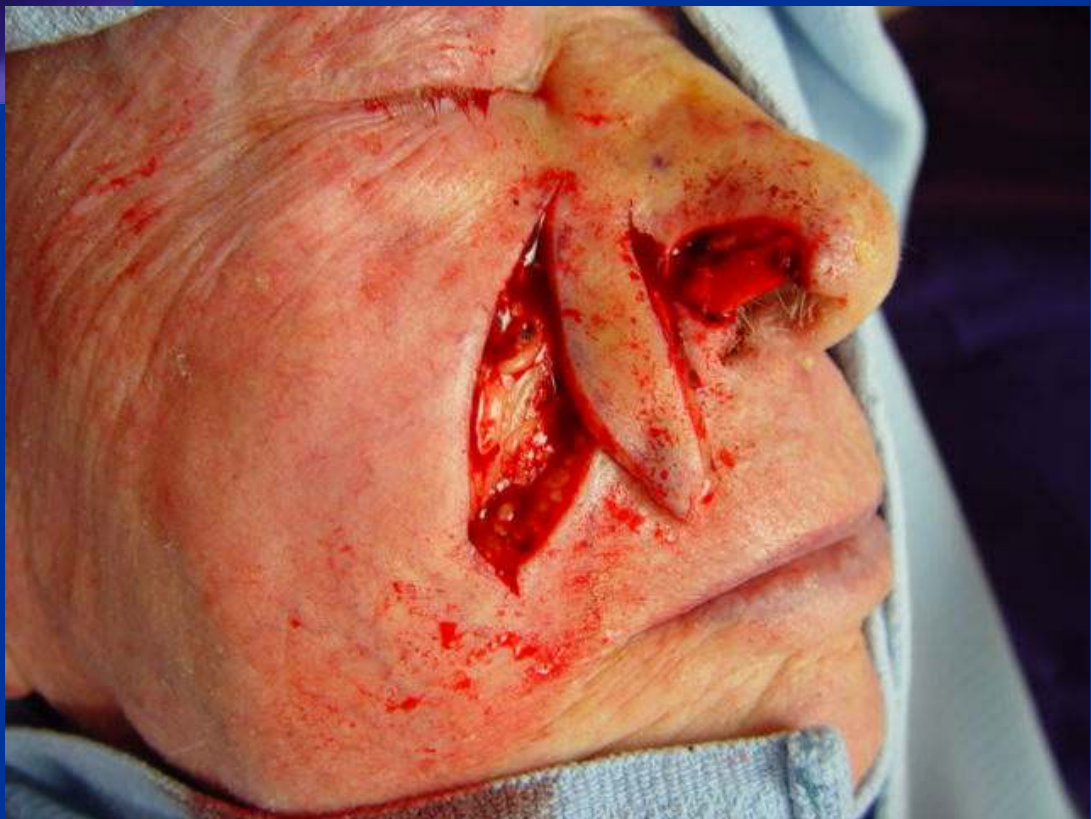**Division of pedicle
with inset at three weeks**

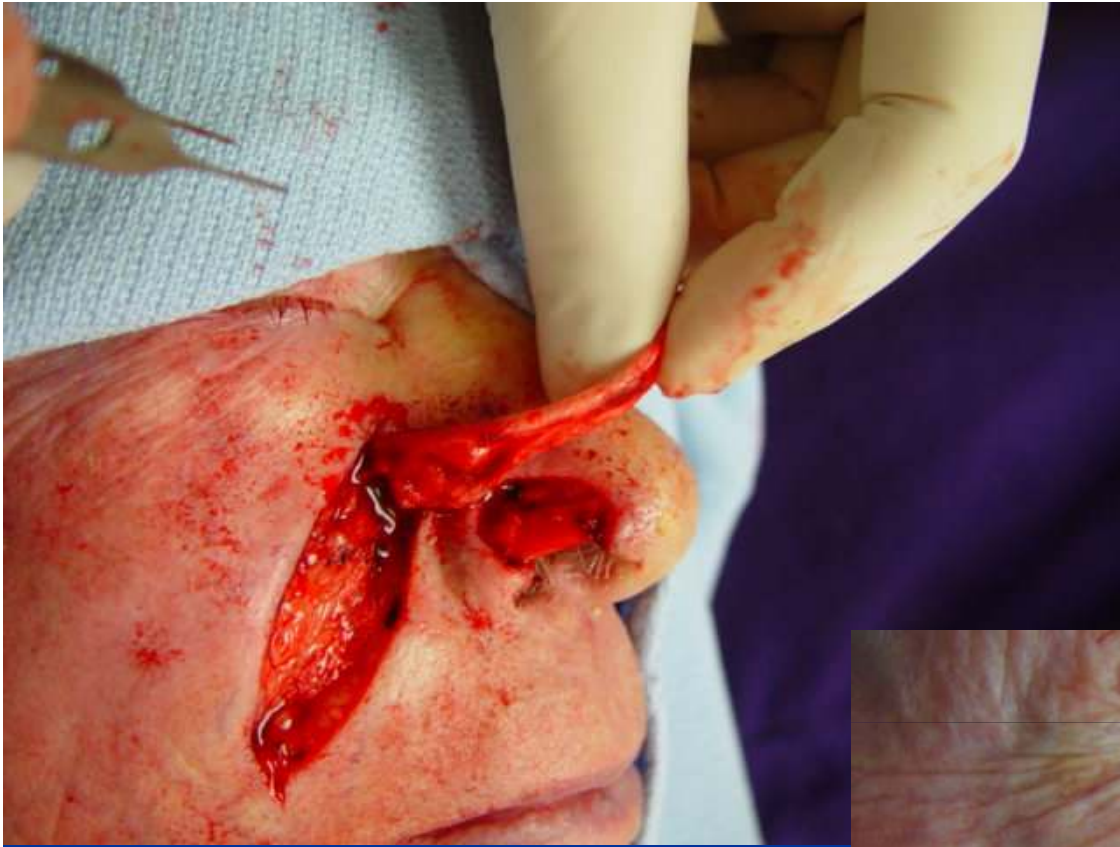




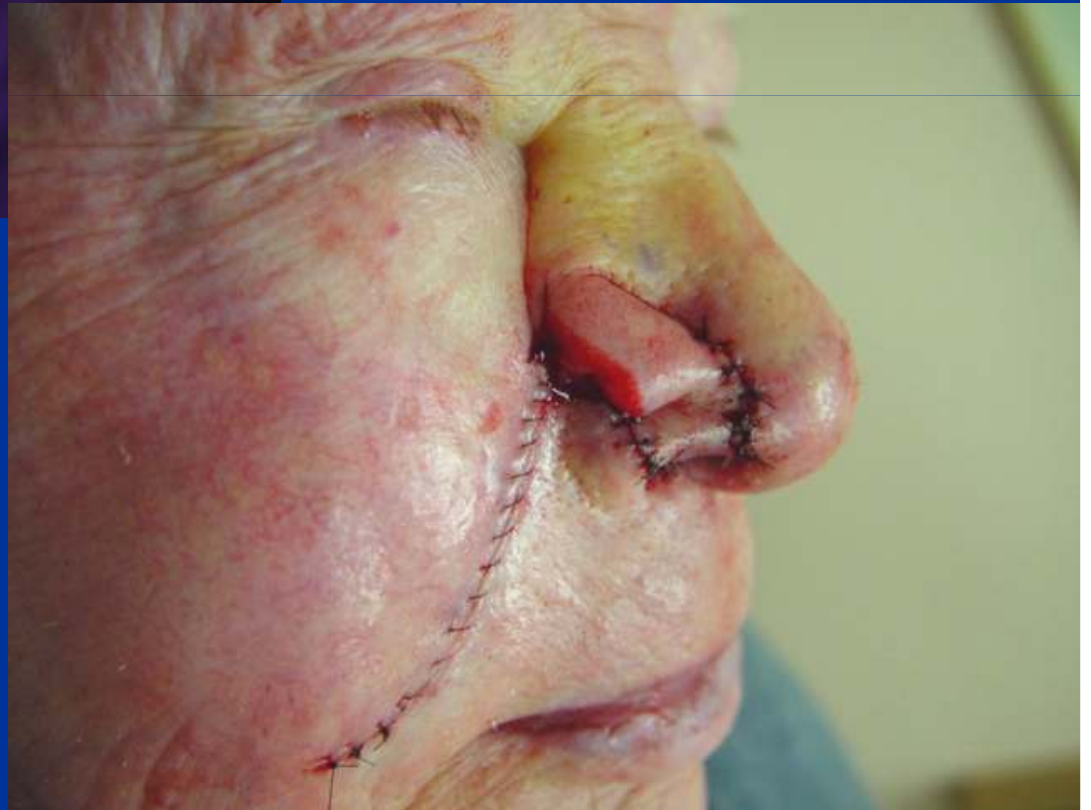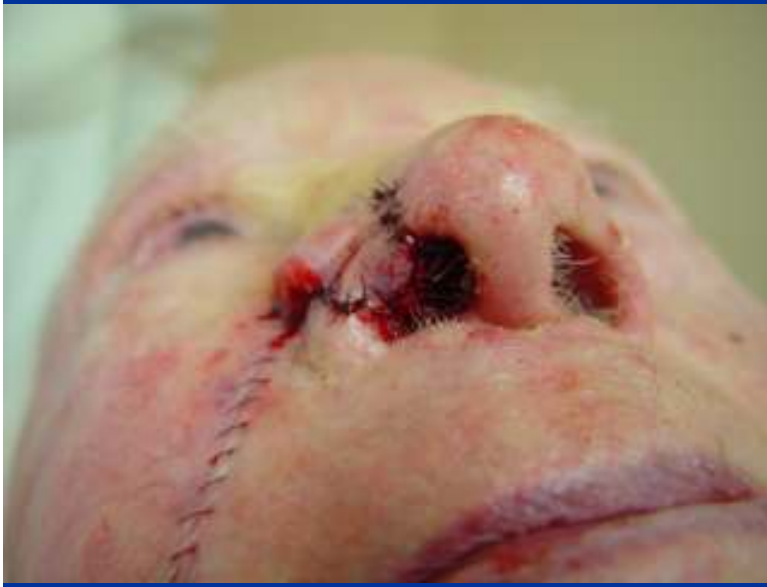Cartilage graft from antihelix

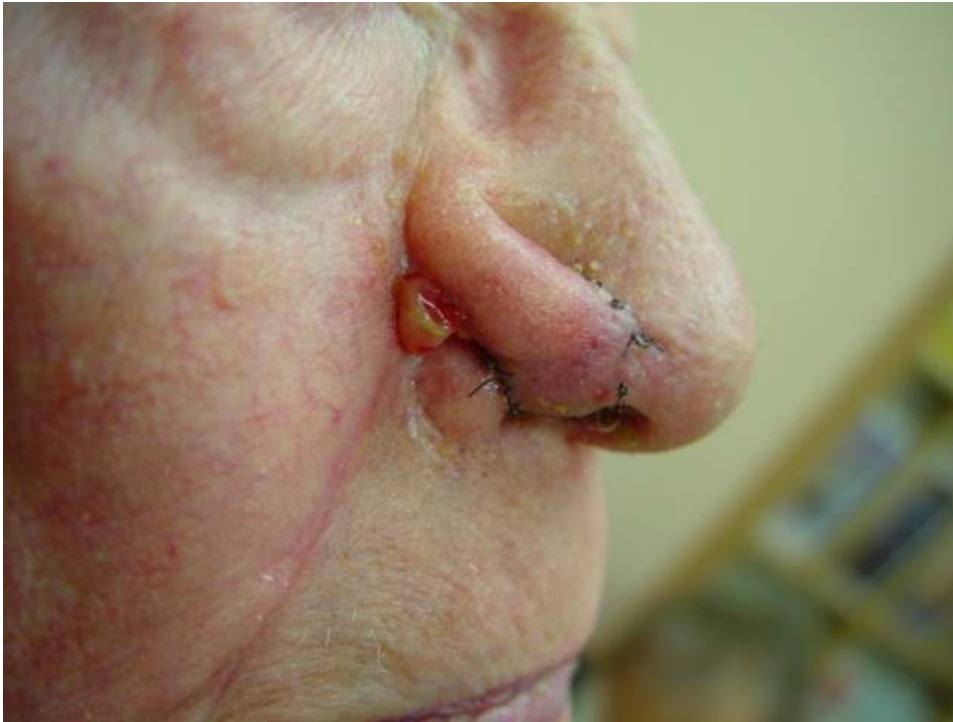2-stage nasolabial
pedicle flap to maintain
alar crease





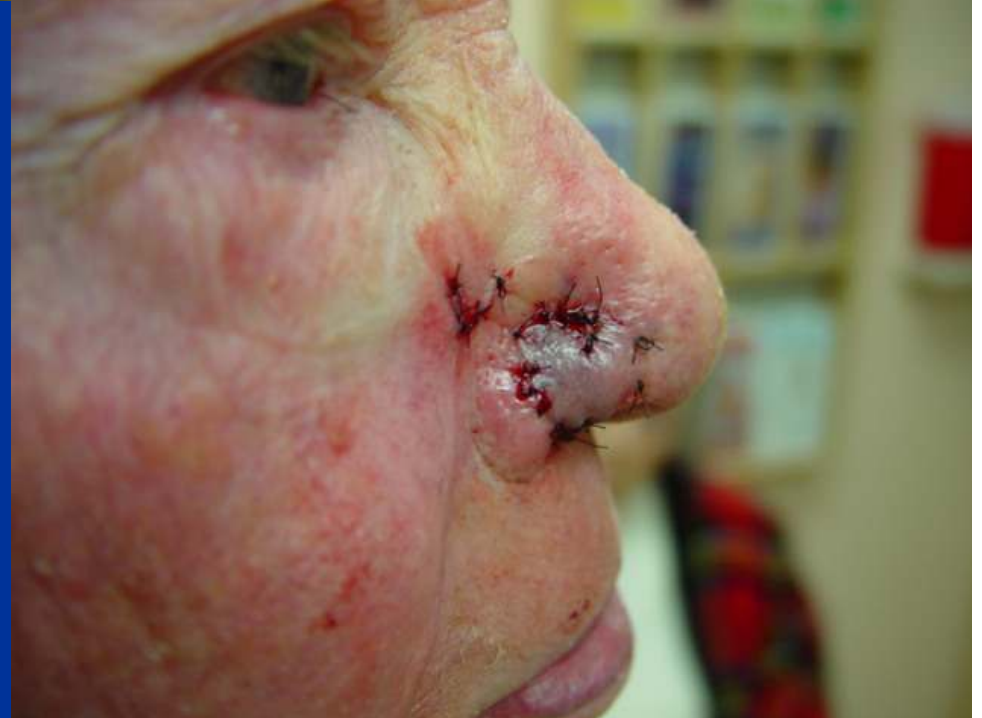2-stage nasolabial
pedicle flap thinned and
wrapped around alar
cartilage graft

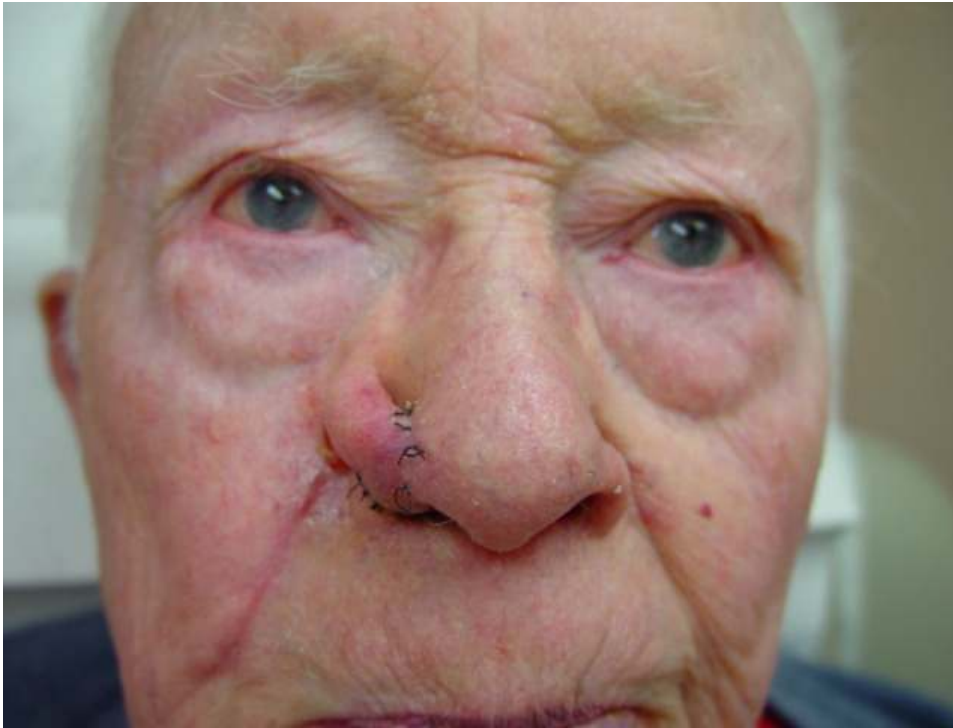



3 weeks after Stage I

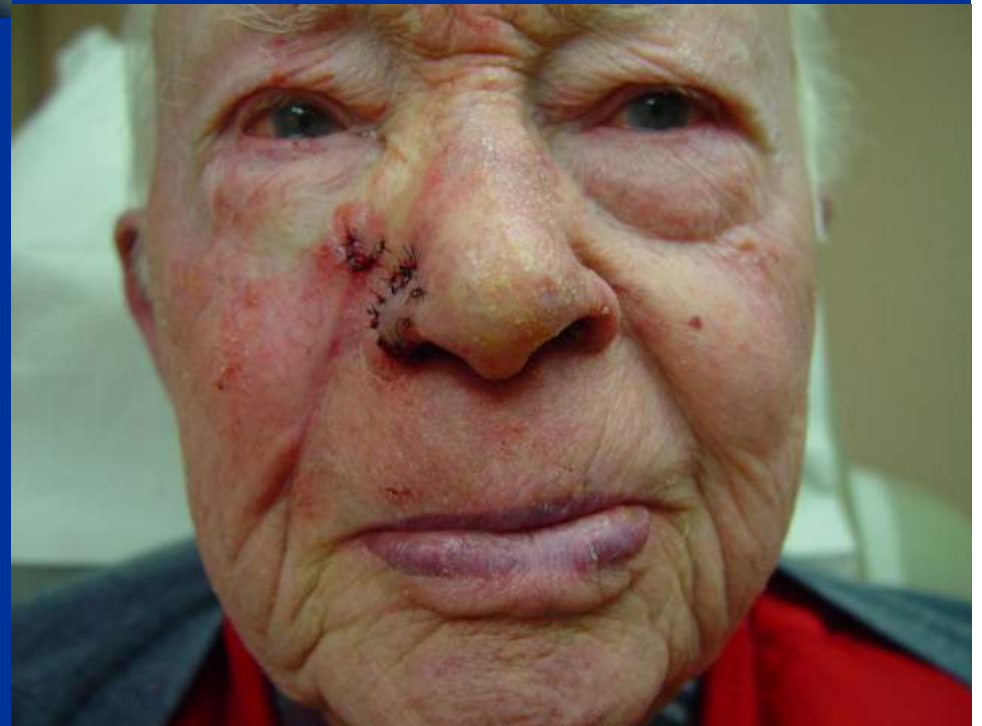Following Stage II:
Division of pedicle

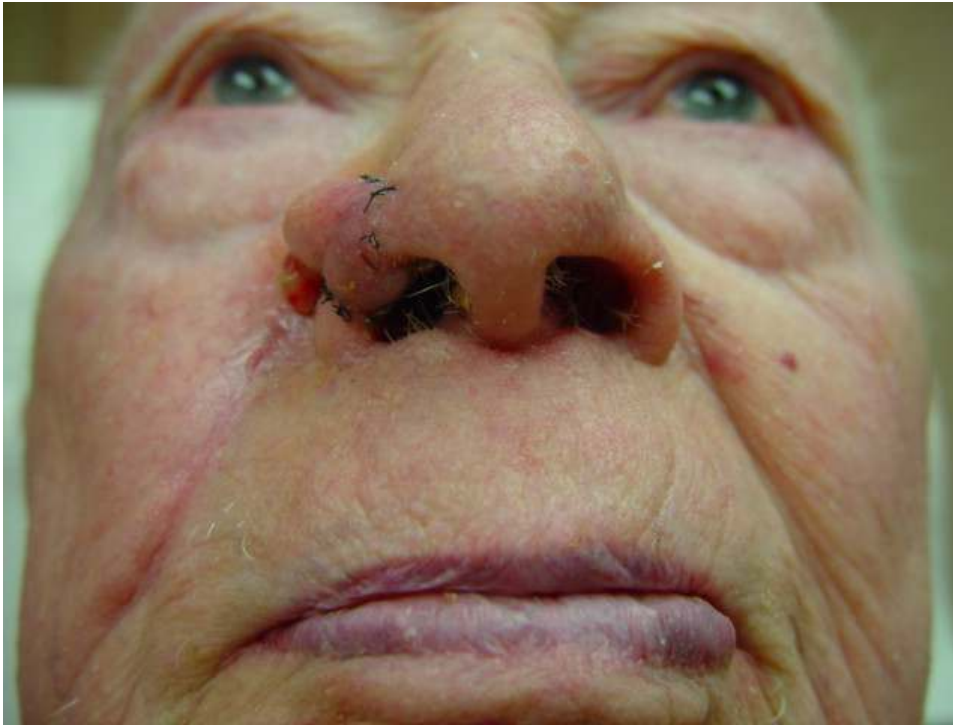



3 weeks after Stage I

Following Stage II:
Division of pedicle





3 weeks after Stage I

Following Stage II:
Division of pedicle

