


# **Pictorial Presentation of Mohs Micrographic Surgery for a Recurrent Tumor on the Forehead**

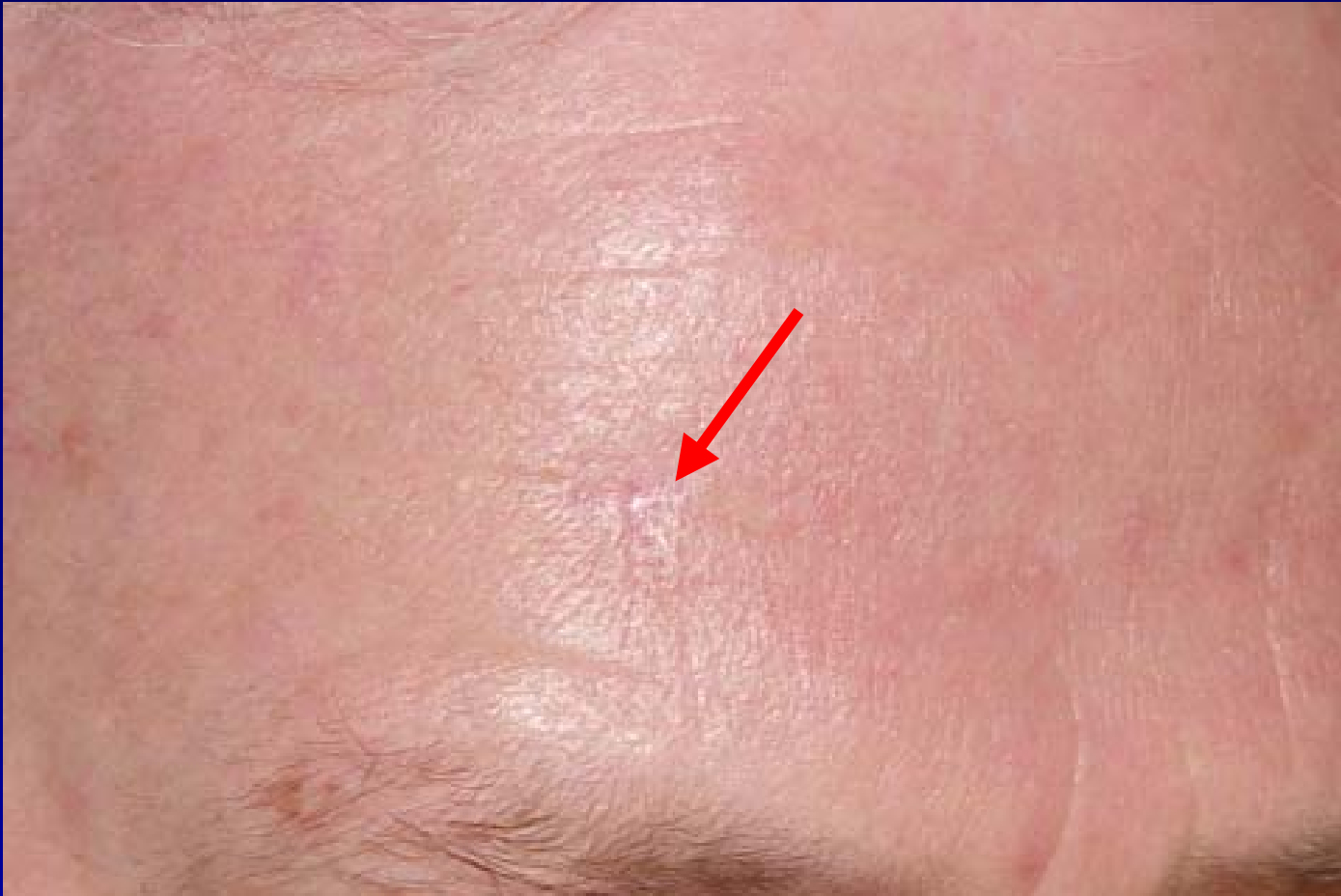**Greg S. Morganroth, MD**

**Fellow, American College of Mohs Micrographic  
Surgery and Cutaneous Oncology**

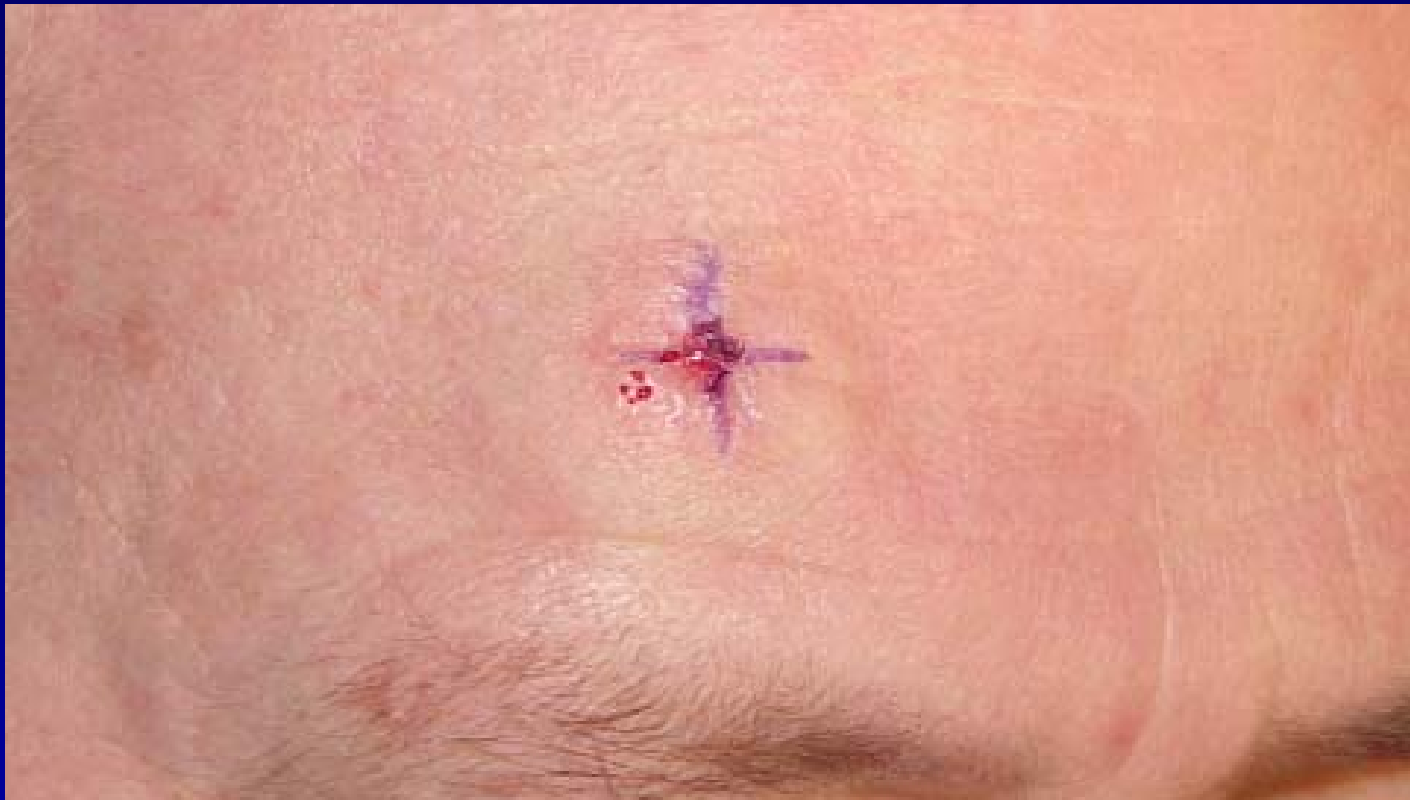**Faculty, Stanford University Facial Plastic Surgery Fellowship,  
Department of Otolaryngology and Facial Plastic Surgery,  
Stanford University Medical Center**



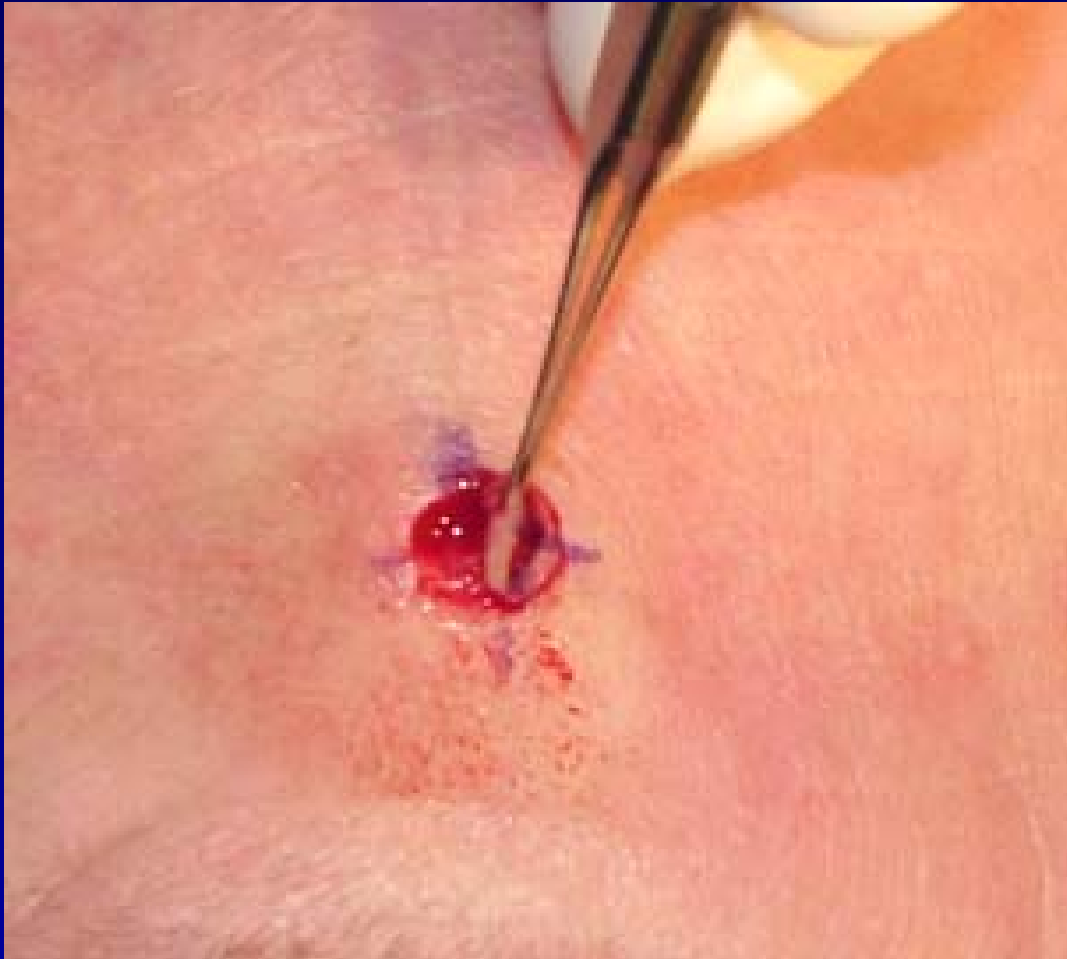**A 48-year-old man presented with a persistent basal cell carcinoma on the right forehead despite two excisions over the past 11 months by his referring physician. The pathology report from the second surgery indicated clear margins (the tumor was all out), however the report was inaccurate because the tumor still returned.**



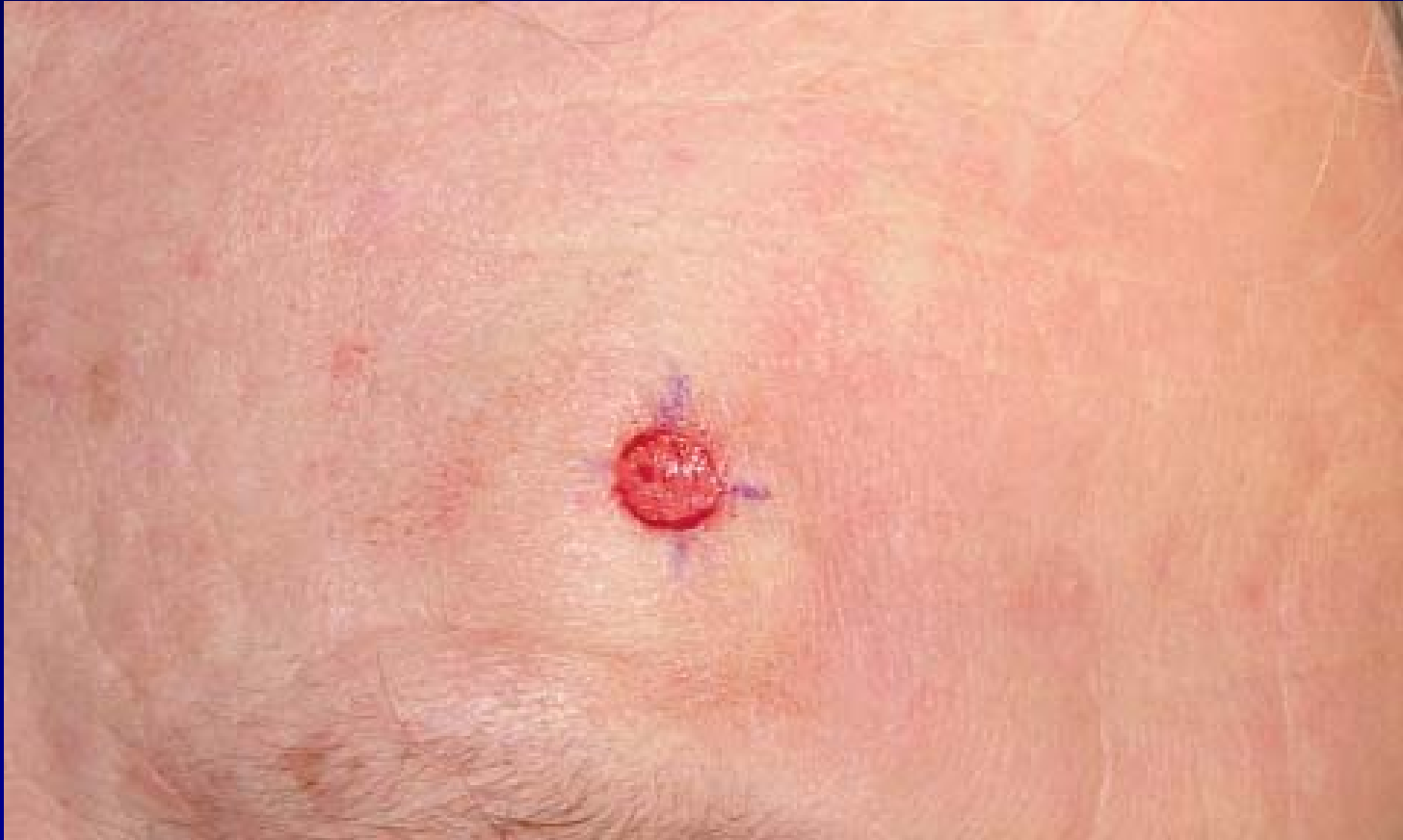**First, the visible tumor is scraped with a curette (circular scalpel) to help define the margin. Skin cancer tissue is more fragile than normal skin and scrapes and bleeds easily. Scar (which does not scrape), a result of two prior surgeries, made the scraping less accurate for outlining the tumor margins. After scraping, a map (purple lines) is drawn on the skin with gentian violet to orient the tissue.**



**Stage I ( the first excision specimen) is created by excising a 1-2mm margin of normal skin around the area demarcated by the curettage (scraping). The tissue is removed in the shape of a pie to allow for examination of 100% of the margin.**




**After removal of Stage I, the skin defect seen here is bandaged. The patient returns to the waiting room. Satellite TV, magazines, and a cup of coffee help you to pass the 20 to 40 minute tissue processing time.**



**The following photos outline the tissue processing technique that take place in the Mohs laboratory.**

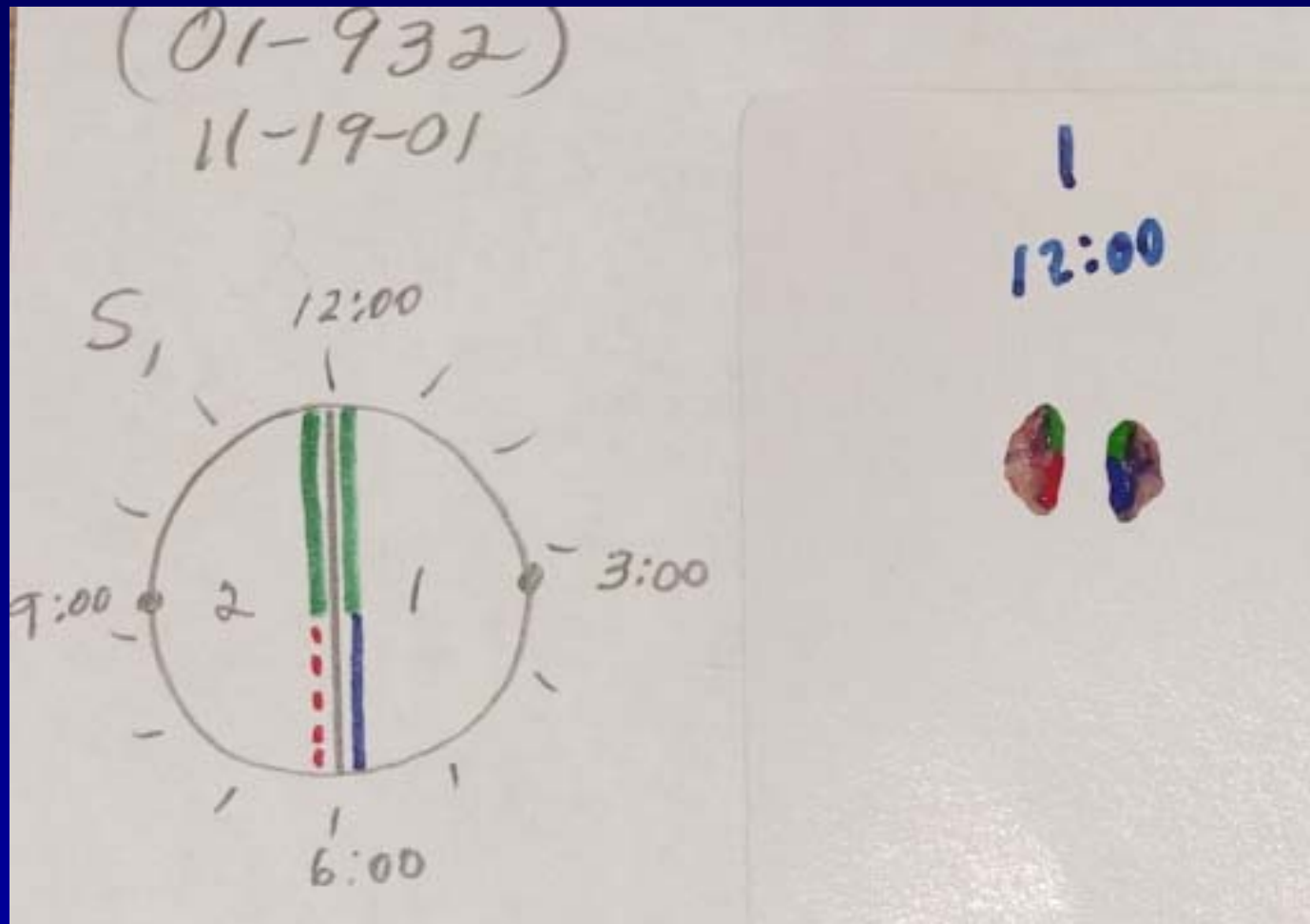
The tissue is taken to the mapping area of the lab. The pie shaped tissue will be divided and mapped. Ink pens and tissue dyes are used to create a corresponding paper and tissue map.



Tissue dyes

Scalpel used to cut tissue

Here is the corresponding tissue and paper map for Stage I. The pie-shaped tissue is divided into two pieces and color-coded for accurate orientation. Note the corresponding green, red, and blue colors on the tissue and paper.



**This is a cryostat—the machine used to freeze tissue and cut very thin tissue sections for microscopic examination.**



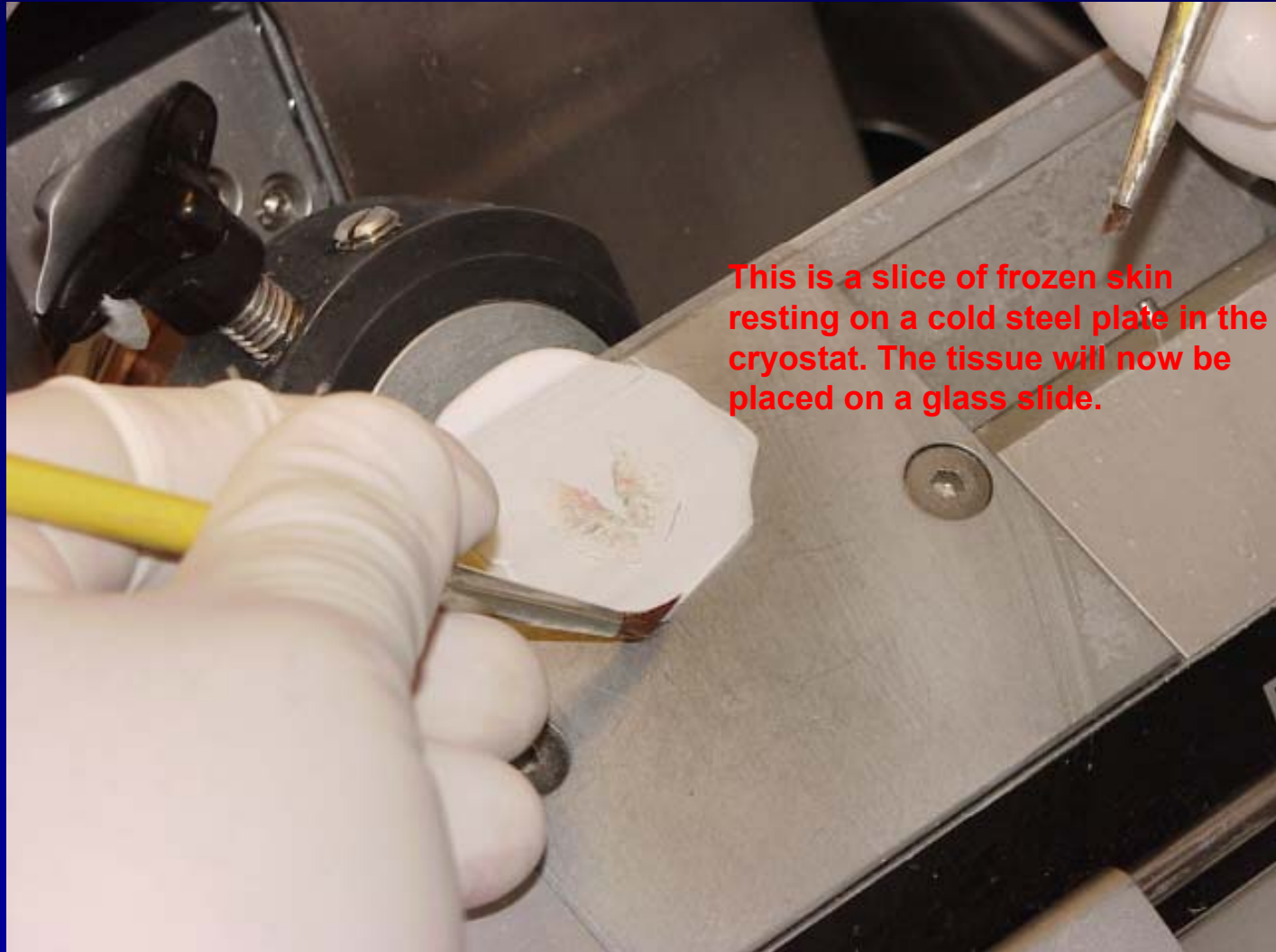**The two tissue sections (or halves of the pie) are mounted in the cryostat and frozen so that 100% of the margin (pie crust) is in the plane of the cryostat blade. Note the clearly demarcated tissue dyes that maintain the accurate tissue orientation.**



**This is the embedding material that keeps the tissue stable for cutting**

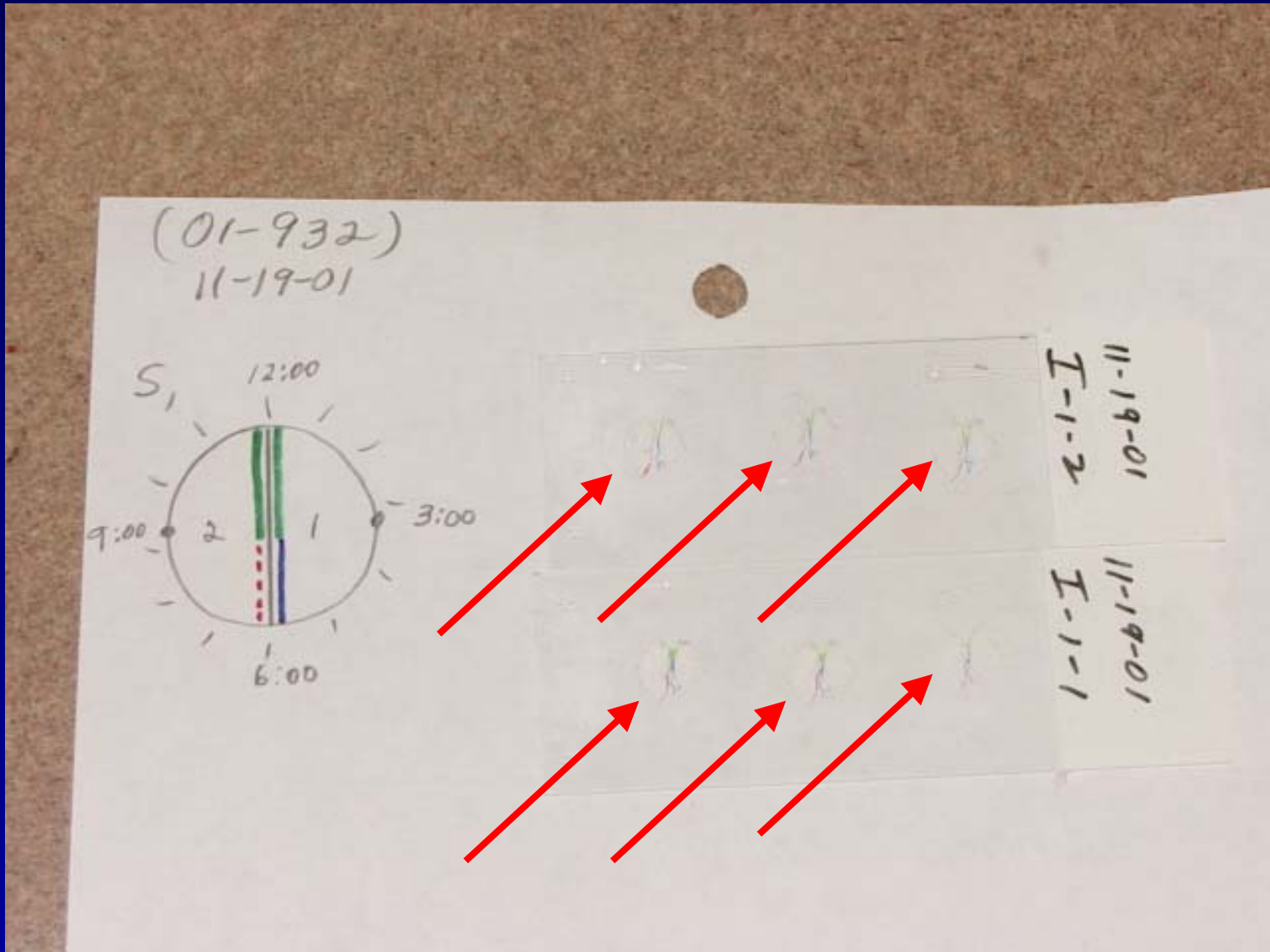
**This is the edge of the tissue or pie crust**

**The frozen tissue is cut by the cryostat in 10 micron thick sections at -20°C by a Mohs histotechnician.**



**This is a slice of frozen skin resting on a cold steel plate in the cryostat. The tissue will now be placed on a glass slide.**

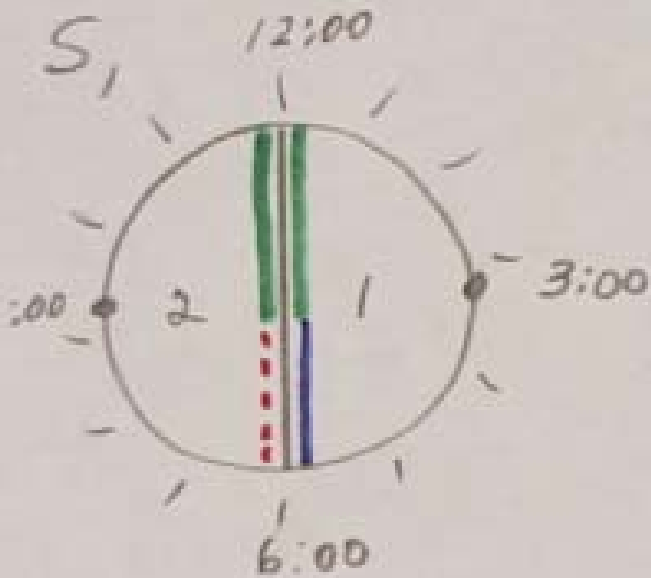
Freshly cut sections of tissue are placed on glass slides prior to staining. Prior to staining, they are difficult to see except for the outline of tissue dye.



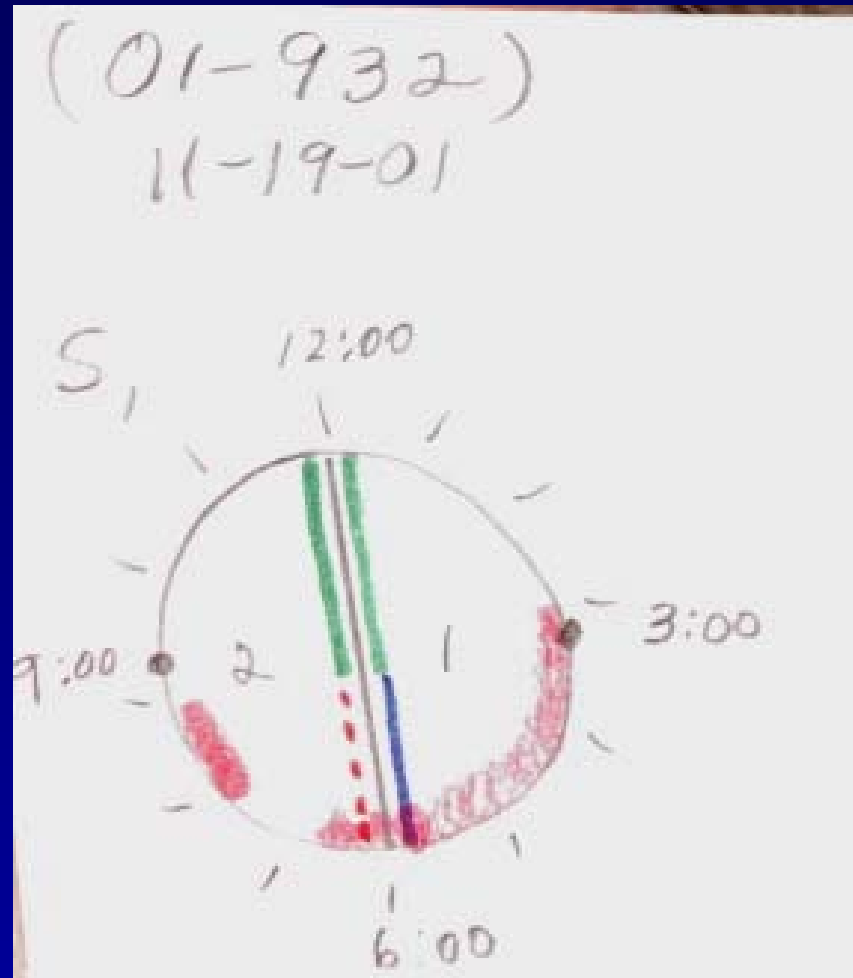
The fresh tissue sections are stained with hematoxylin and eosin to help distinguish cell types in the skin before microscopic examination by the Dr. Morganroth.



Here are the completed tissue sections for Stage I. The entire skin excision margin (pie crust) is represented on each of these sections that correspond exactly to the paper map and the map on the patient's forehead.

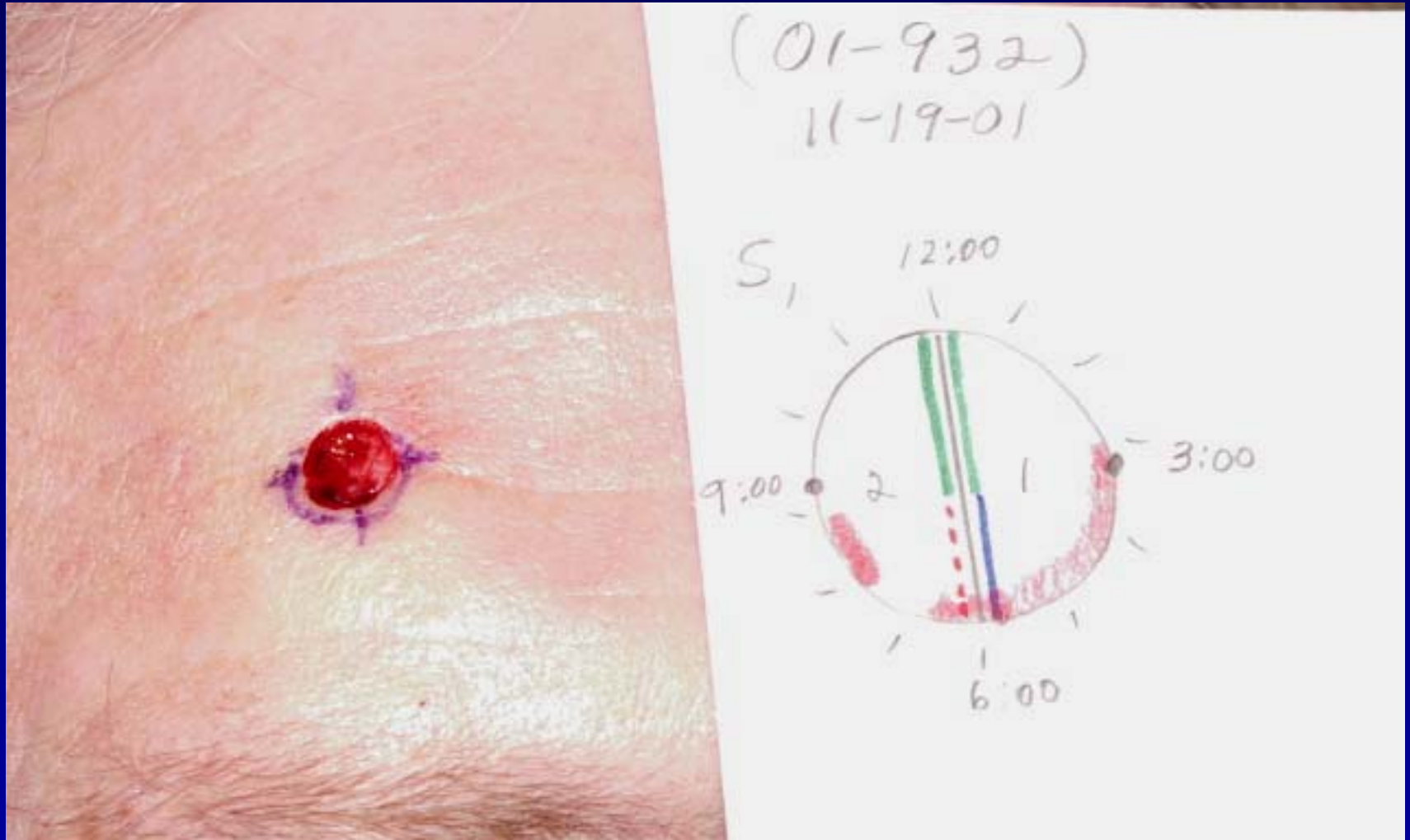


The stained sections are examined with a microscope. The excision margin (pie crust) that is positive for residual tumor is marked on the map with red pencil. In this case, tumor is positive from 3 to 9 o'clock. The patient requires more tissue removal.



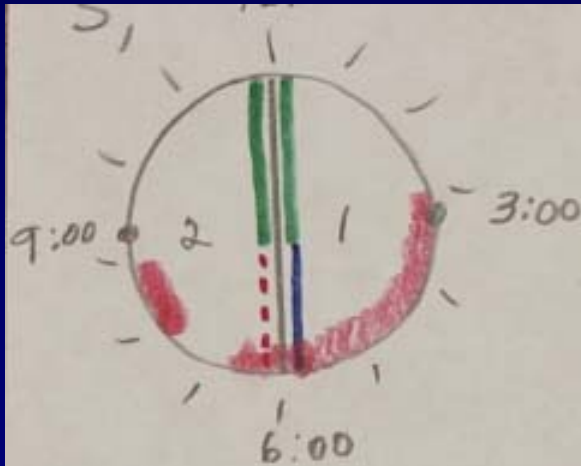
The patient returns to the procedure room from the waiting room and the paper map is compared to the forehead map.

Gentian violet demarcated the area of skin that will be removed as Stage II. This specimen will correspond to the red pencil on Stage I.

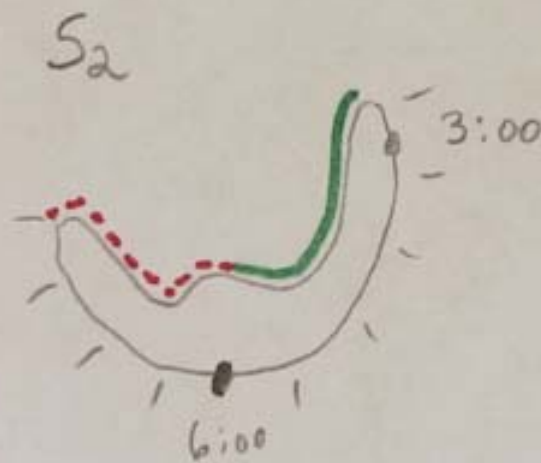


**Stage II consists of the skin excision that corresponds with the positive area demarcated by red pencil on Stage I (3 to 9 o'clock).**

**Stage I**



**Stage II**



12:00



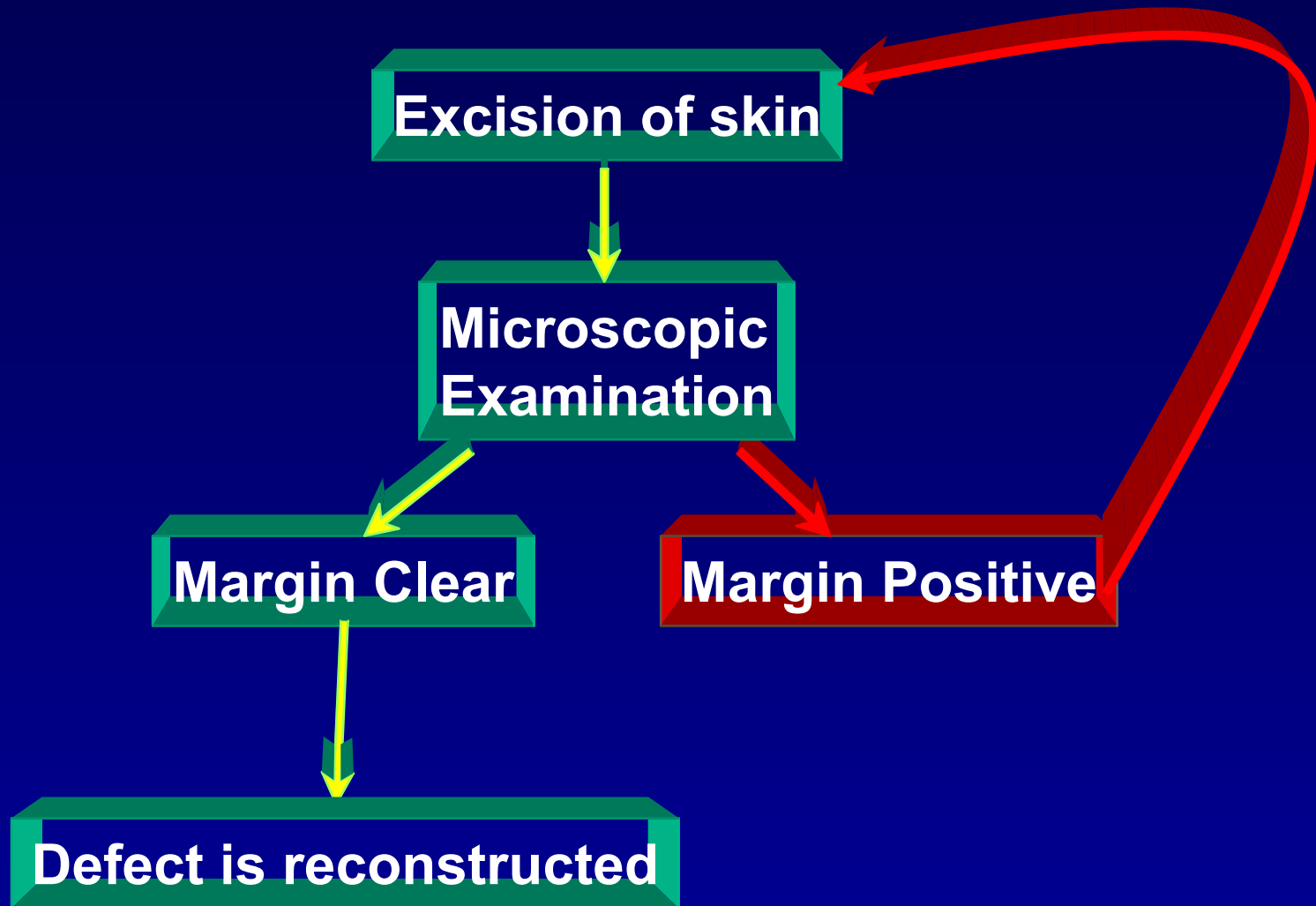
**Stage II will be mapped, divided, color-coded, frozen, sliced, stained, and microscopically examined exactly like Stage I.**

**If the tissue sections of Stage II are clear of tumor, the patient is ready for reconstruction of the skin defect.**

**If tumor is present on the tissue sections of Stage II, the patient will return to the room and have more skin removed. This additional tissue will be called Stage III.**


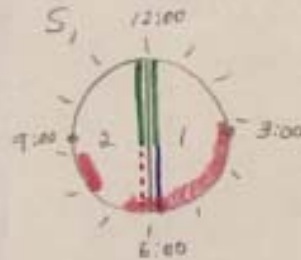
**This process is repeated until the Stage is clear of tumor as depicted in the next photo.**

# Mohs Micrographic Surgery

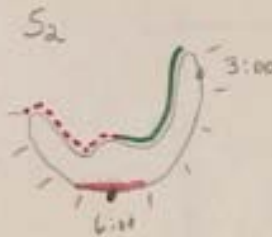


This patient's recurrent tumor required five Mohs stages for complete removal. The five stages are outlined below. The map reveals that the tumor tracked downward in the direction of 6 o'clock as demarcated by red pencil.

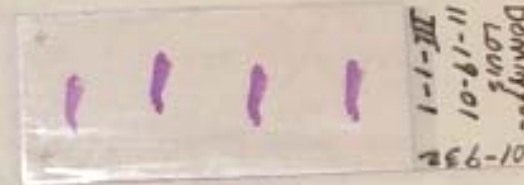
Stage I



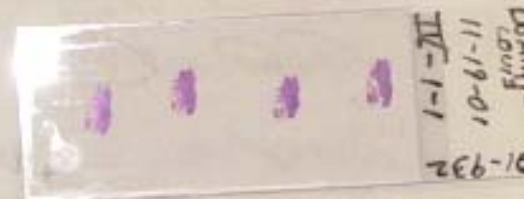Stage II




Stage III



Stage IV



Stage V



Clear of tumor

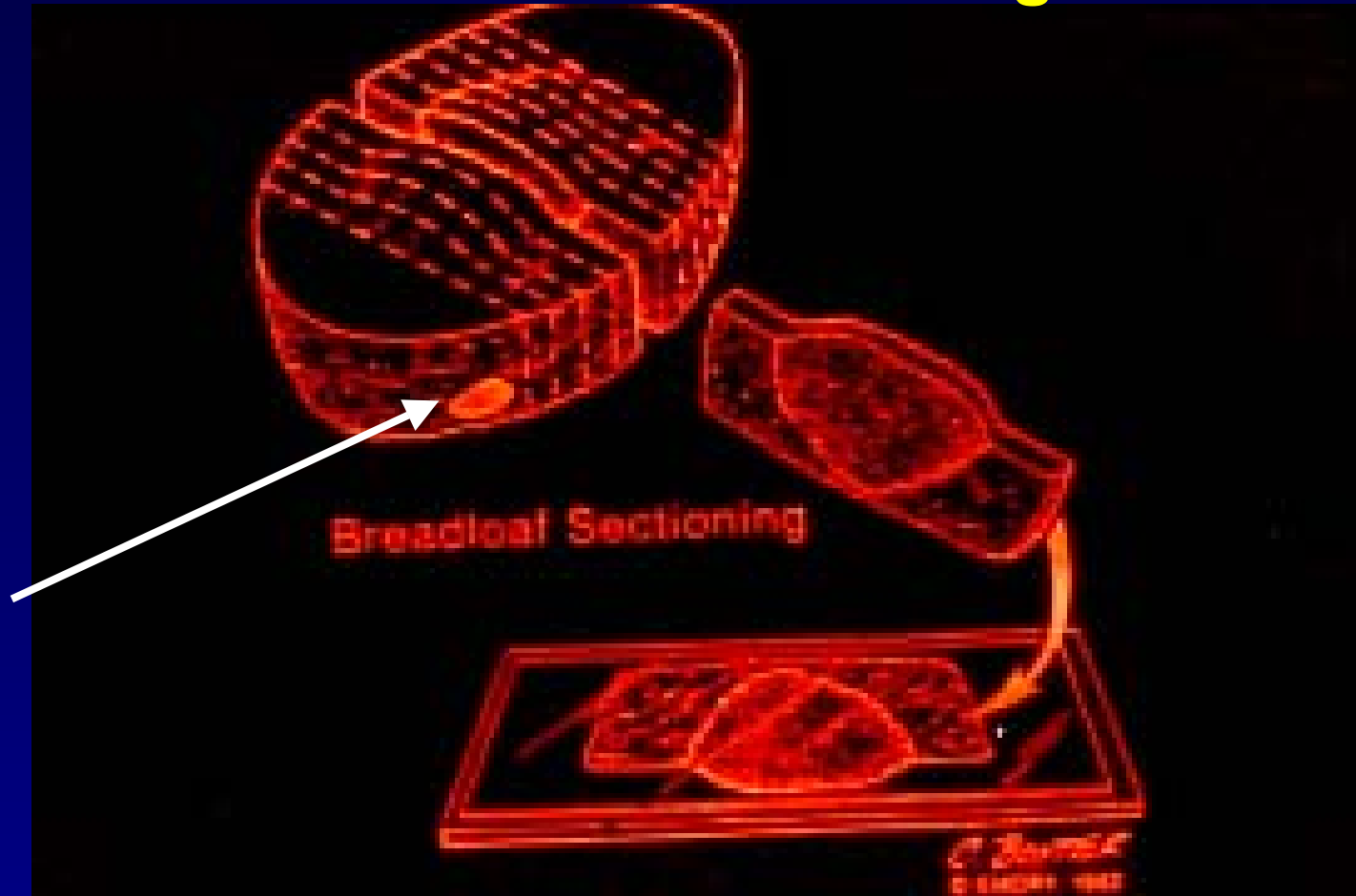


**Why did this patient's original pathology report from the referring doctor's second surgery indicate that the tumor was removed when it wasn't actually removed?**

**All standard techniques for tissue processing examine **less than 1%** of the true surgical margin unlike Mohs surgery which examines 100% of the true surgical margin.**

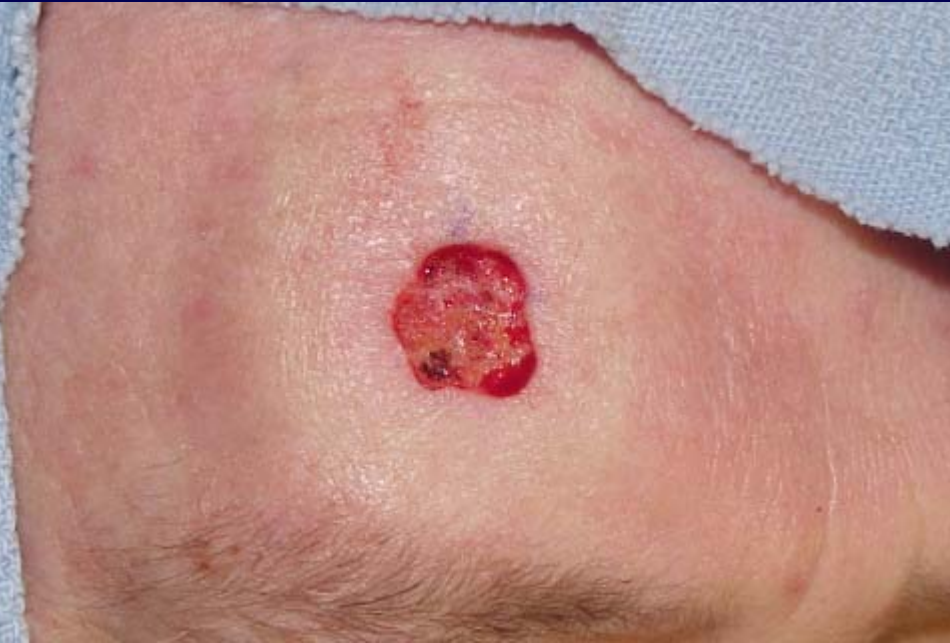**The following photo illustrates the most common tissue section approach used in all pathology laboratories. In this example, the pathology report would indicate complete removal of the skin cancer when, in fact, it is still present in the patient's skin.**

# Breadloaf Sectioning

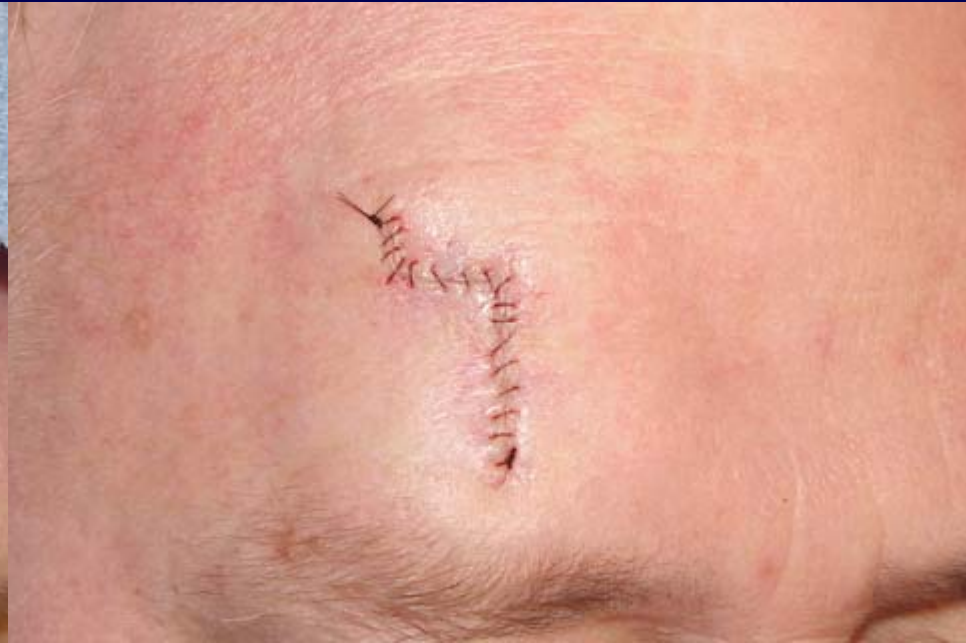

The tissue is sliced like a loaf of bread and a few slices are examined. If these slices (that represent **less than 1%** of the margin) are free of tumor, it is assumed that the other 99% of the tissue is also clear. The white arrow shows a tumor tentacle that would be missed by this approach.

**Final defect after five Mohs surgery stages**



**Advancement flap reconstruction of the defect**



**Mohs surgery examined 100% of the margin and removed this difficult tumor with the highest possible cure rate and minimal sacrifice of normal, uninvolved tissue. Note the irregular shape of the defect that accurately matches the true shape of the tumor. Mohs surgery also provided the smallest possible defect and allowed closure of the skin with the smallest possible scar.**