


# Facial Reconstruction

**Greg S. Morganroth, MD**

**Adjunct Clinical Professor of Otolaryngology/Head and Neck Surgery, Stanford University**

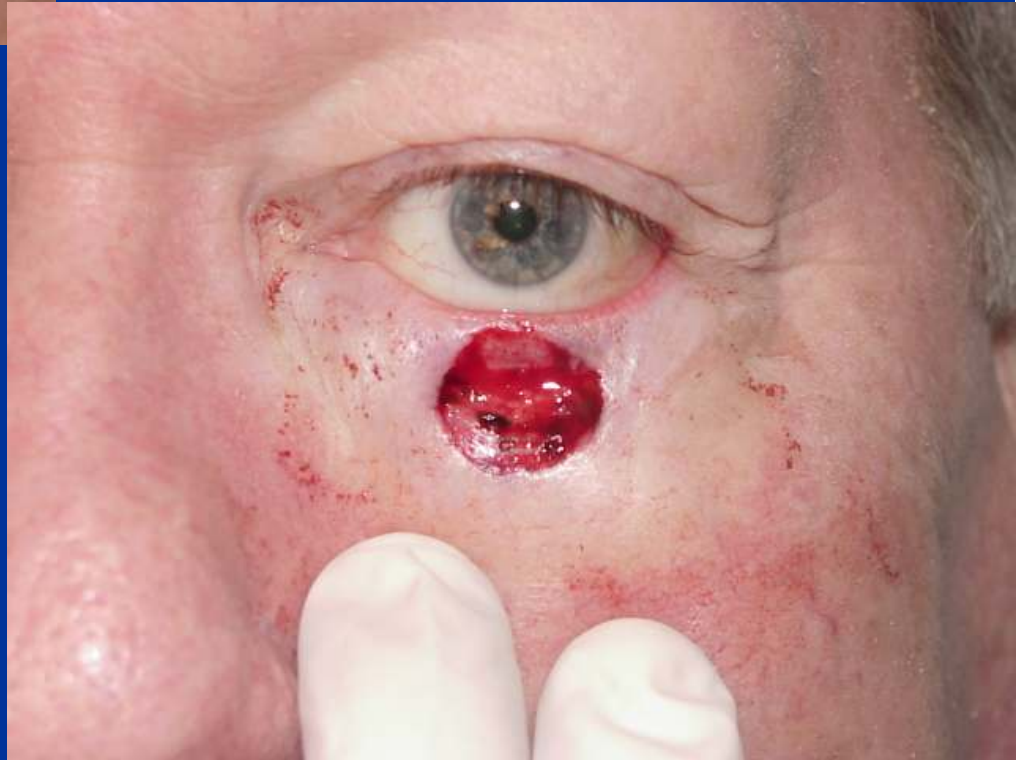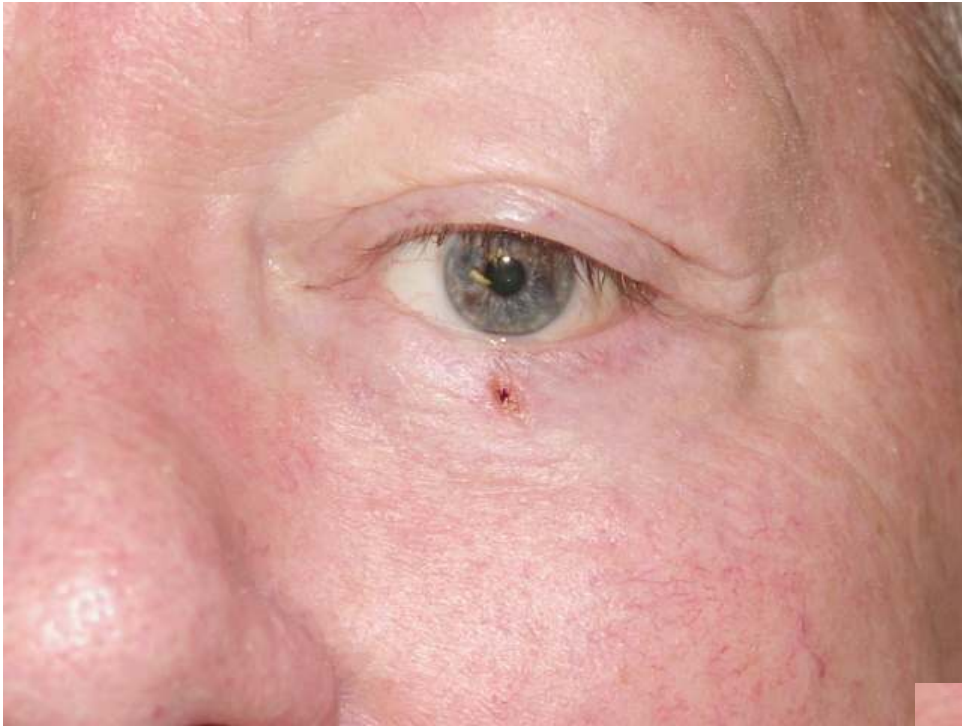**Assistant Clinical Professor of Dermatology, University of California, San Francisco**

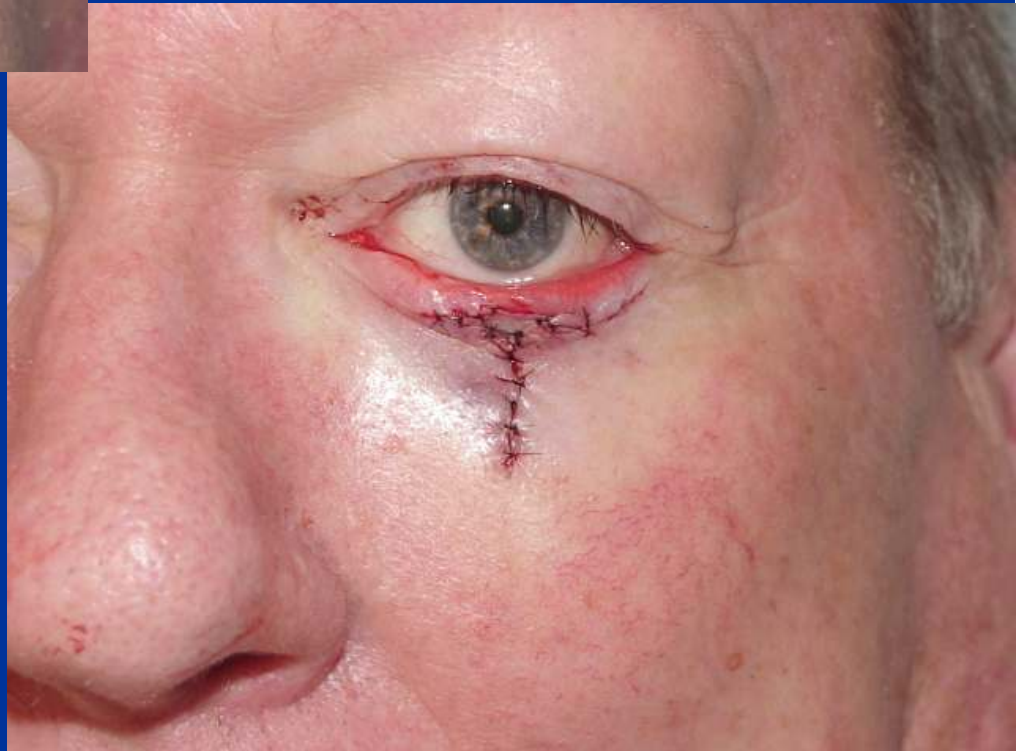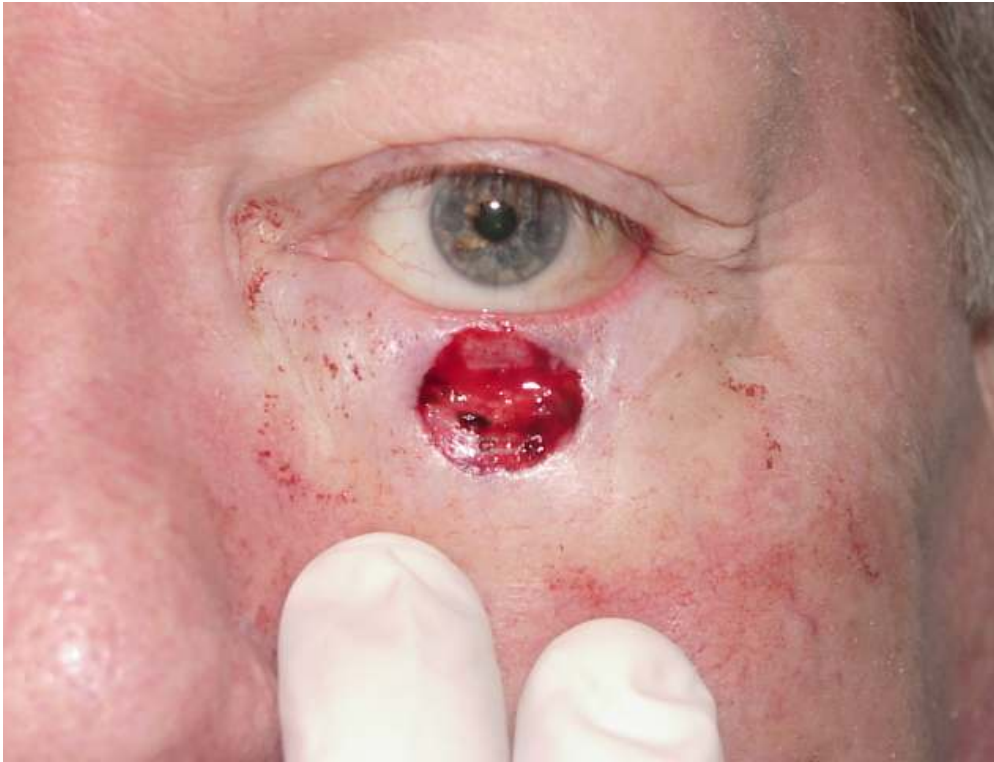**Fellowship Director, American College of Mohs Surgery**

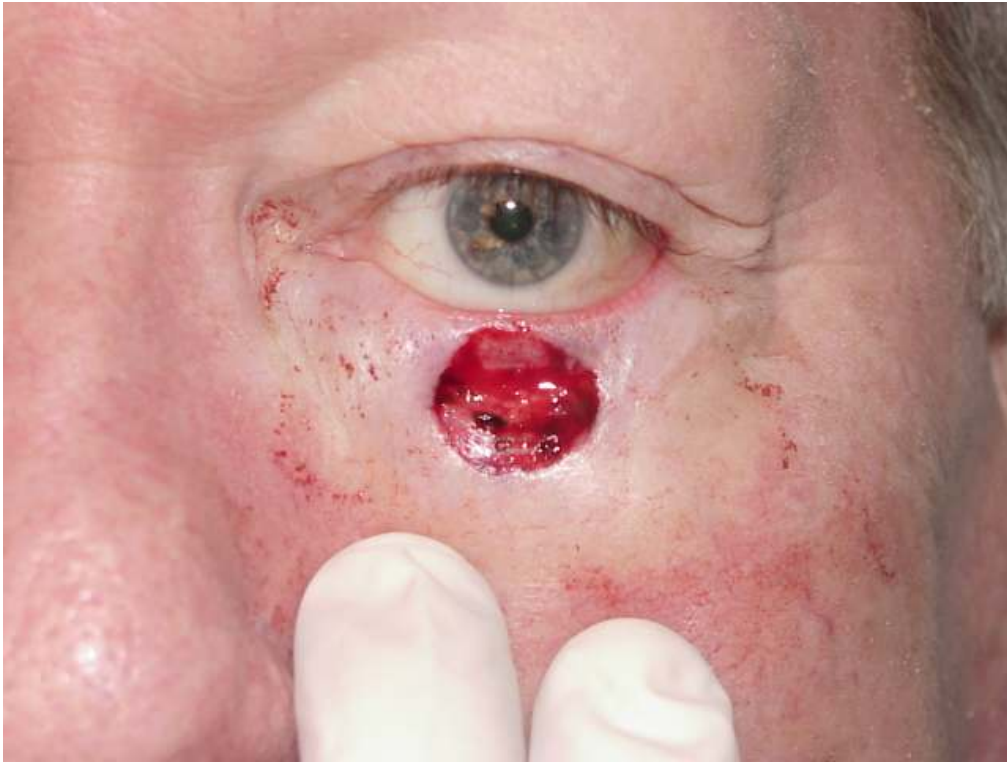

# The Periorbital Region

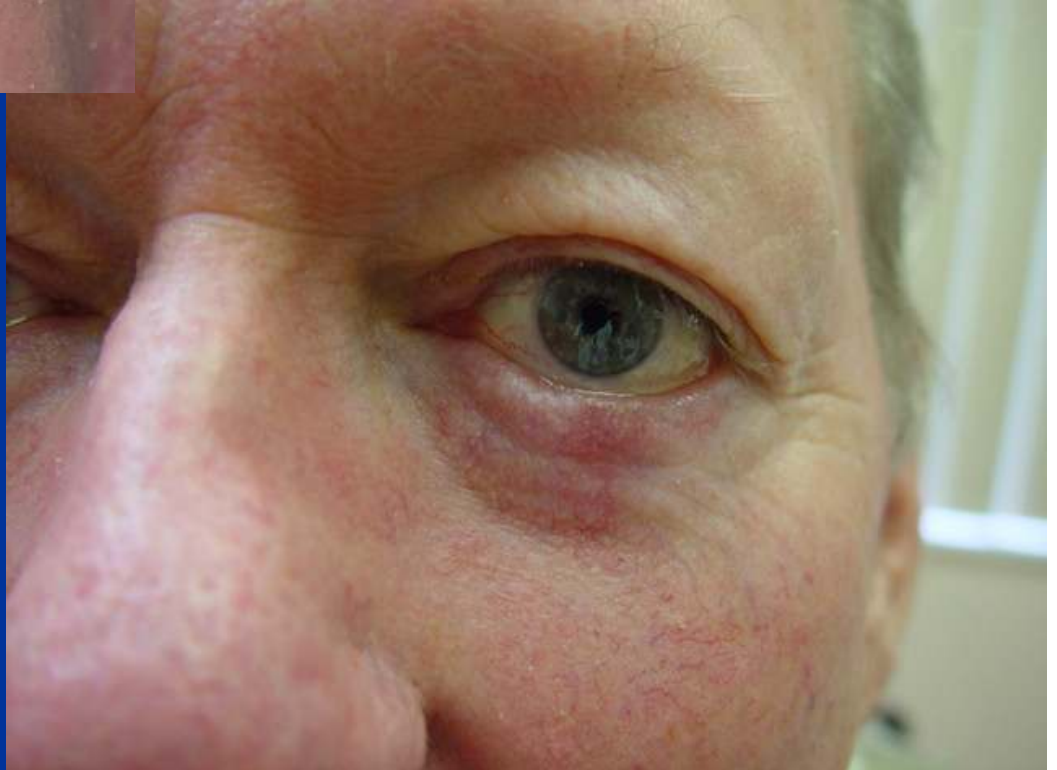Greg S. Morganroth, MD

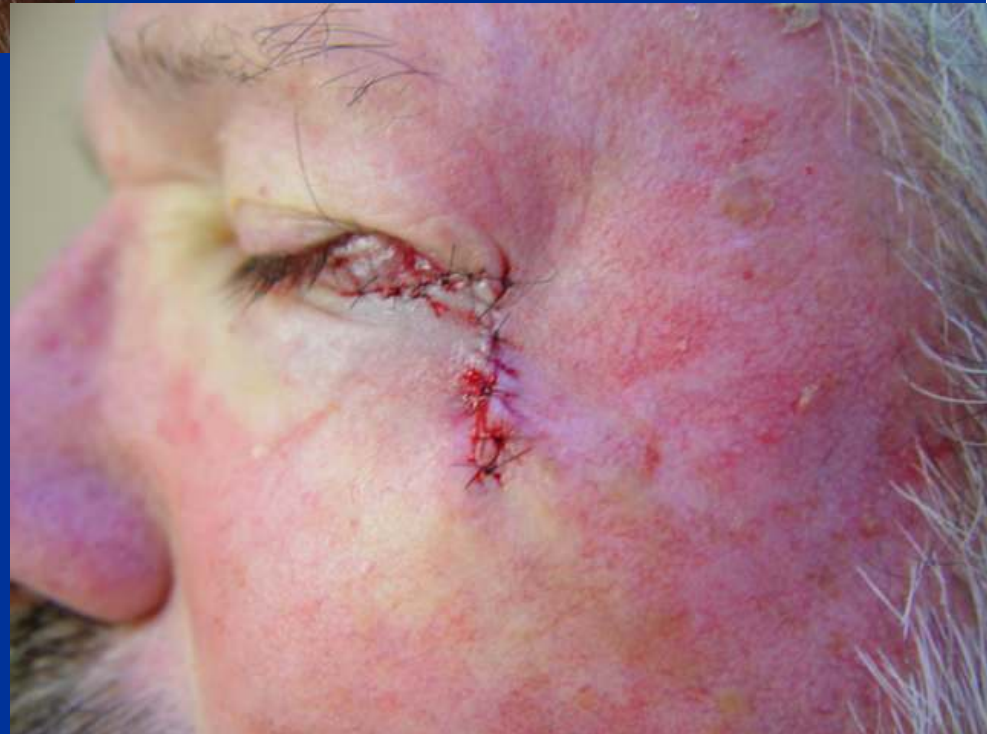
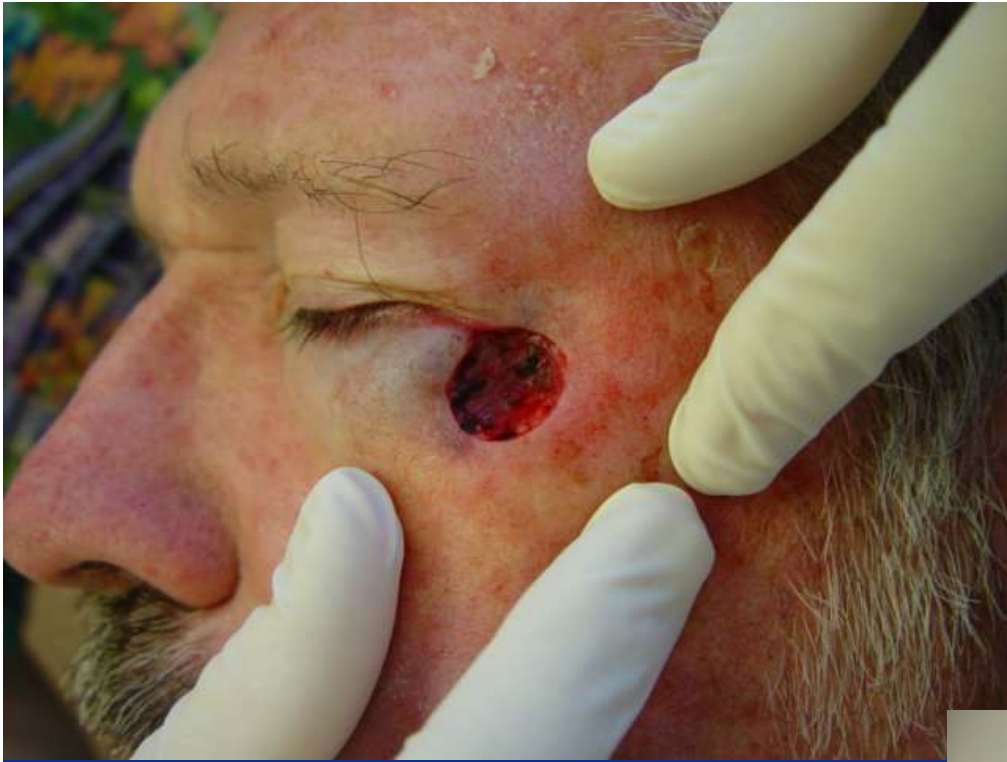


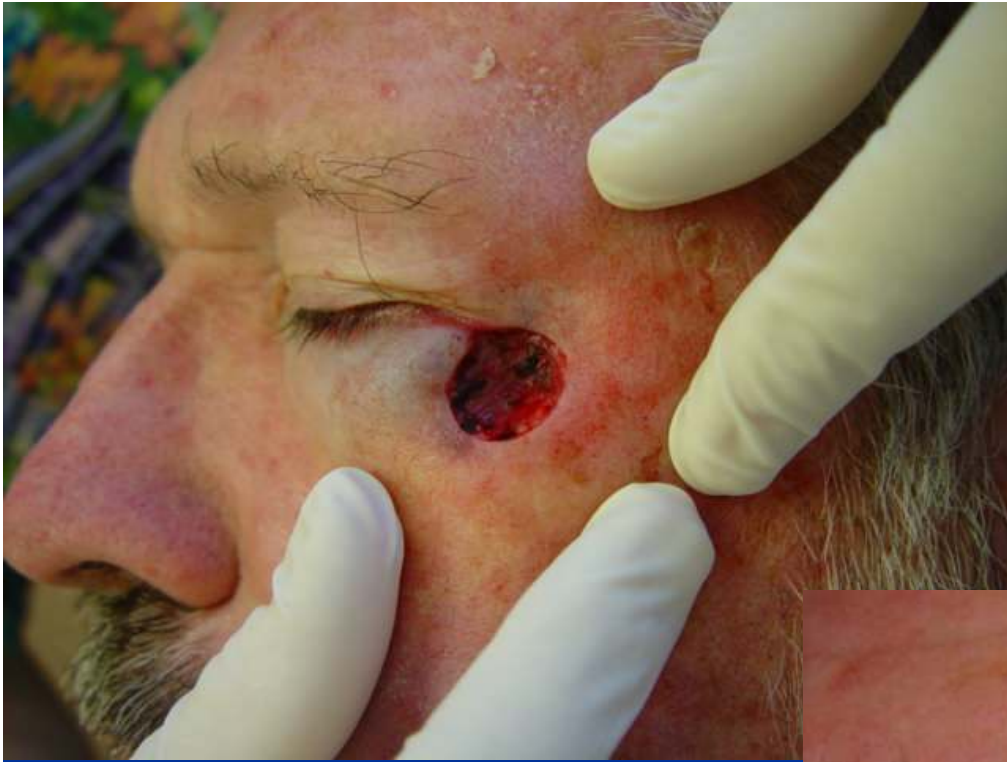

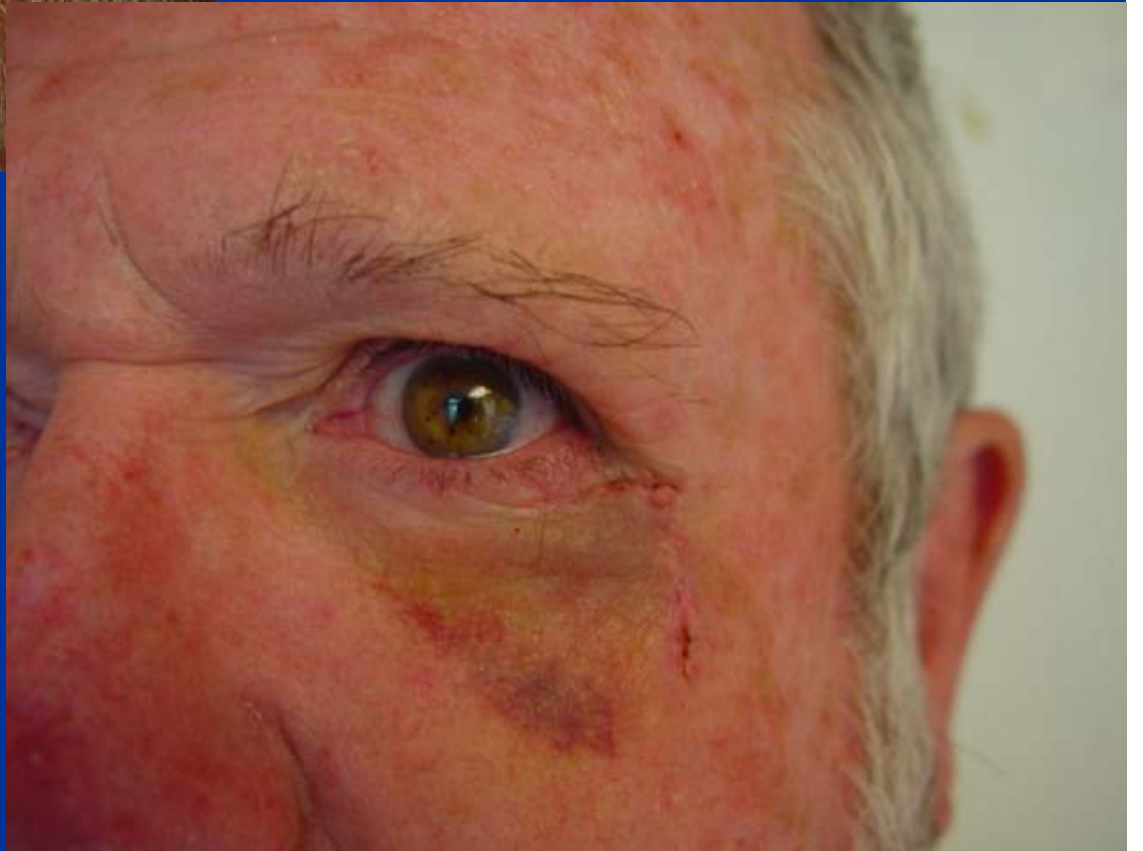One month later

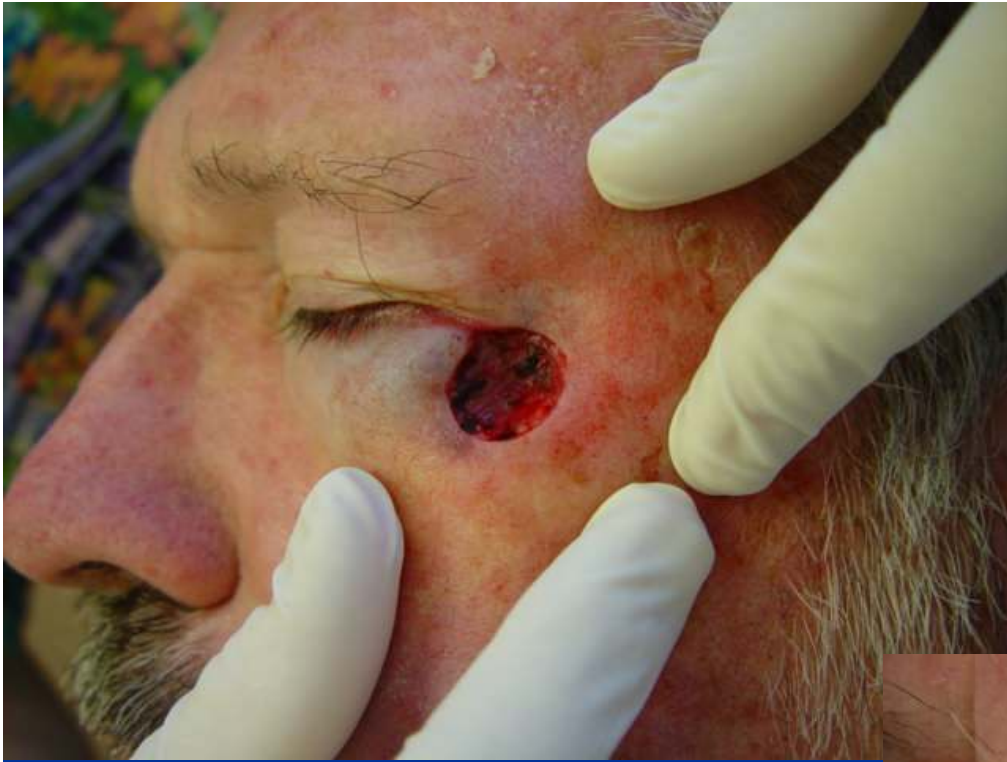




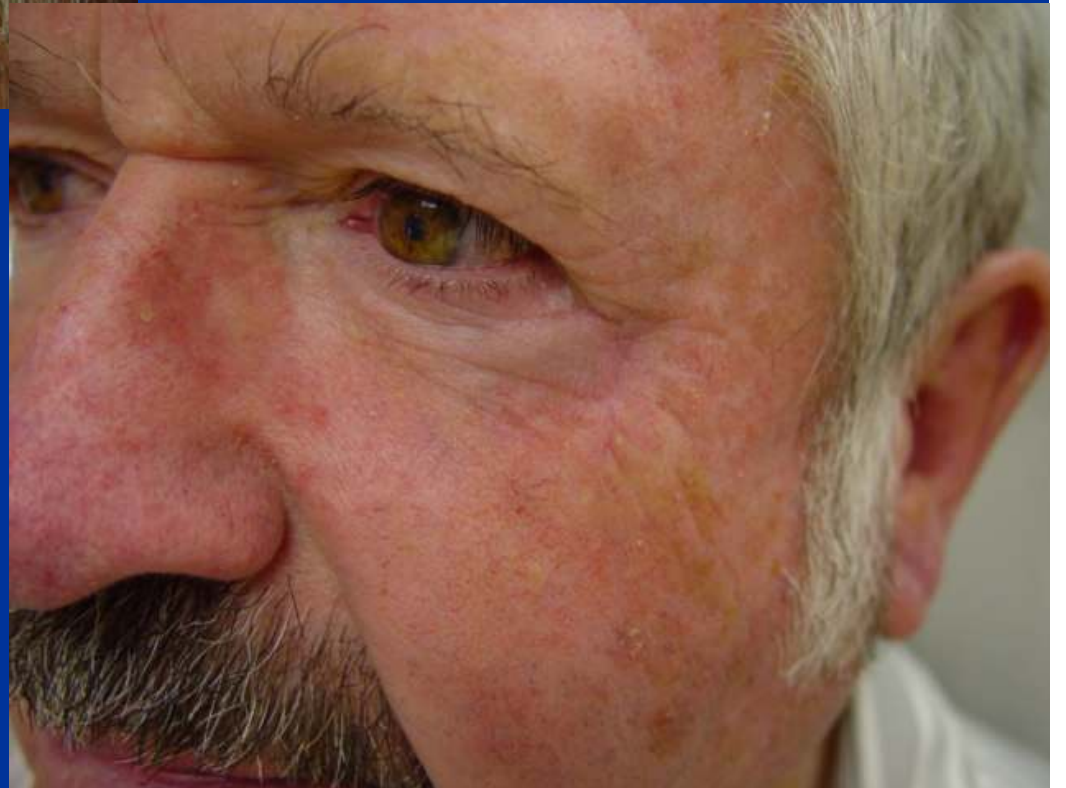
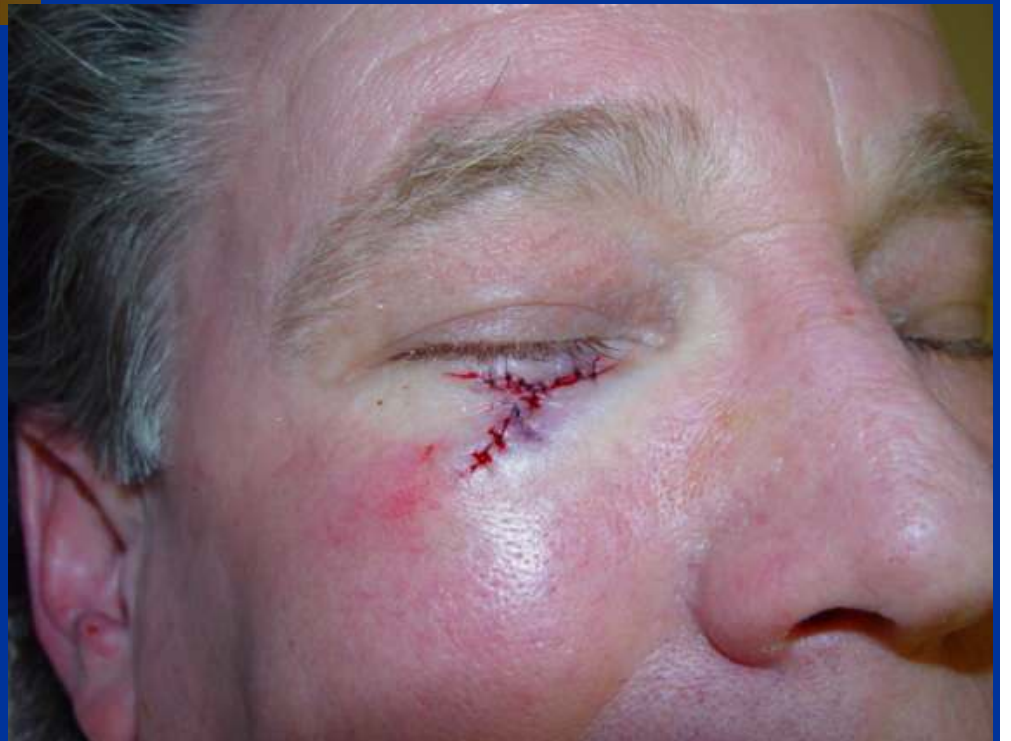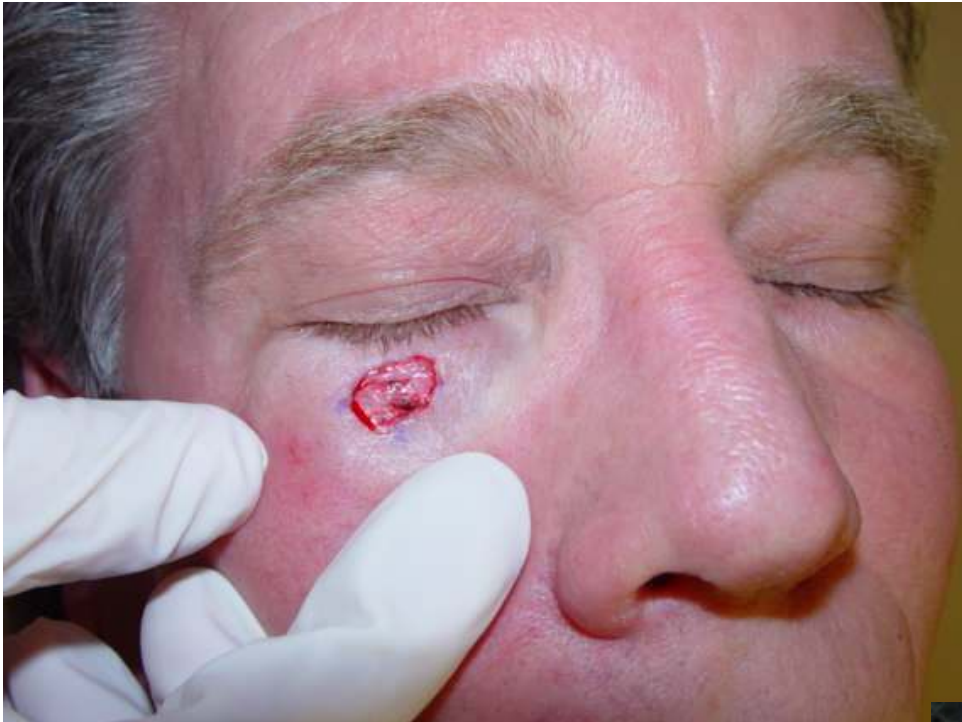**One week later**

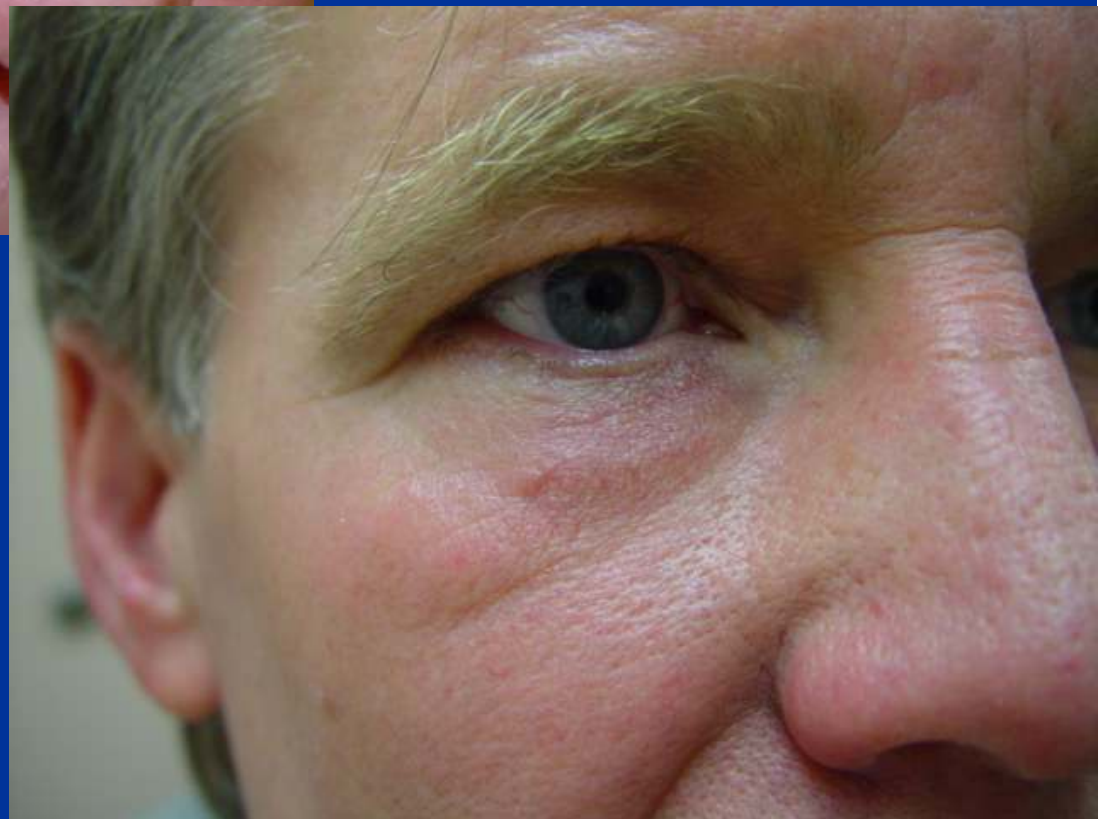
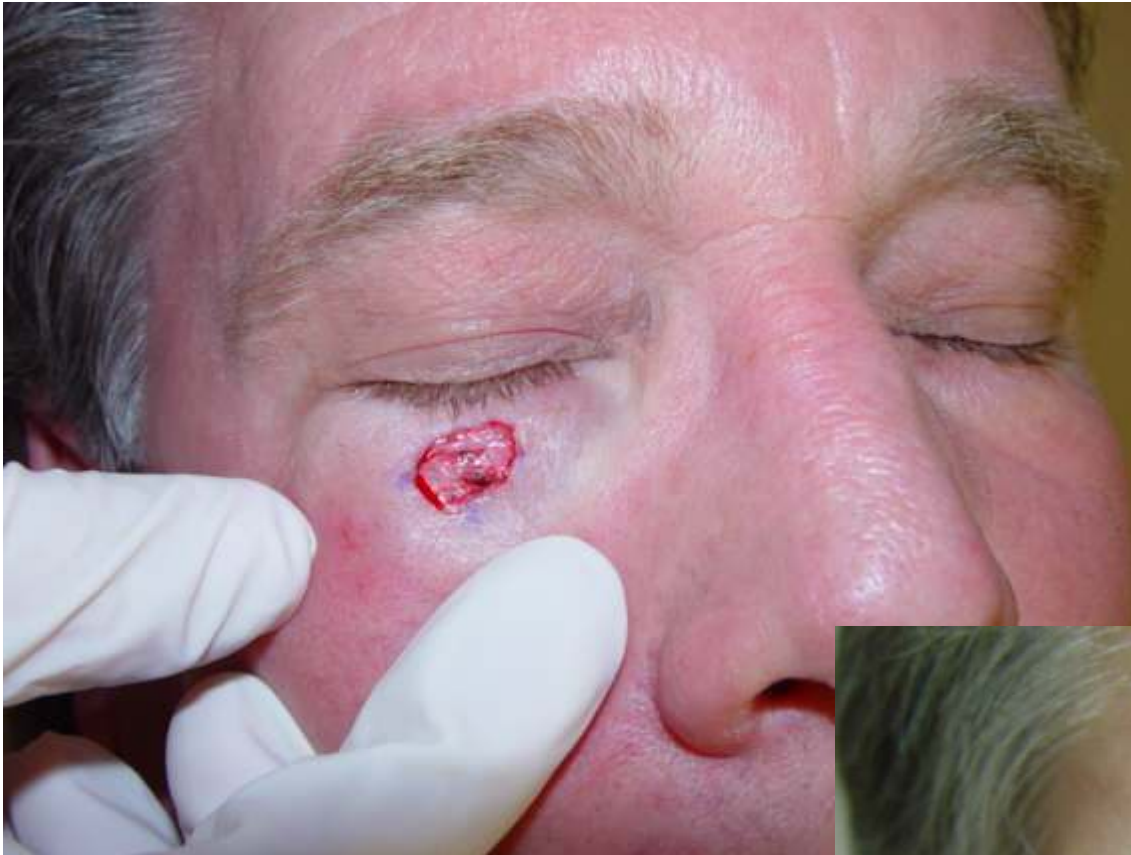


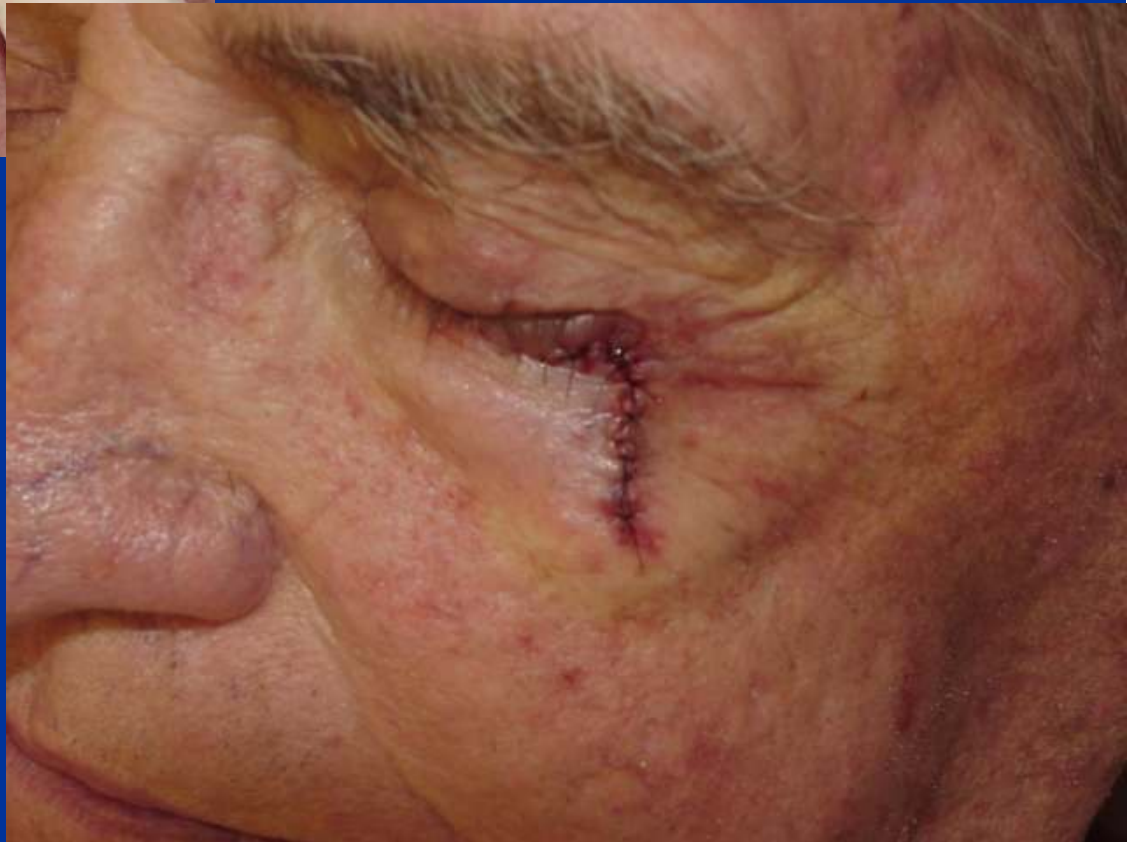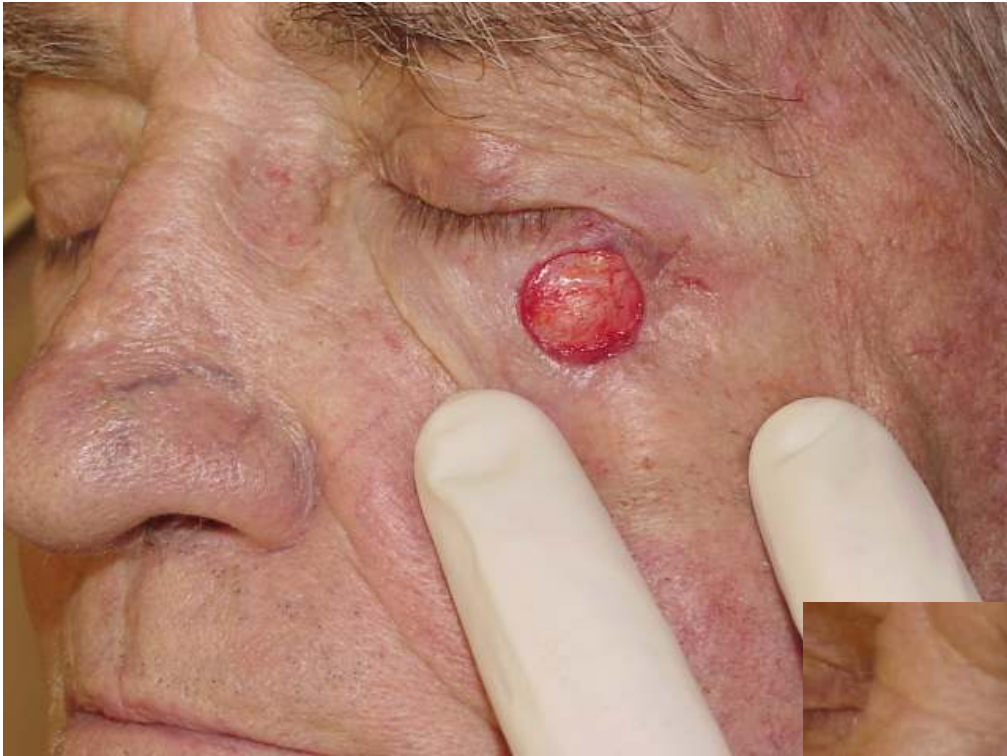**2 months later**

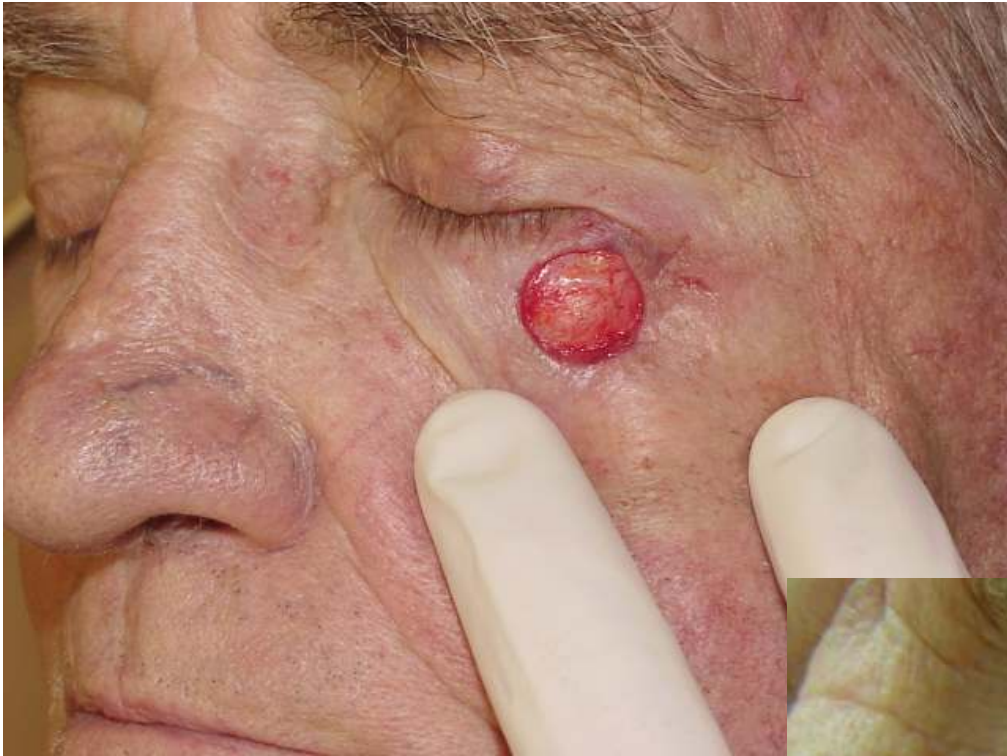




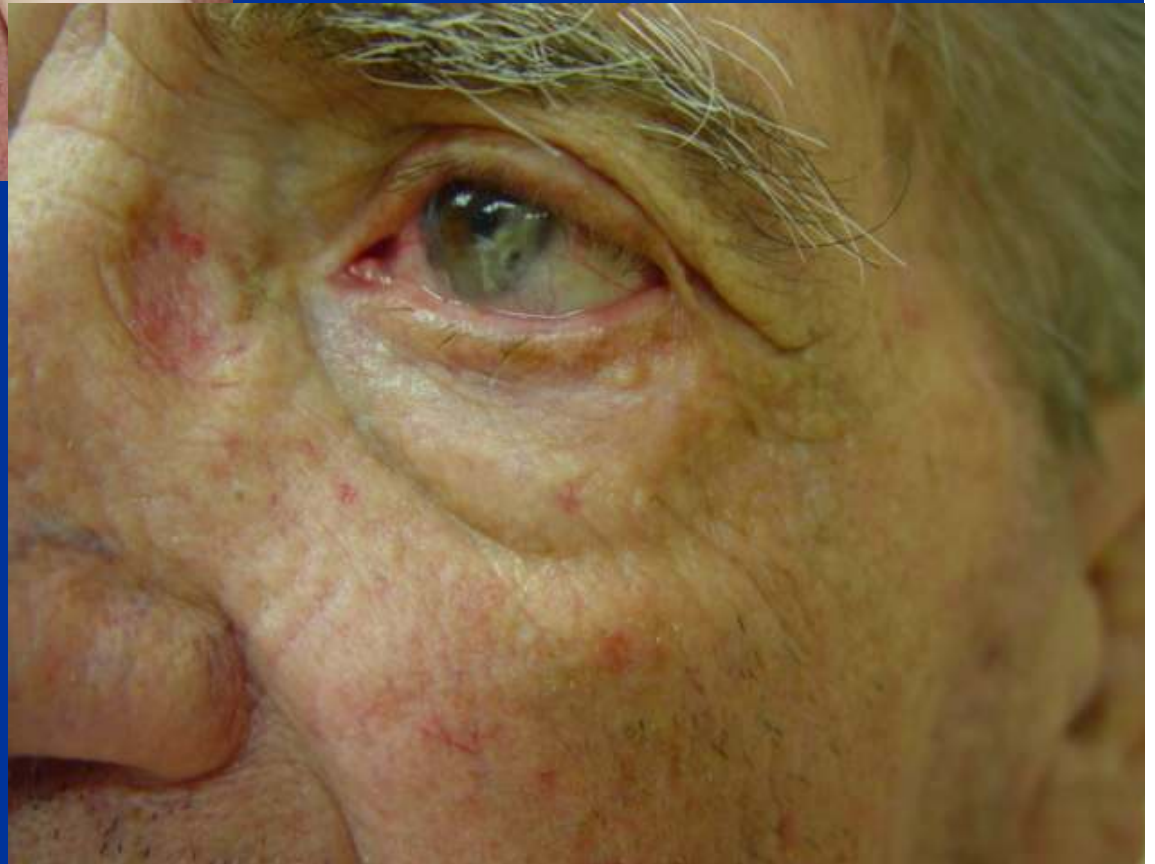
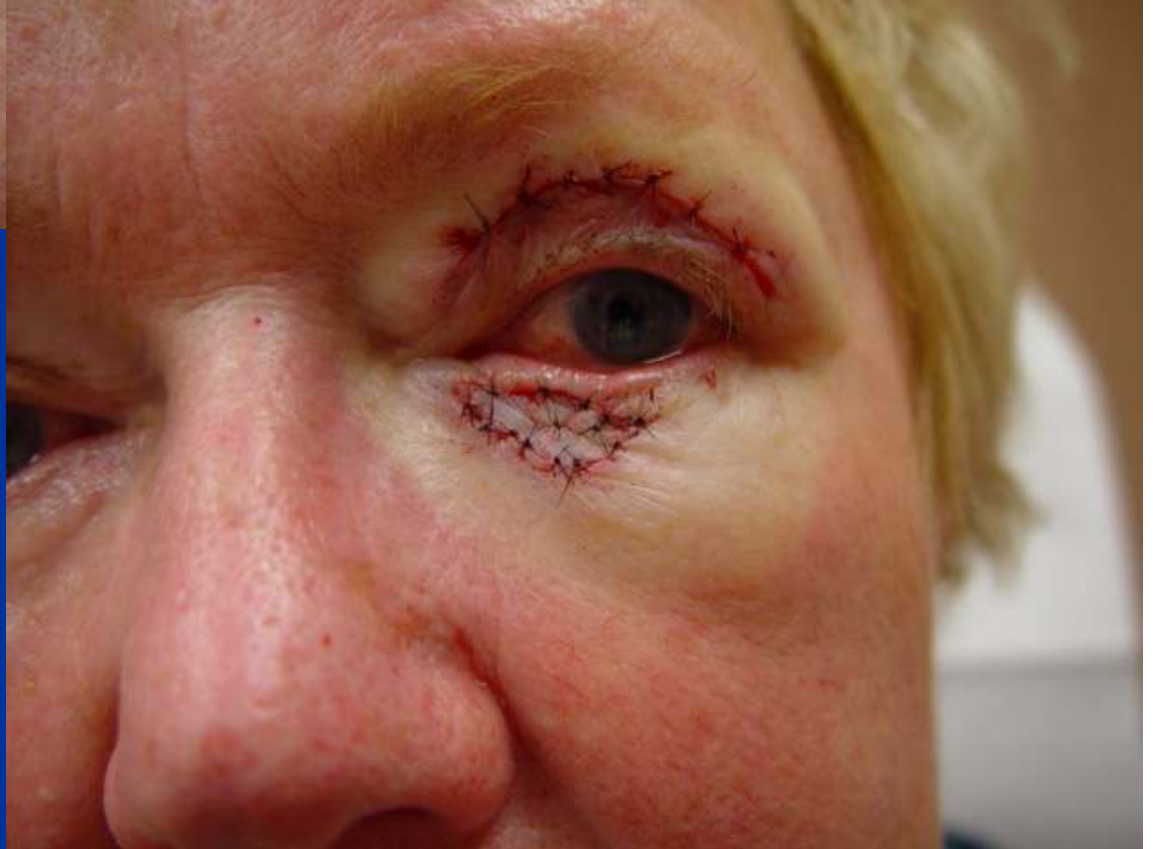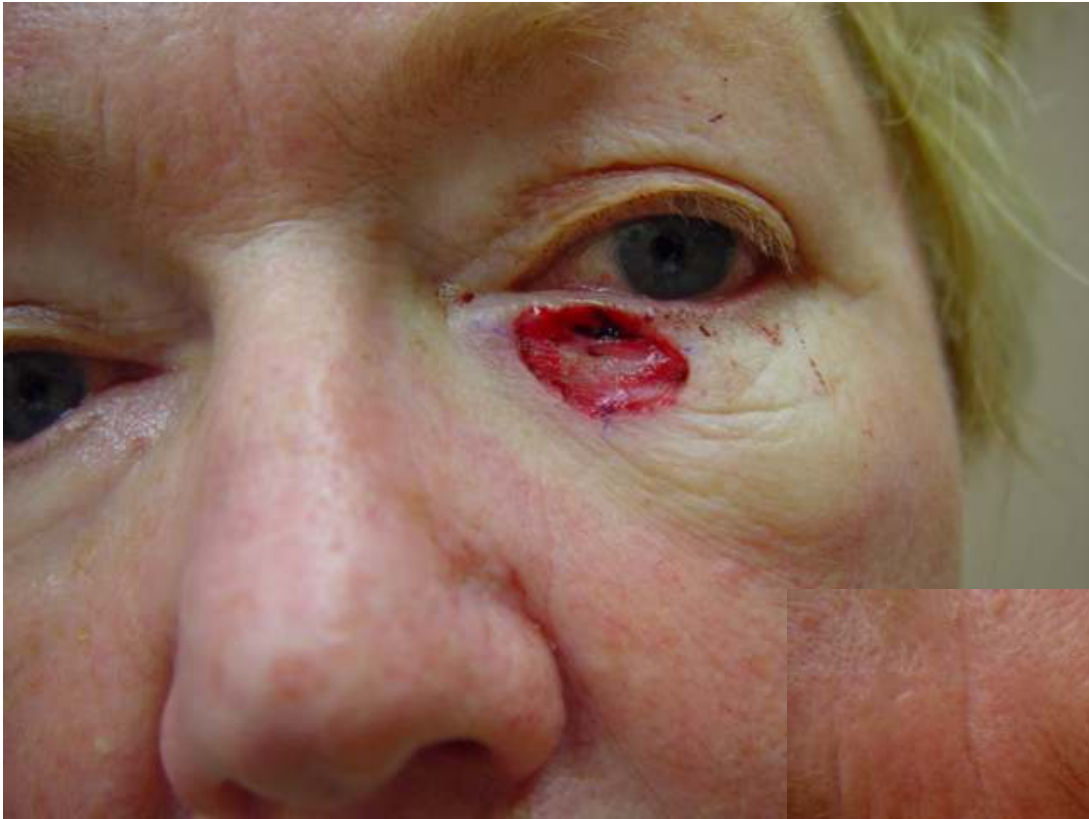**6 weeks later**



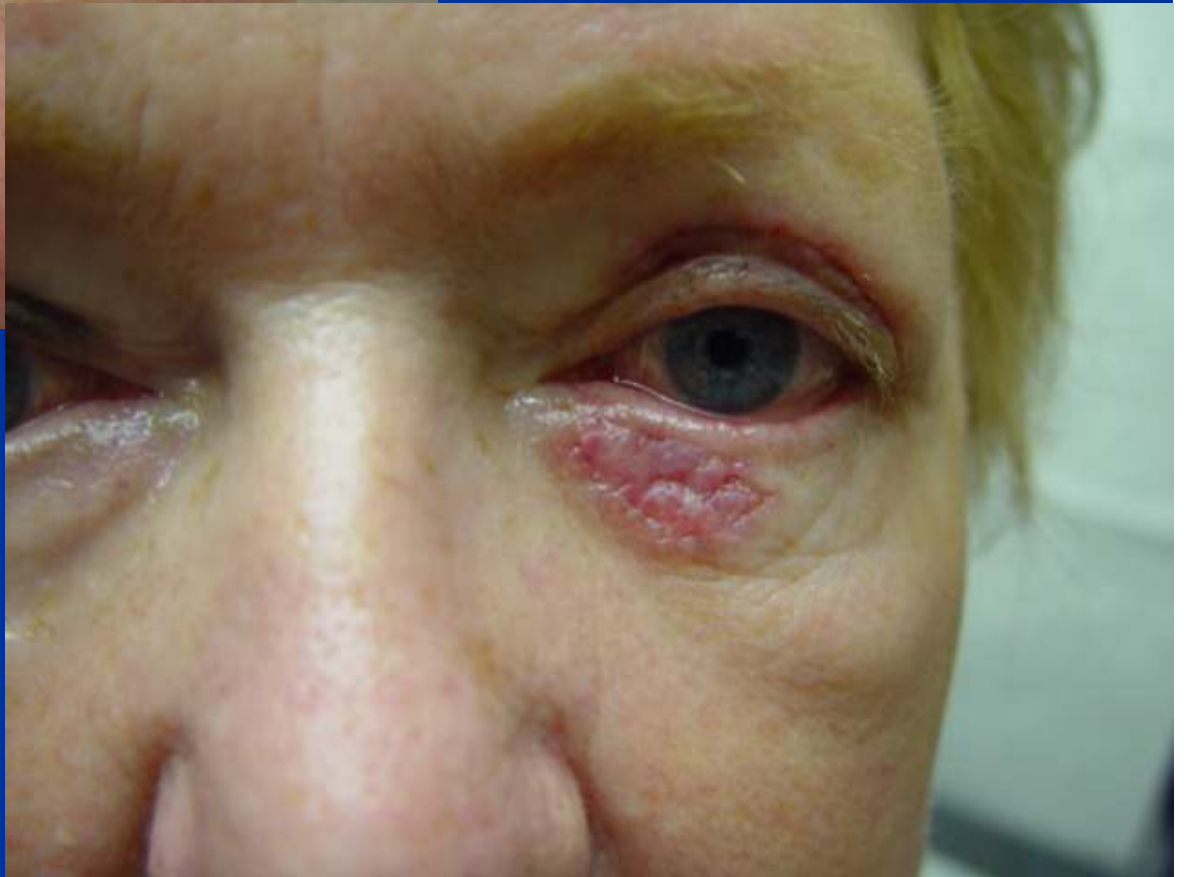
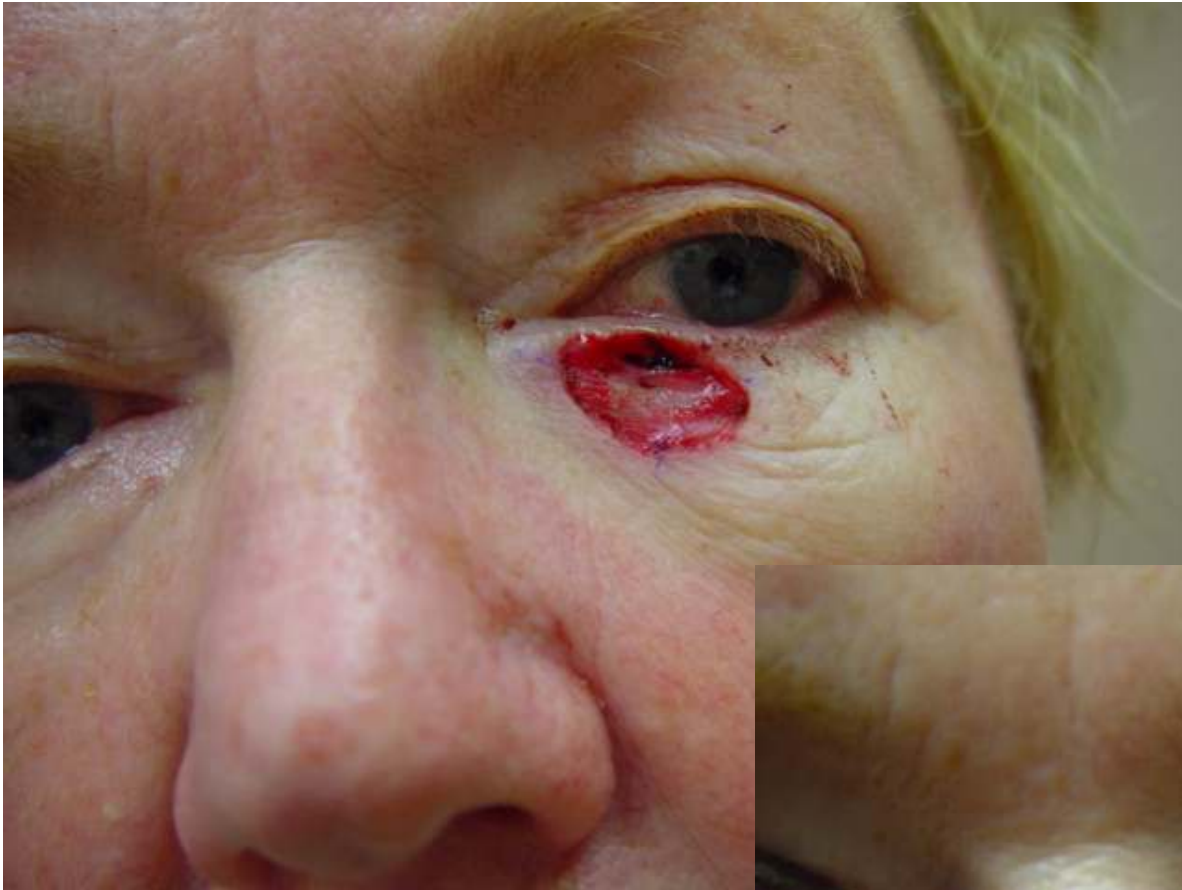
**5 months later**

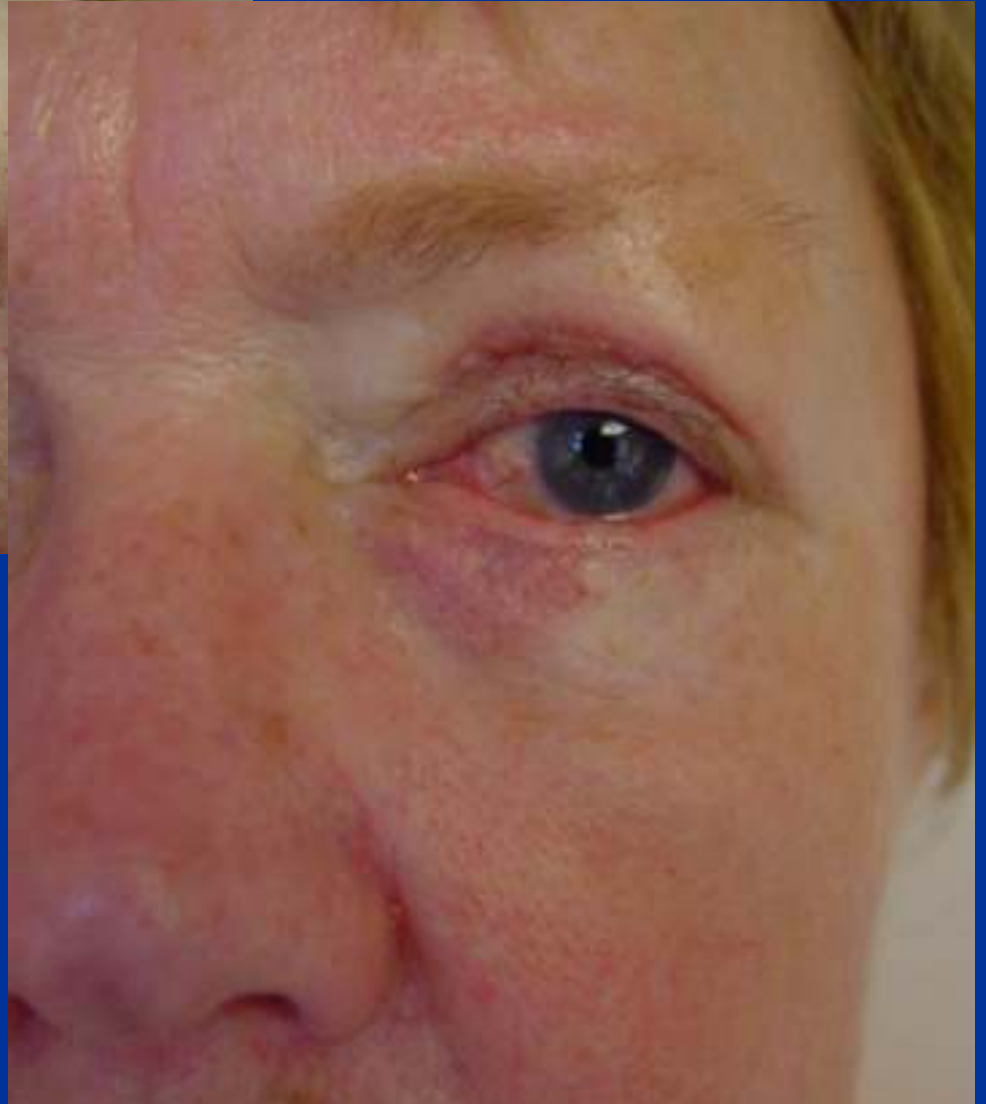
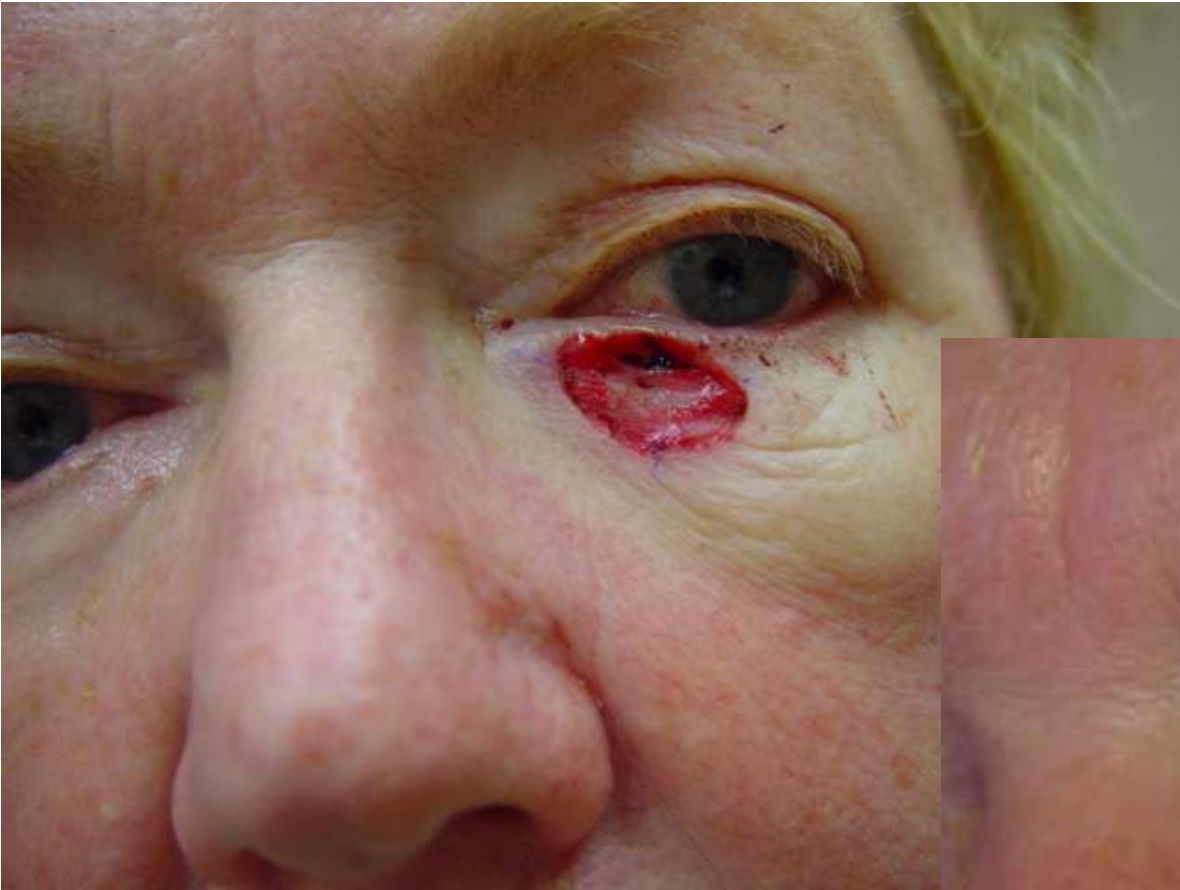


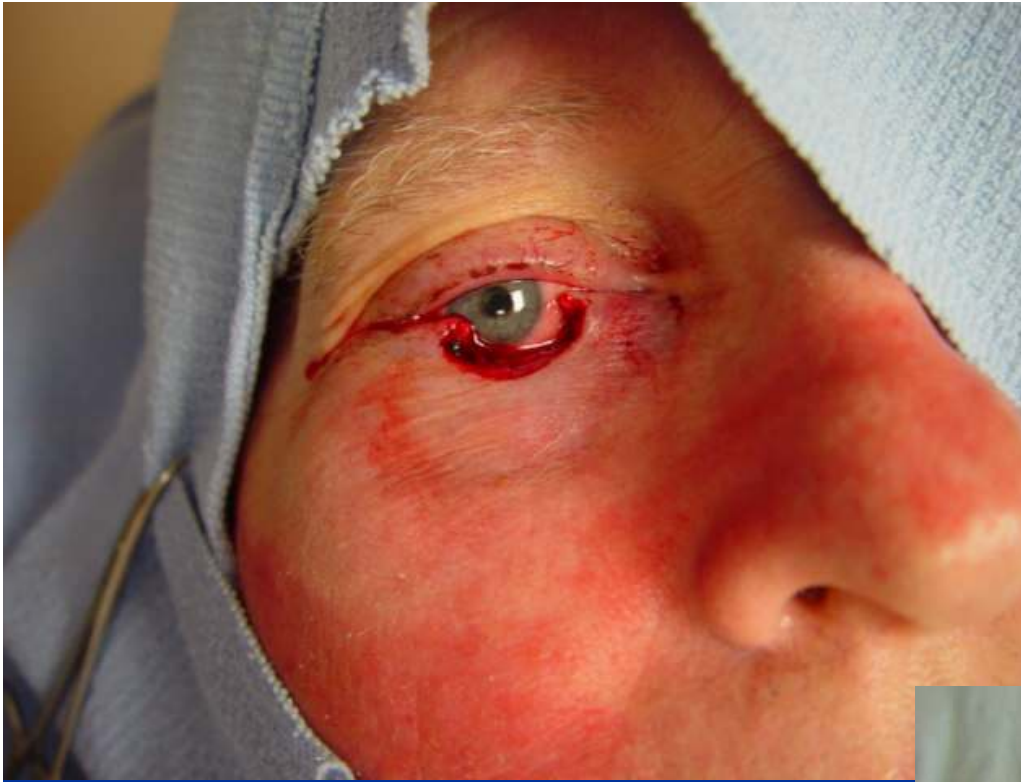One week later



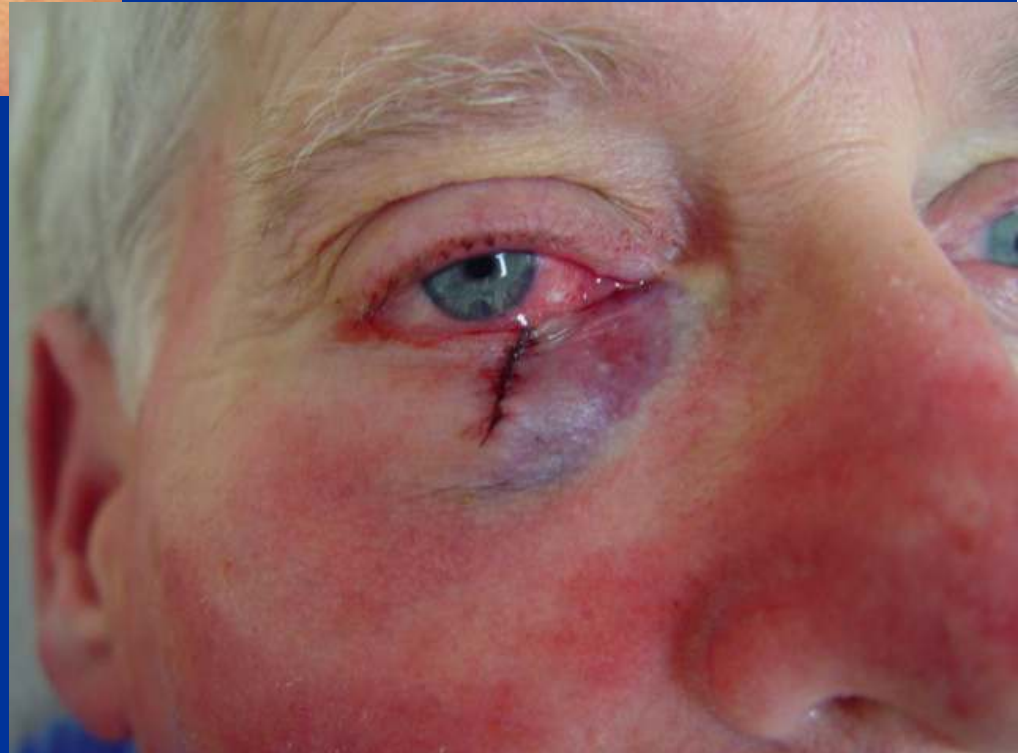10 days later

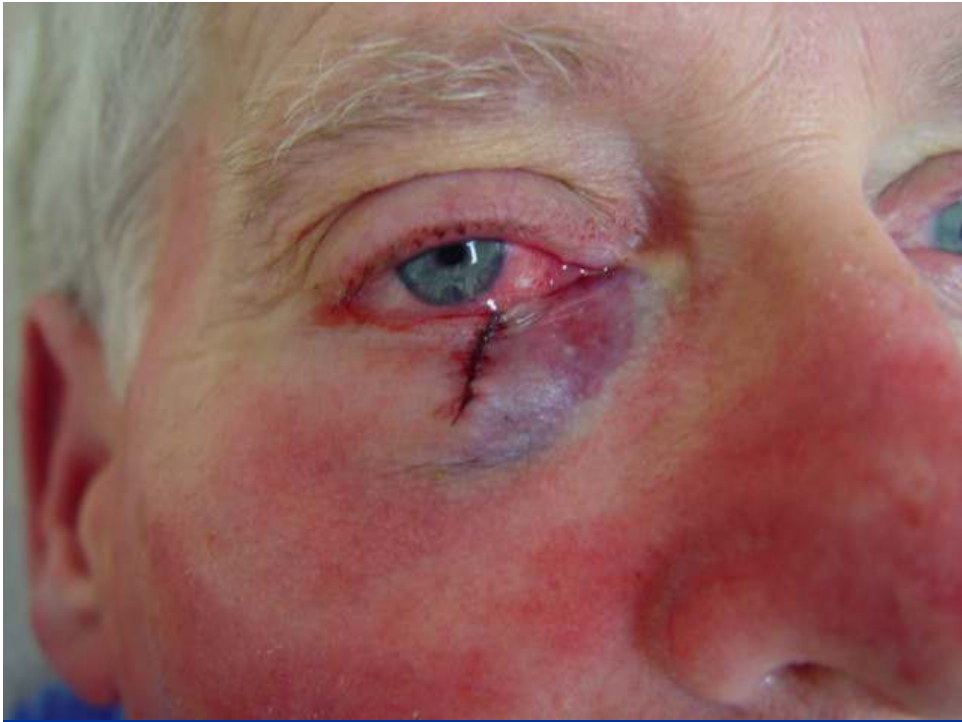



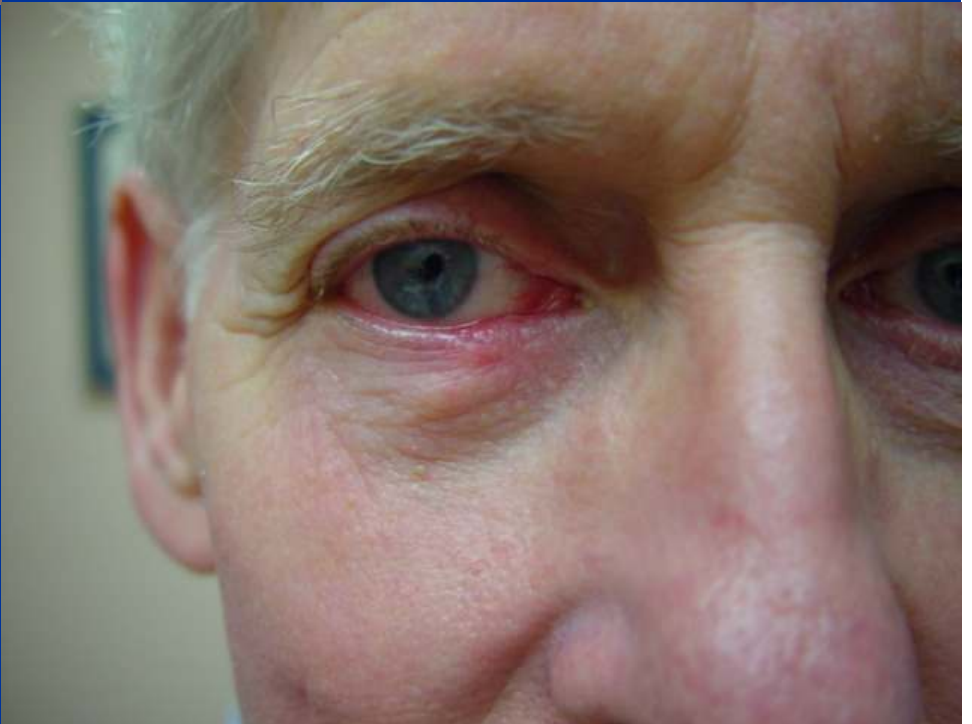## Pentagonal Wedge Excision

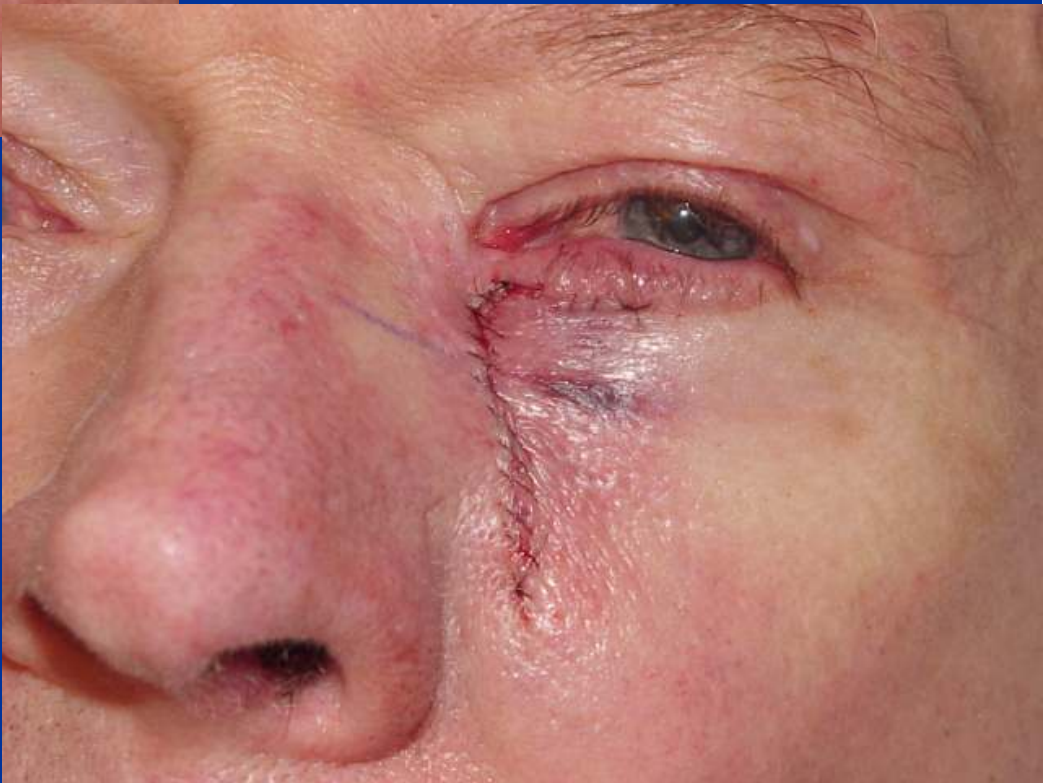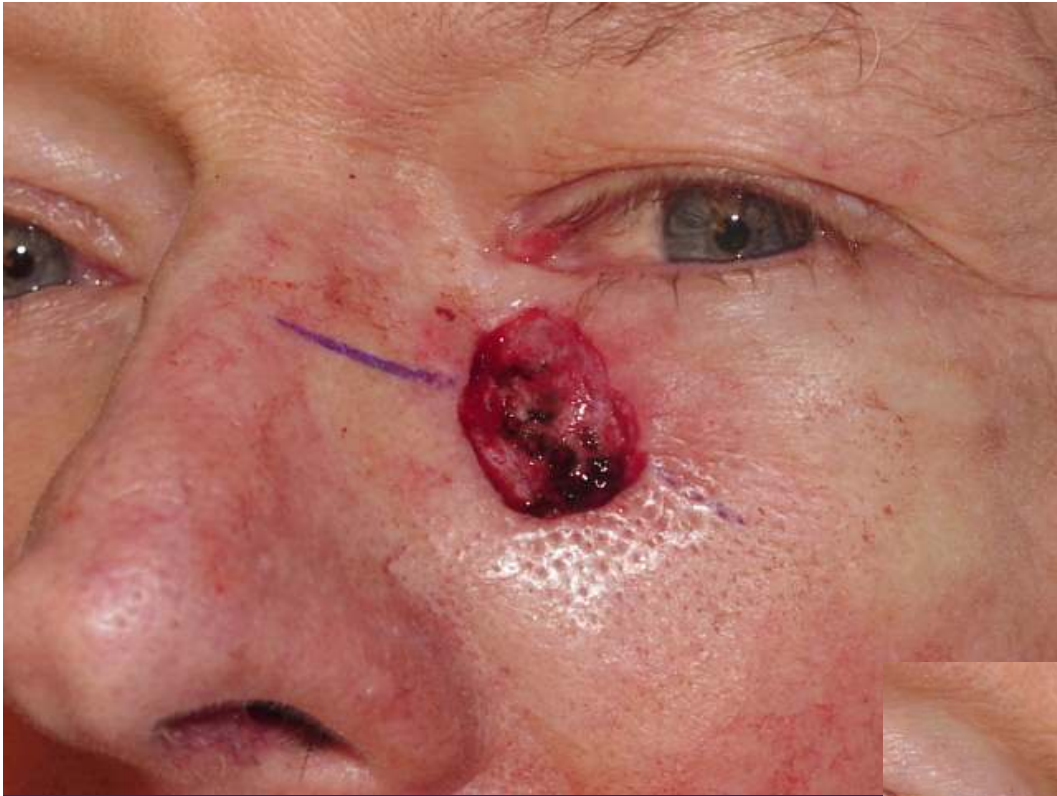Side to side closure

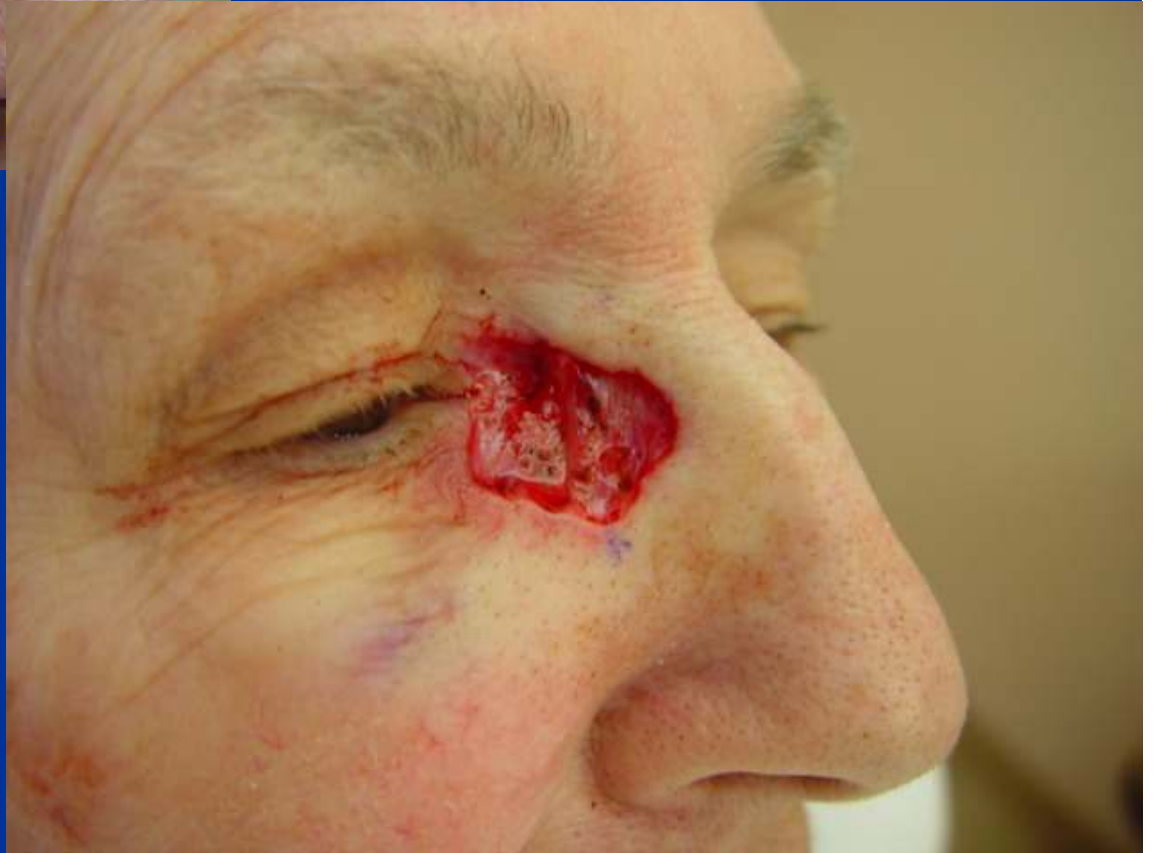
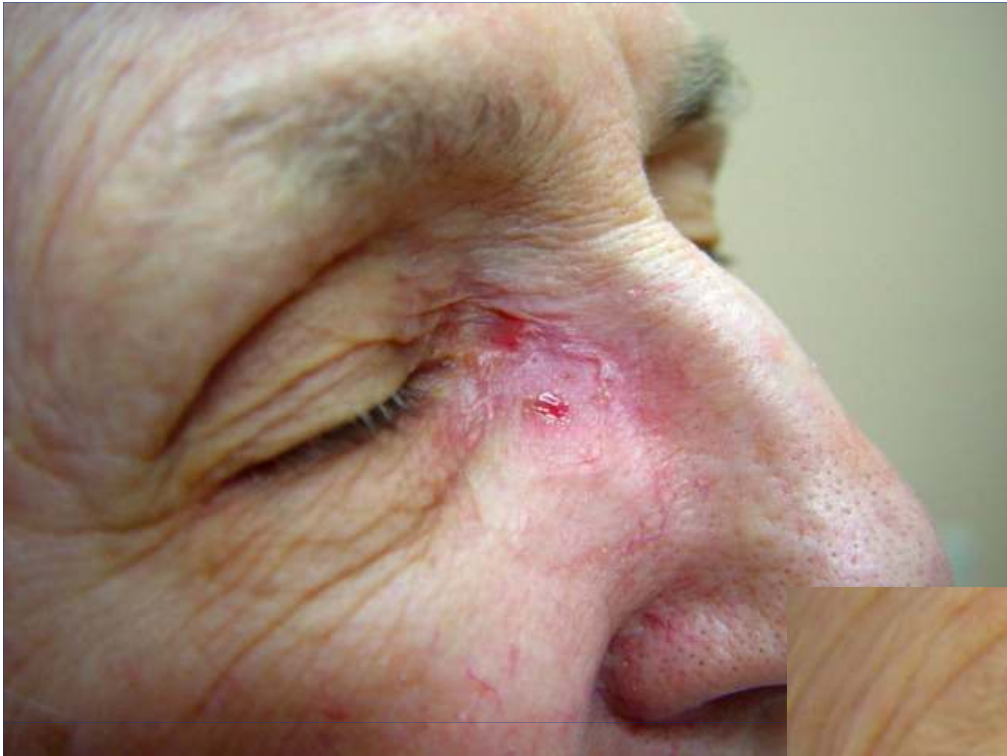


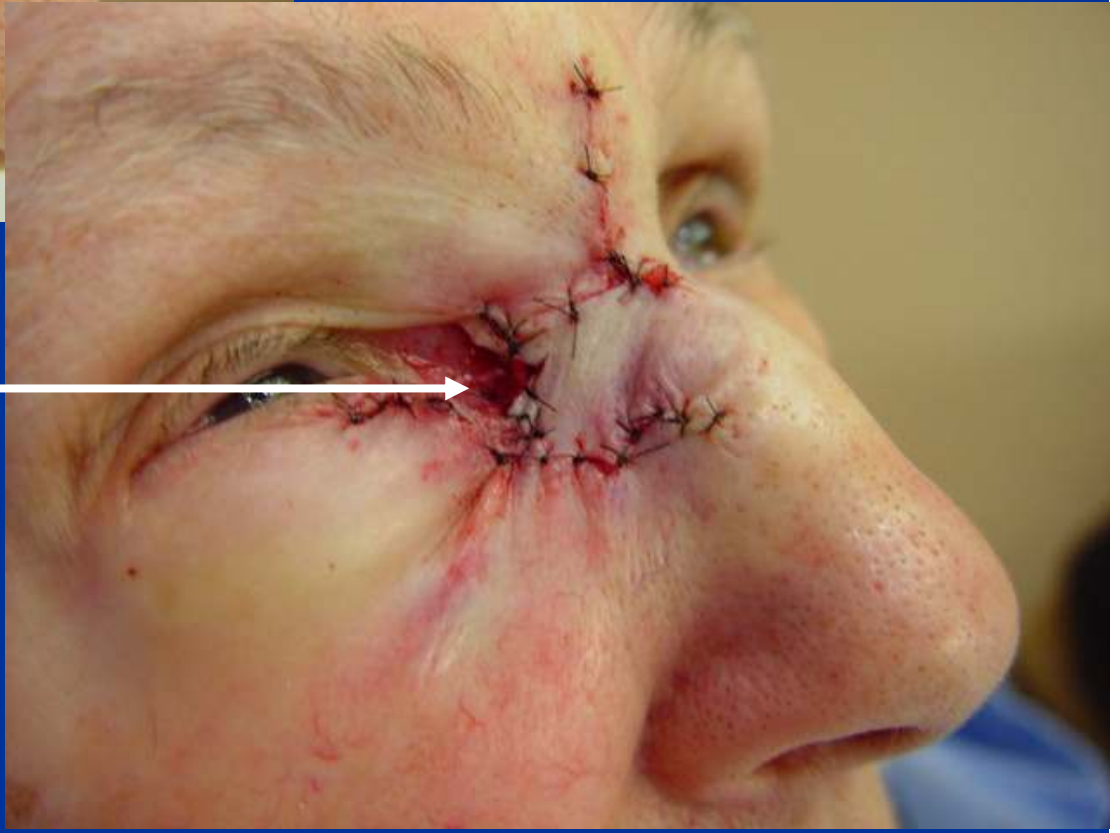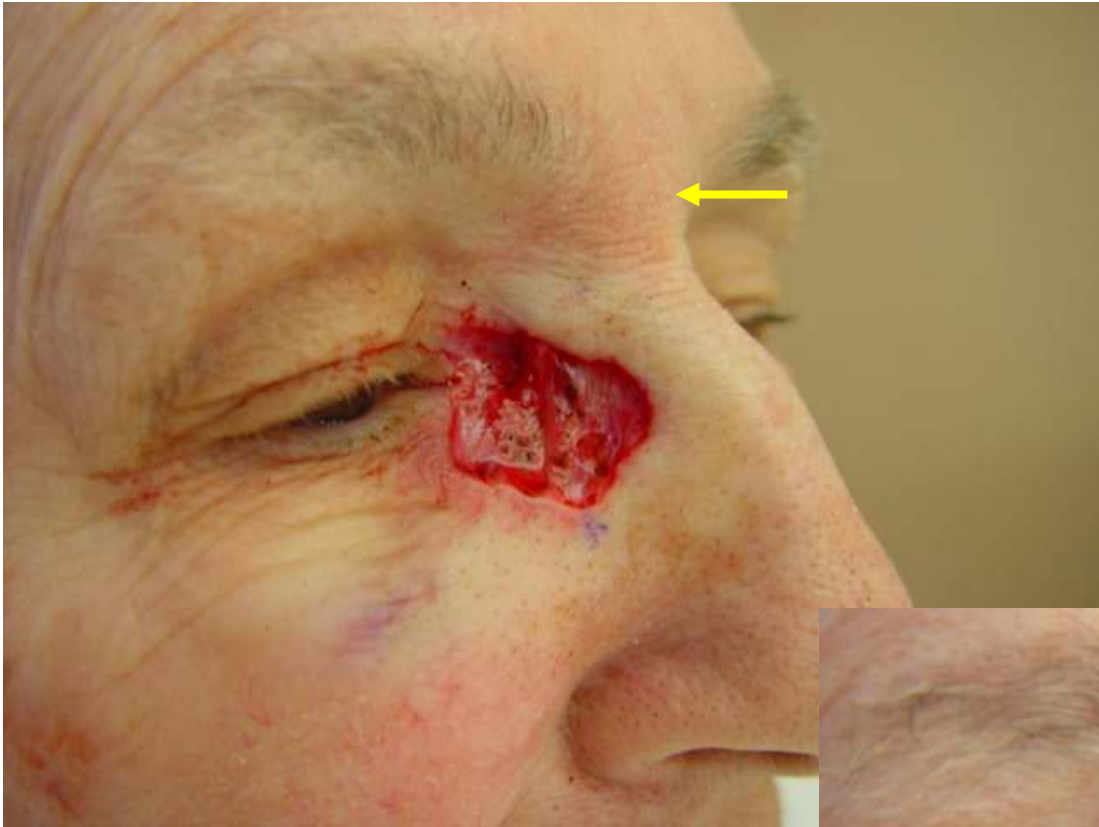3 weeks later

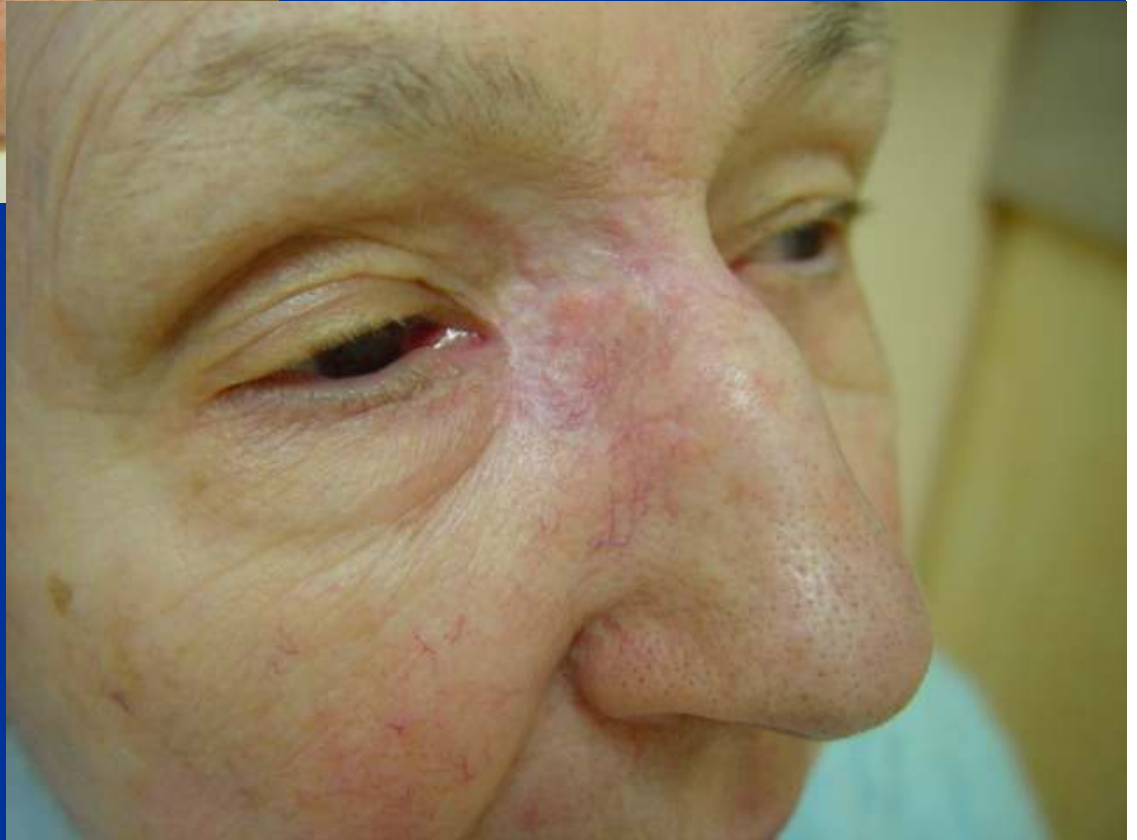
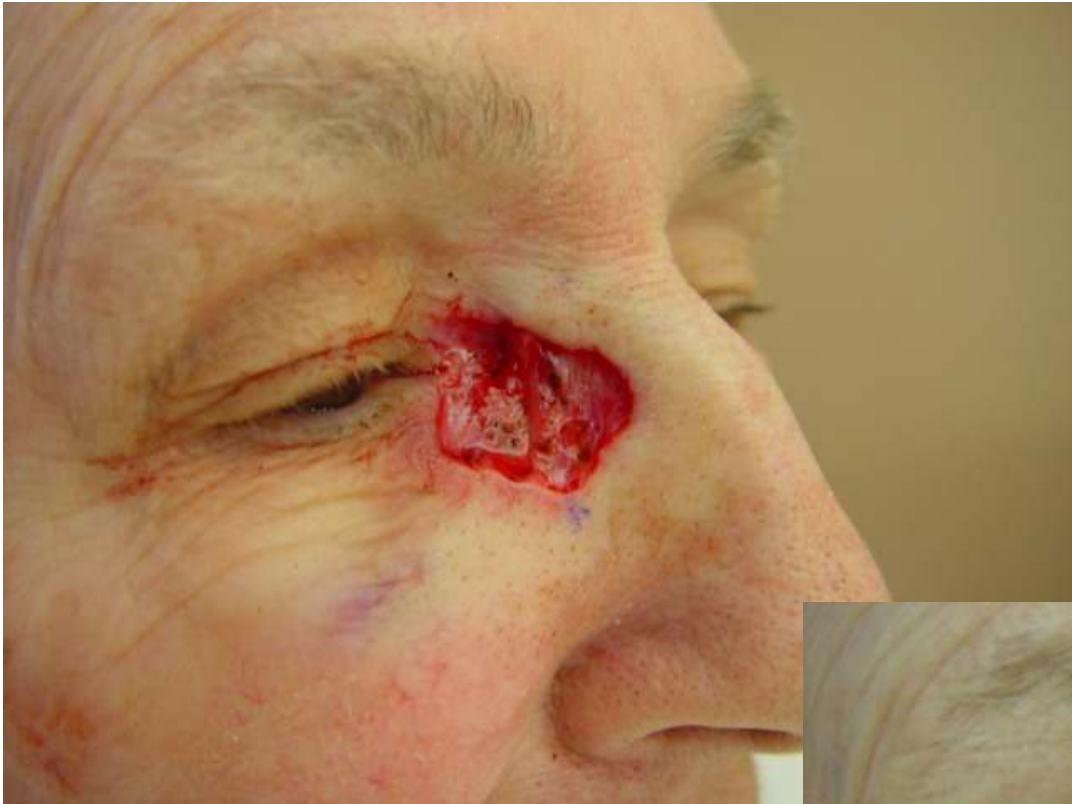




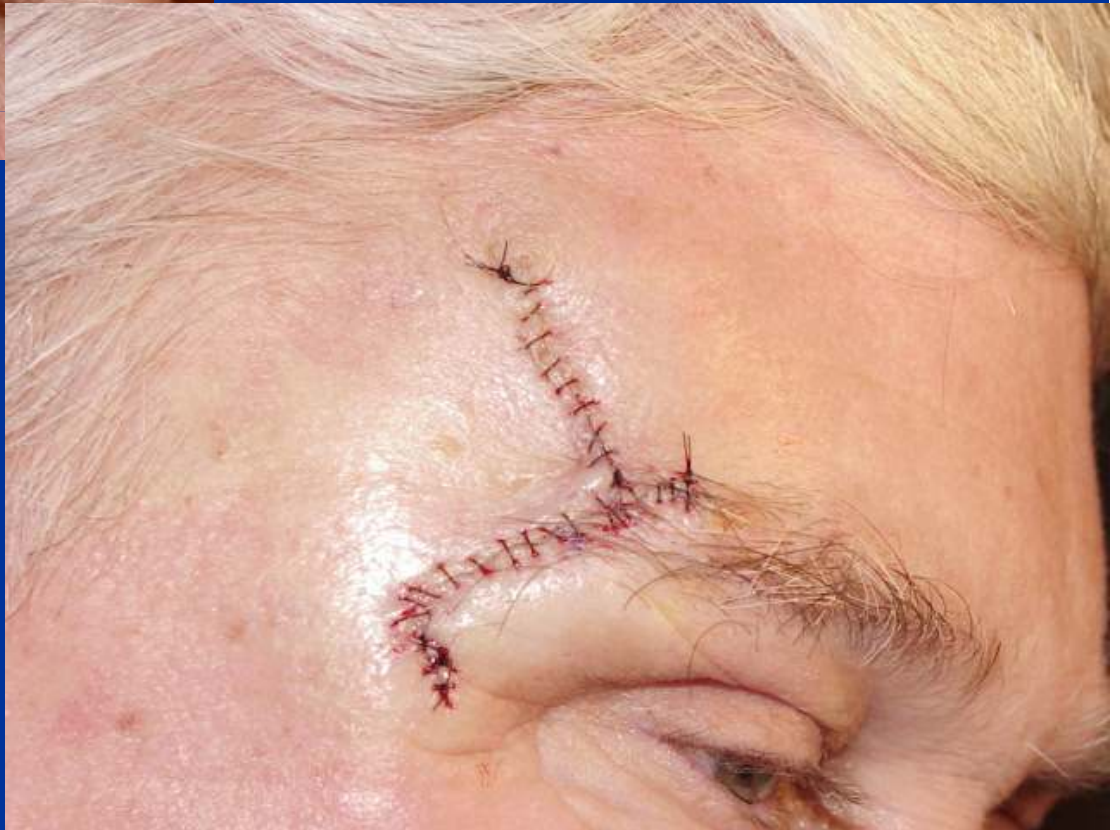
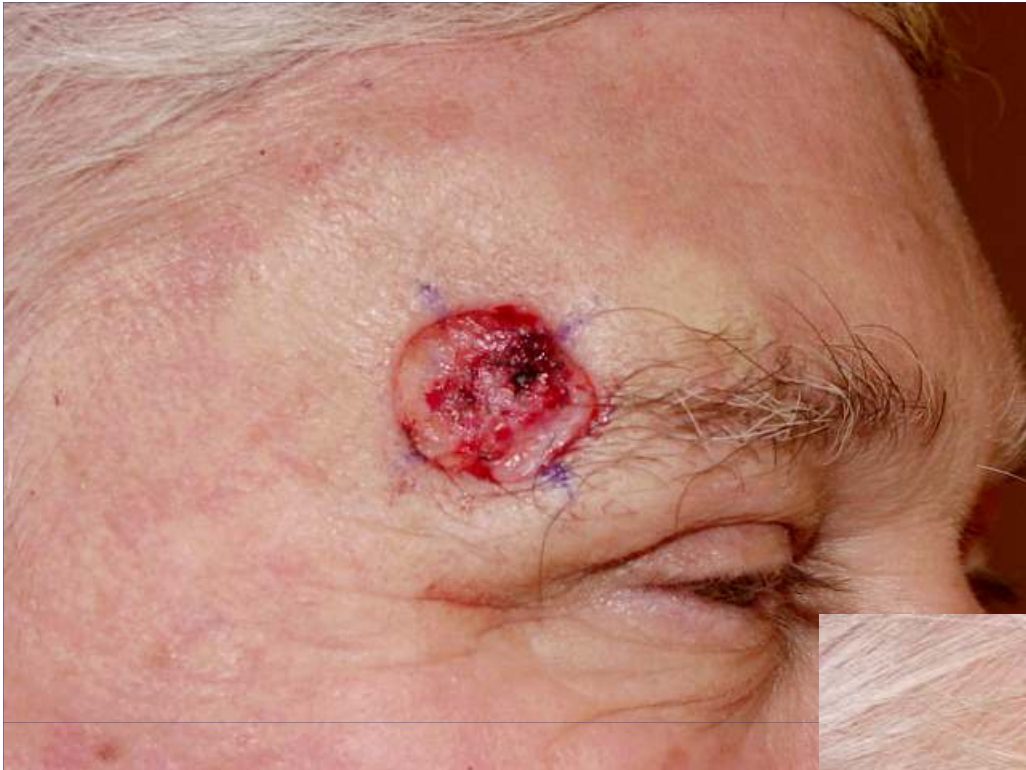
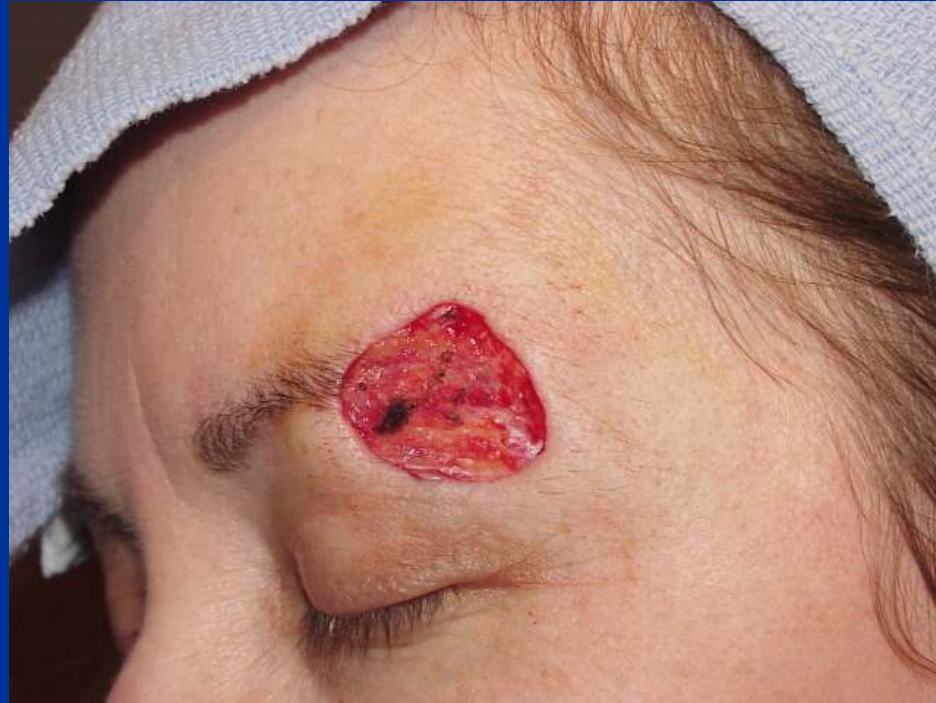**Allowed to granulate  
to create natural  
contour**

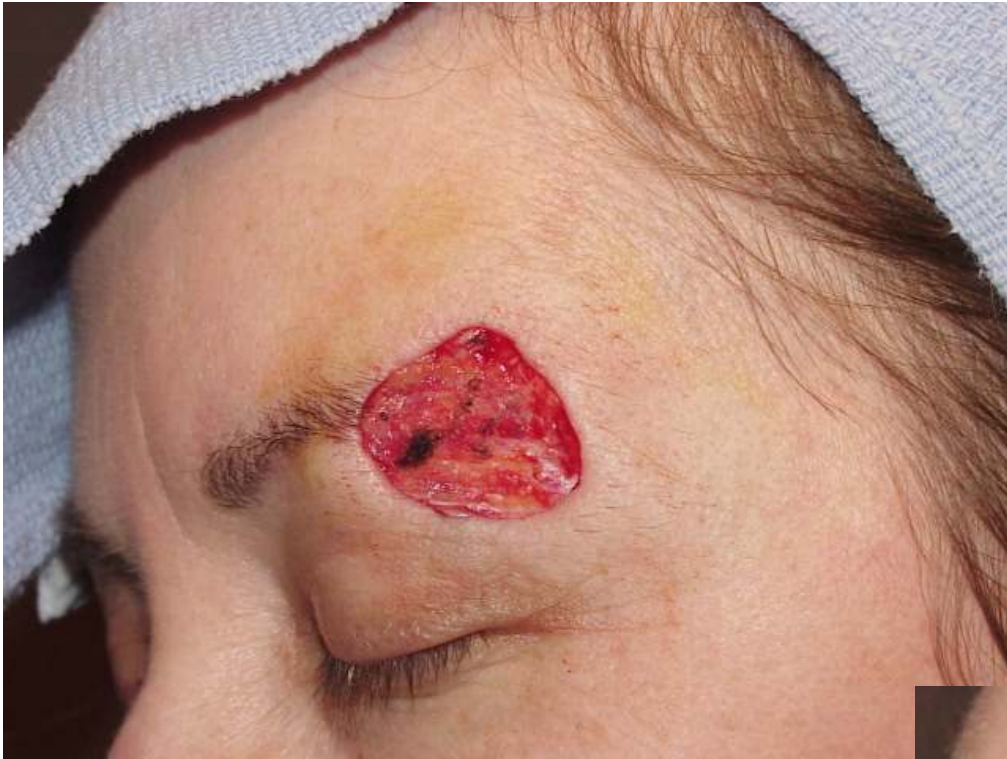

**6 months later**

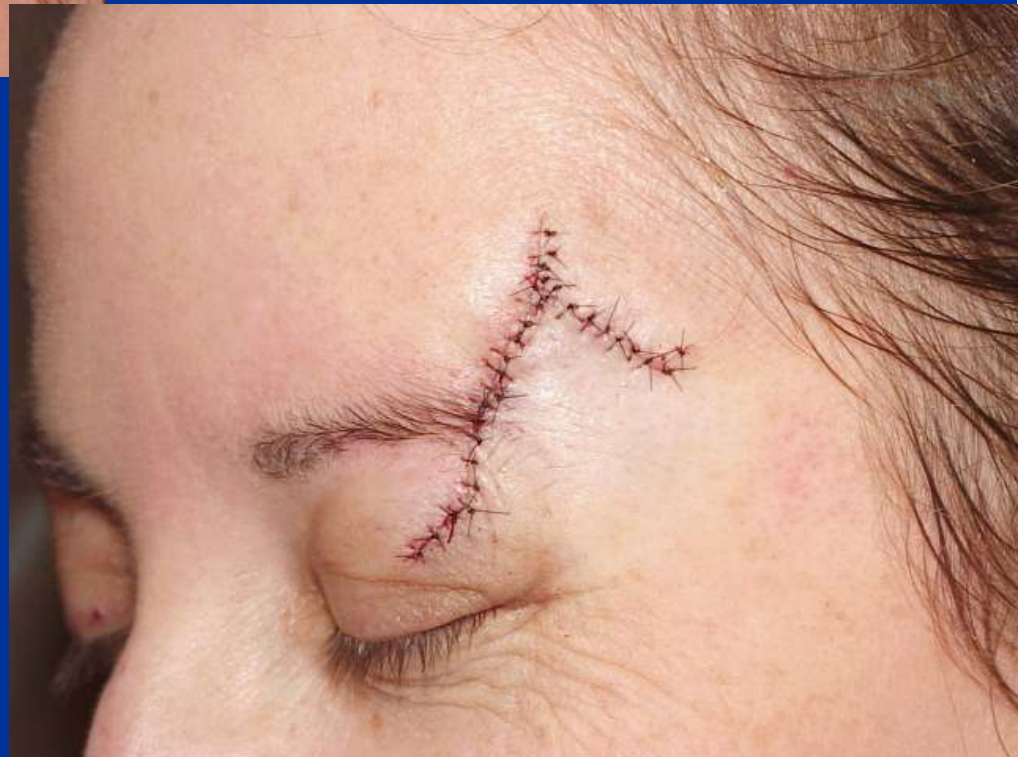


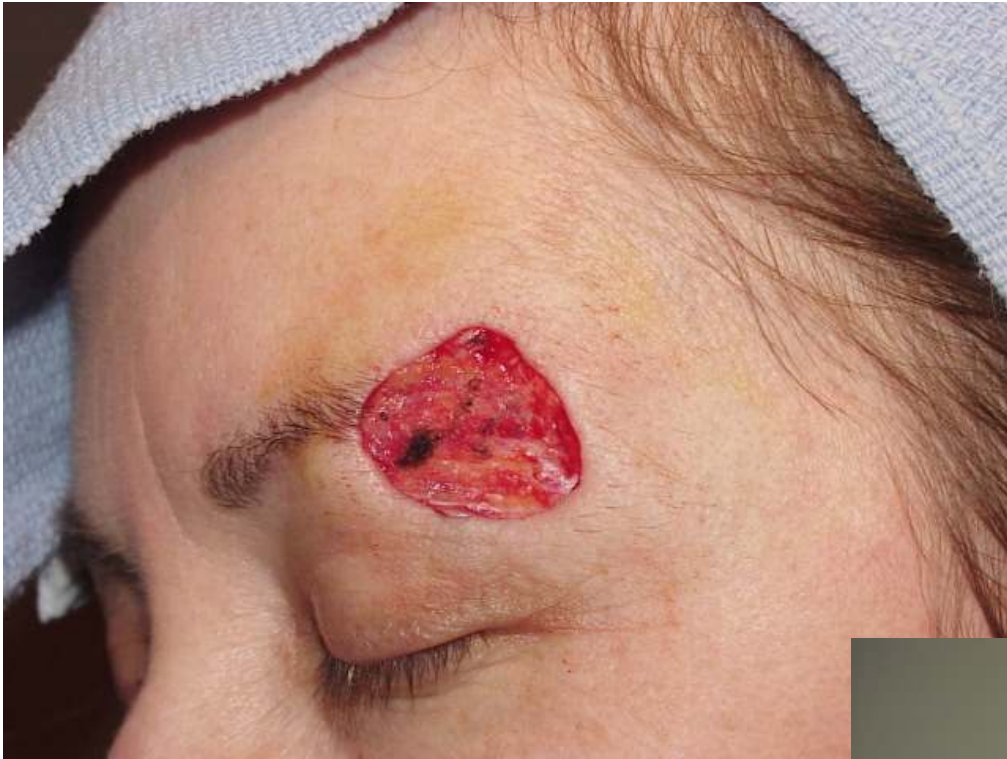
Options: Flap, graft, granulation

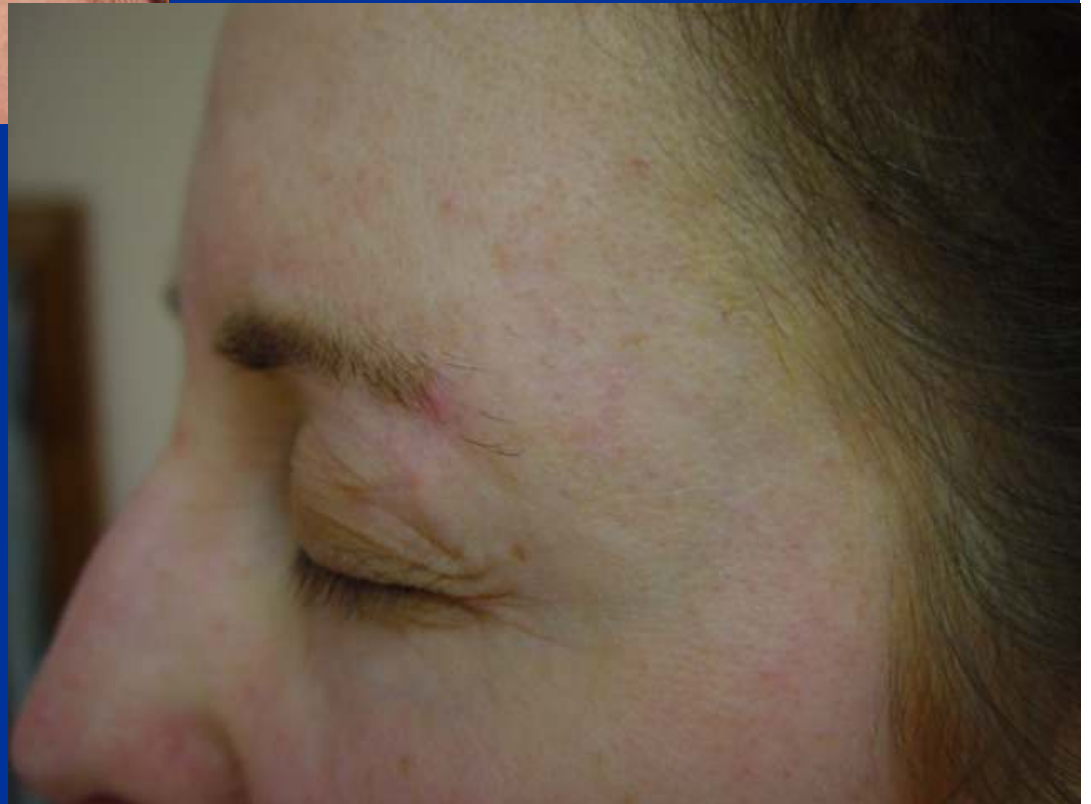

Laterally-based  
advancement flap with  
three dog-ears

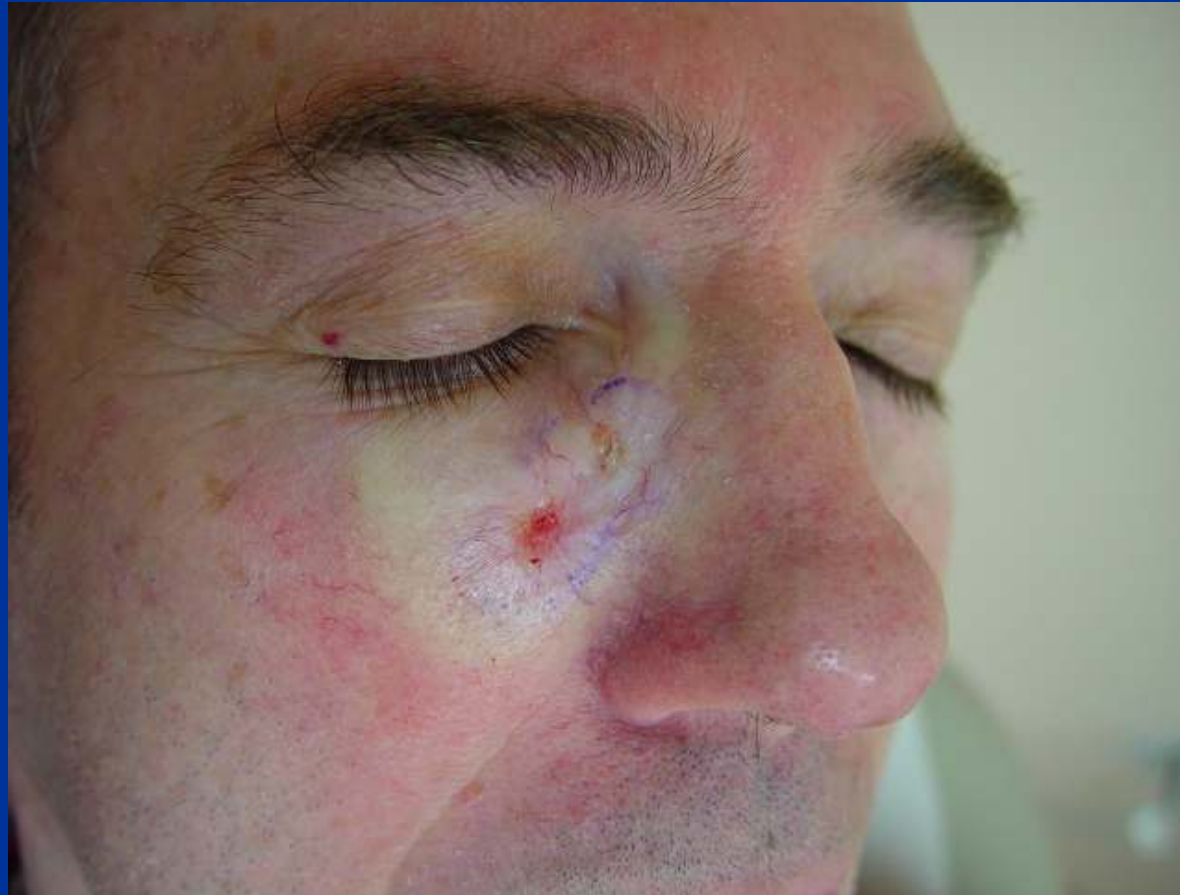


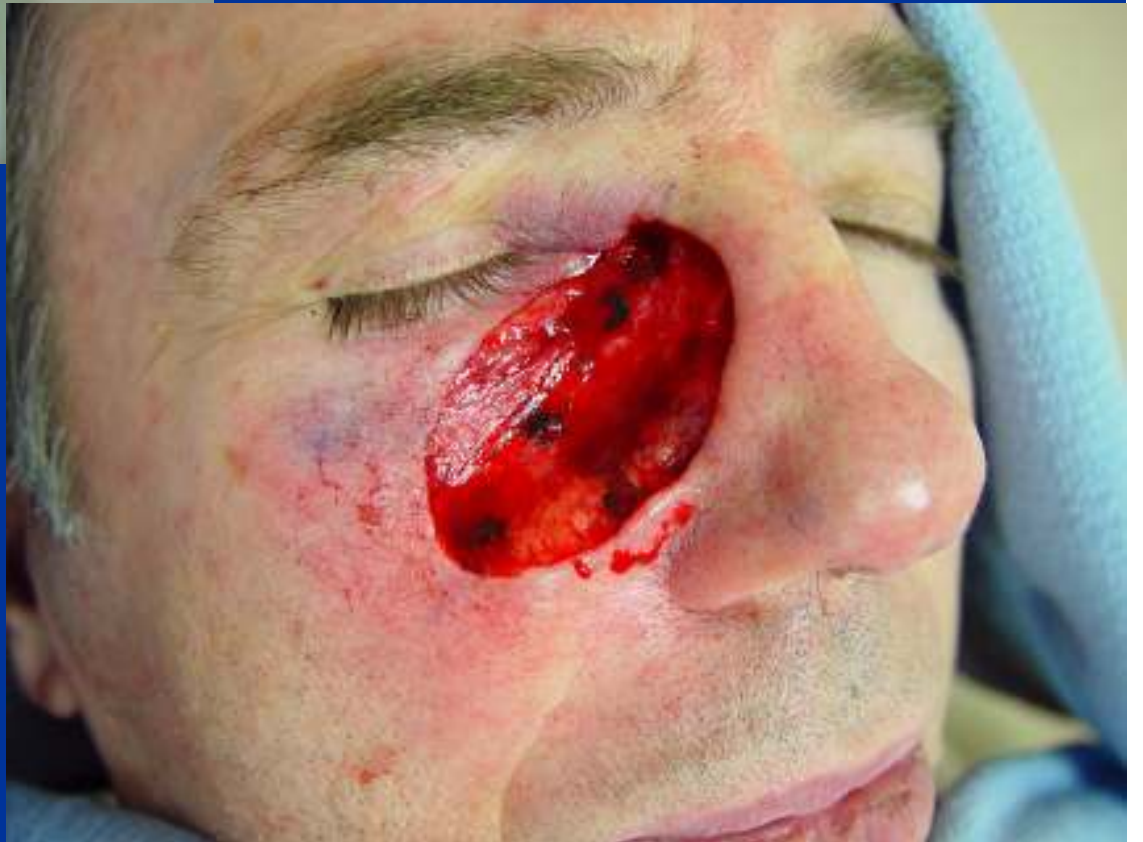
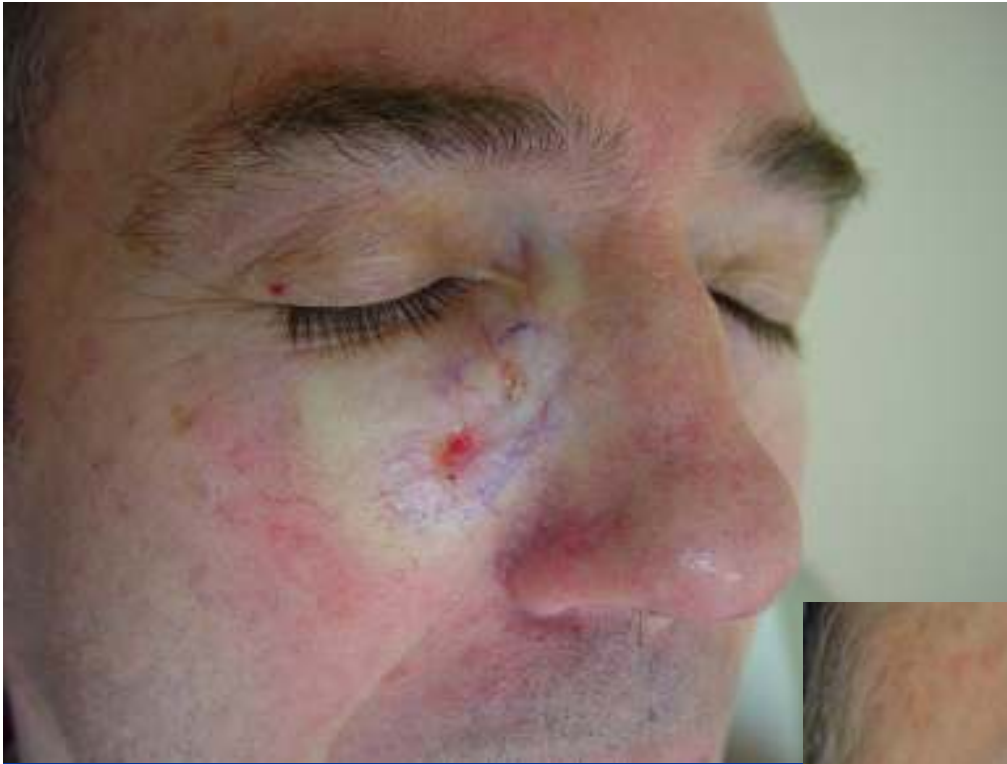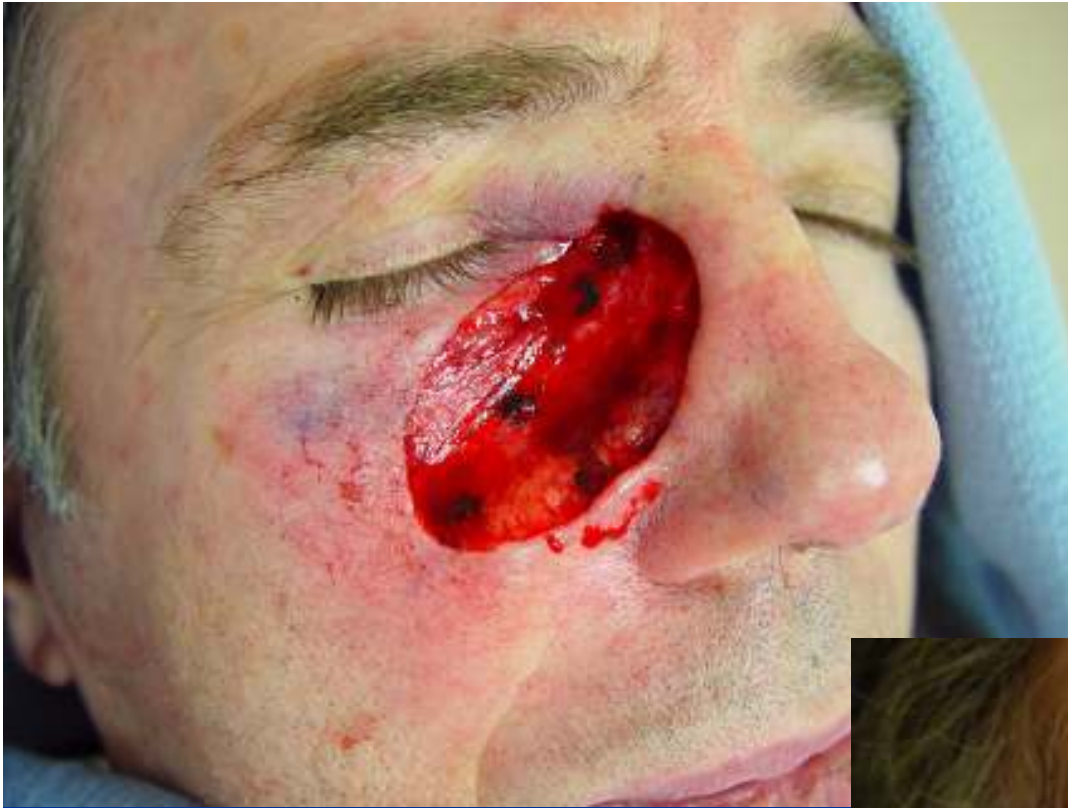One year later



## Multiply recurrent basal cell carcinoma



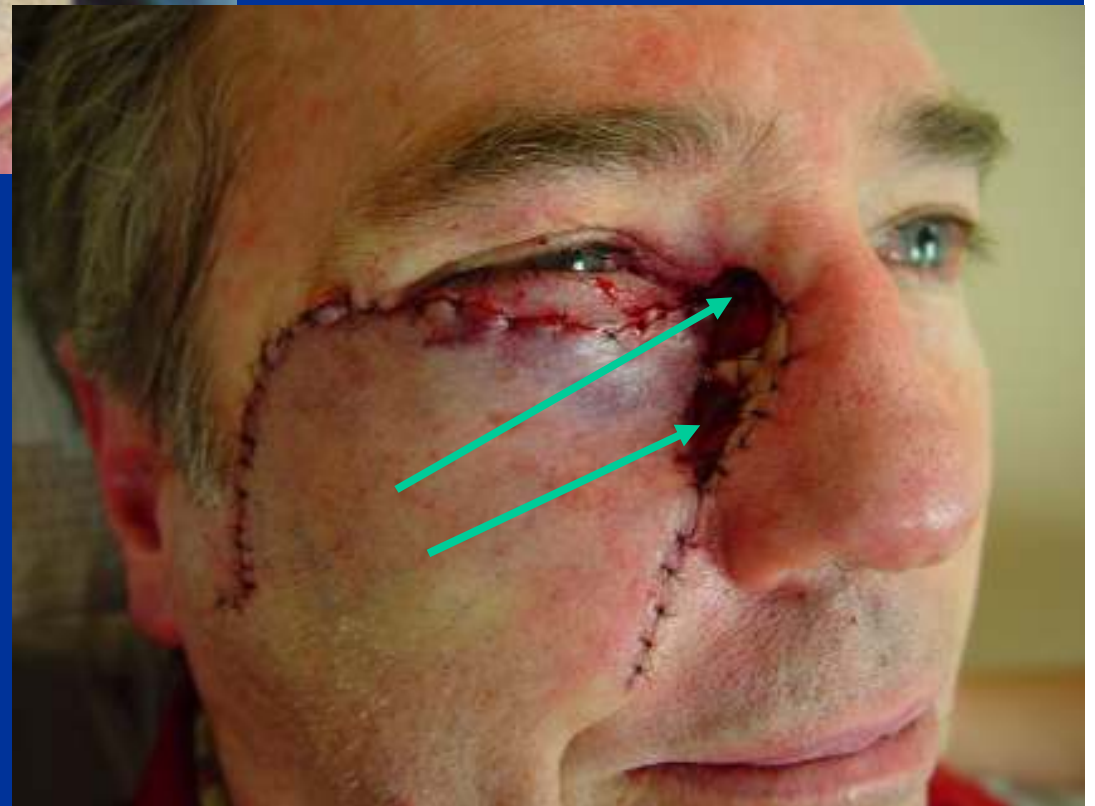


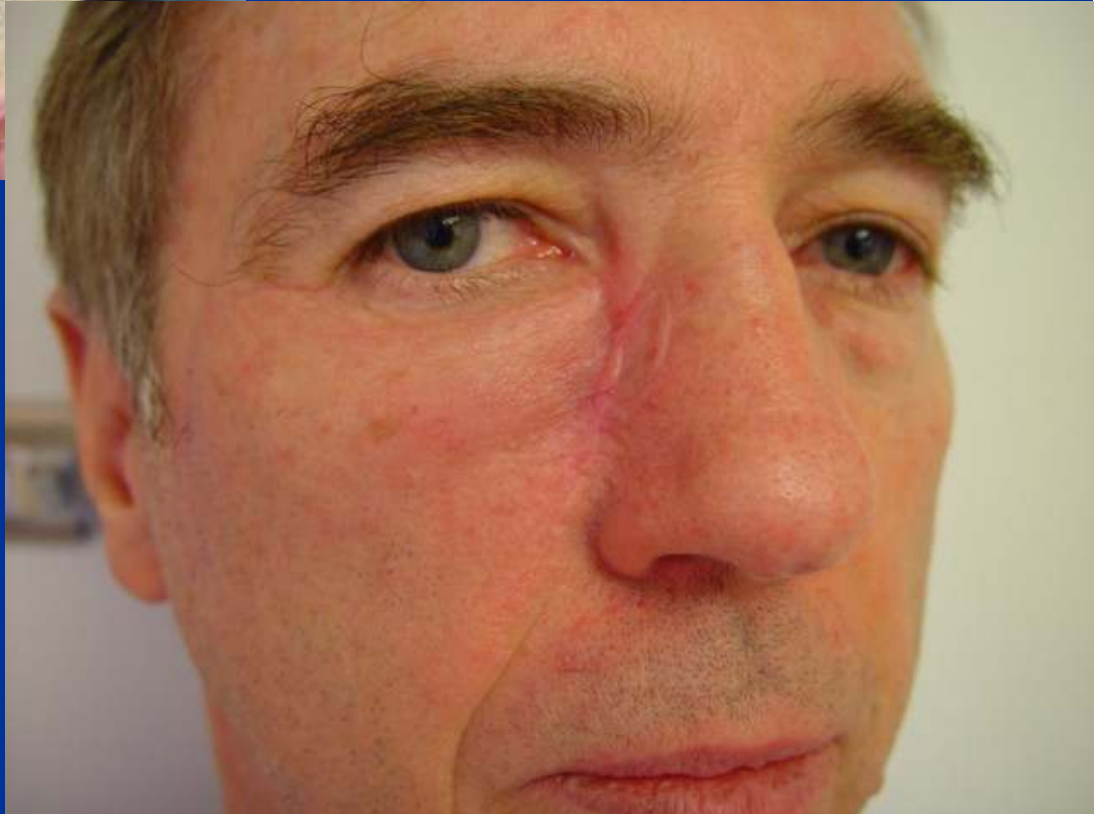
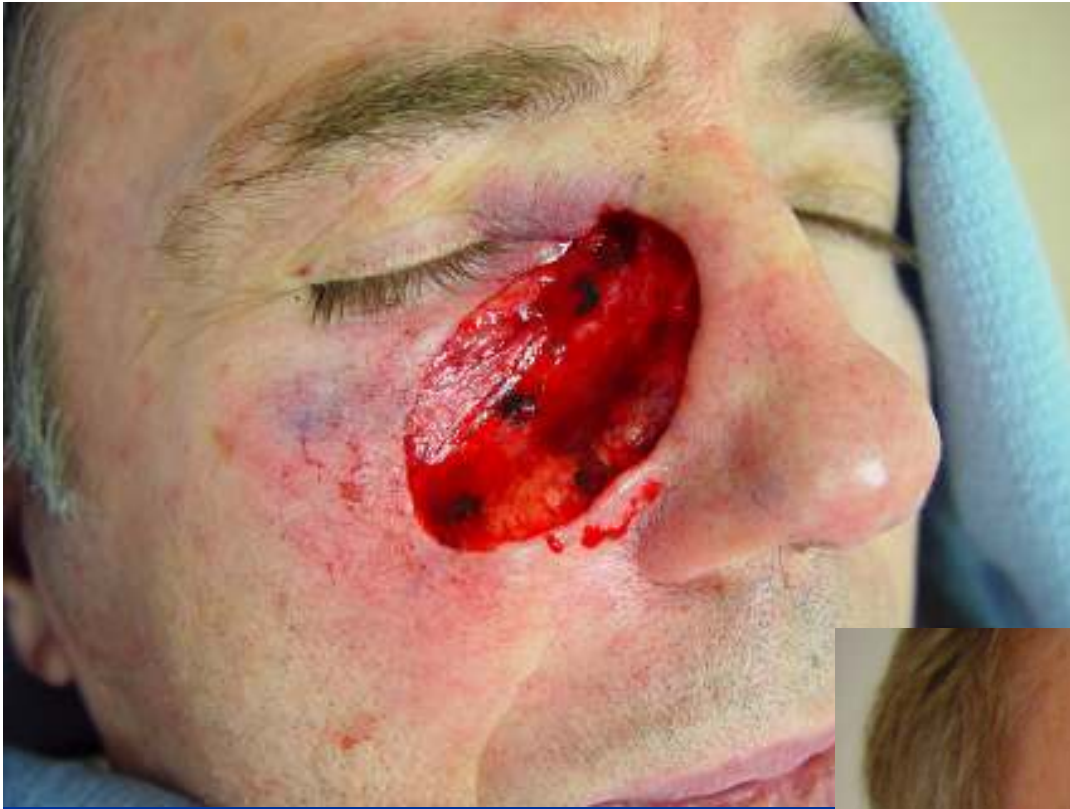## Mustardé Flap

Dog ear used to facilitate granulation

Granulation to maximize angle





Four months later